



Clostridioides Difficile Infection Presenting with Fulminant Colitis

Lucas F. Sobrado¹ Cristan Anderson¹ Scott R. Steele¹

¹Department of Colon & Rectal Surgery, Digestive Disease and Surgery Institute, Cleveland Clinic, Cleveland, OH, United States

Address for correspondence Lucas F Sobrado, MD, PhD, Department of Colon & Rectal Surgery, Digestive Disease and Surgery Institute, Cleveland Clinic, 9500 Euclid Ave. Cleveland, Ohio 44195, United States (e-mail: lfsobrado@gmail.com).

J Coloproctol

Abstract

Keywords

- ▶ *Clostridium difficile*
- ▶ *Clostridioides colitis*
- ▶ colectomy
- ▶ total abdominal colectomy
- ▶ surgery

Clostridioides difficile infection (CDI) is a common hospital-acquired infection, typically presenting with watery diarrhea and colitis. Most cases are managed with clinical support and antibiotics. Recently, more virulent strains have been associated with life-threatening infections. Surgery plays a role for complicated cases failing clinical treatment or with complications, such as bowel perforation and peritonitis. The present study reports the case of a 62-year-old female with CDI and fulminant colitis requiring urgent surgery. Surgeons should be aware of this presentation and involved early in the care of these patients, as clinical deterioration can occur very rapidly.

Introduction

Clostridioides difficile infection (CDI) is a common hospital-acquired infection that typically presents with watery diarrhea and colitis. Most cases are managed with clinical support and antibiotics. Recently, more virulent strains have been associated with life-threatening infections. Surgery plays a role for complicated cases failing clinical treatment or presenting with complications, such as bowel perforation and peritonitis. In this study, we present the case of a 62-year-old female with CDI and fulminant colitis requiring urgent surgery. Surgeons should be aware of this presentation and involved early in the care of these patients, as clinical deterioration can occur very rapidly.

Clinical Case

A 62-year-old female with a past medical history of hypertension, atherosclerosis, and remote aortobiliac bypass with inferior mesenteric artery reimplantation was admitted for evaluation of chronic gastrointestinal bleeding and underwent an upper endoscopy and colonoscopy. On the endoscopic exam, small, non-bleeding, angiodysplastic lesions of the stomach and duodenum were identified and treated with

argon plasma coagulation. Furthermore, small colonic polyps were removed with cold snare. During admission she was treated for a urinary tract infection with piperacillin and tazobactam.

At 2-weeks following discharge, she presented to the emergency department with fatigue, abdominal pain, and profuse watery diarrhea. On the physical exam, there was diffuse abdominal tenderness but no signs of peritonitis. She was afebrile but hypovolemic, with tachycardia of up to 125 bpm and hypotension requiring low dose pressors. Laboratory examination revealed a severe leukocytosis of 82,000 with left shift, acute kidney injury with a creatinine of 3.4, metabolic acidosis with a bicarbonate of 12.7, and a lactate of 8.9. After resuscitation with intravenous fluids, she underwent a plain abdominal radiograph (▶ **Fig. 1**) and a computed tomography (CT) scan of the abdomen and pelvis that was remarkable for diffuse proctocolitis without signs of intestinal ischemia. The polymerase chain reaction (PCR) testing was performed on the stool and confirmed CDI. Oral vancomycin and intravenous metronidazole were initiated.

However, over the following hours, the patient developed worsening abdominal tenderness with increased lactate and

received

January 26, 2024

accepted after revision

June 5, 2024

DOI <https://doi.org/>

10.1055/s-0044-1788666.

ISSN 2237-9363.

© 2024. The Author(s).

This is an open access article published by Thieme under the terms of the Creative Commons Attribution 4.0 International License, permitting copying and reproduction so long as the original work is given appropriate credit (<https://creativecommons.org/licenses/by/4.0/>).

Thieme Revinter Publicações Ltda., Rua do Matoso 170, Rio de Janeiro, RJ, CEP 20270-135, Brazil

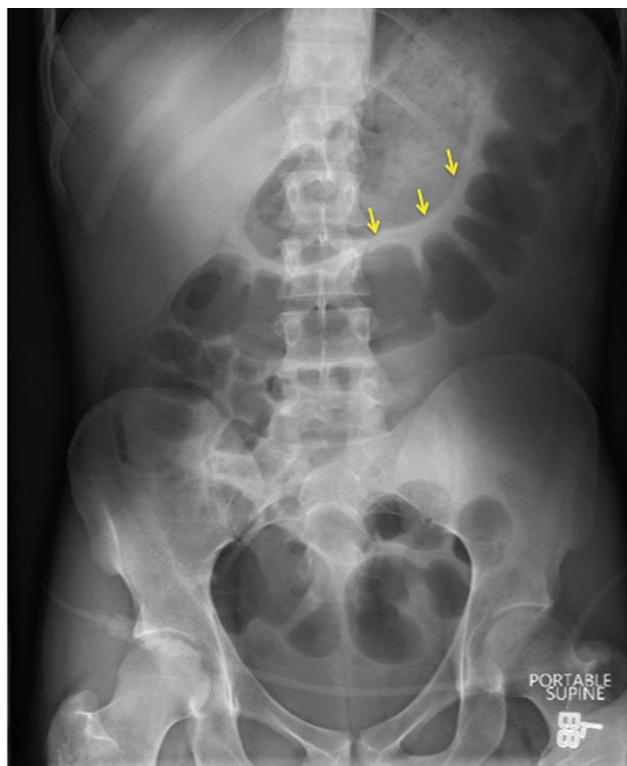


Fig. 1 Abdominal radiograph showing the typical thumbprinting sign (arrow), consistent with colonic wall thickening.

pressor requirements, and a change in mental status prompting emergent intubation for airway protection. The colorectal surgery team was consulted for evaluation of fulminant colitis. The patient was taken for emergency surgery and a

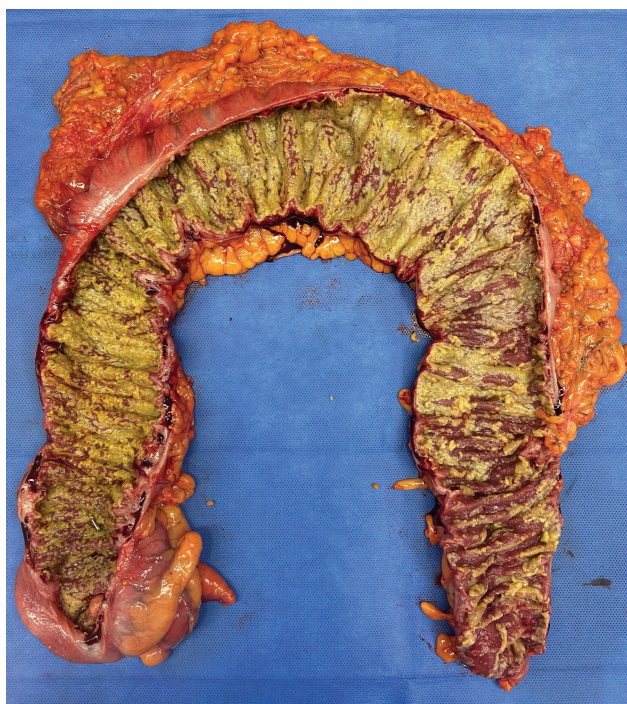

Fig. 2 Surgical specimen with colonic wall thickening and pseudomembranes on the mucosa.

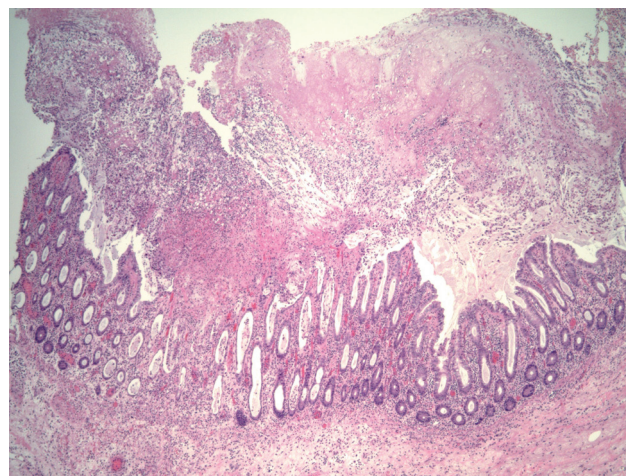


Fig. 3 Histologic sections reveal a pseudomembranous colitis pattern of injury characterized by fibrinopurulent exudate erupting from injured crypts, which is consistent with *Clostridioides difficile* infection.

subtotal colectomy with end-ileostomy and mucous fistula of the sigmoid colon was performed. The specimen revealed diffuse colonic wall thickening and pseudomembranes on the mucosa (►Fig. 2). Recovery was complicated by upper extremity deep vein thrombosis, requiring anticoagulation. She was discharged from the intensive care unit (ICU) on postoperative day (POD) 4 and home on POD 14.

Pathology confirmed severe colitis with ulceration, mucosal necrosis, and pseudomembranous exudate, compatible with CDI (►Fig. 3).

Discussion

This clinical case describes a patient with fulminant colitis, which can occur due to infectious pathogens or be related to inflammatory bowel disease (IBD). Patients without a history of IBD should be considered to have CDI until proven otherwise, especially if risk factors for infection are present, such as advanced age with clinical comorbidities, recent hospitalization or living in a nursing home, and use of antibiotics.¹ Although bowel preparation for colonoscopy causes alterations in the gut microbiome, it is not considered a risk factor for this disease. Recent data suggests increasing rates and severity of CDI colitis, which has been attributed to more virulent strains of the bacillus.²

Initial treatment for fulminant colitis associated with CDI includes oral vancomycin and intravenous metronidazole. ACT scan of the abdomen and pelvis with intravenous contrast is often obtained and can demonstrate diffuse colonic wall thickening and ascites. Complications such as portal vein gas, megacolon, and perforation can also be seen. Although CT scan has limited diagnostic accuracy, it can help to differentiate from other diagnoses, such as ischemic colitis. Plain radiograph films of the abdomen may reveal the typical finding of thumbprinting, which suggests bowel wall thickening due to an inflammatory process. Although nonspecific, when associated with history of antibiotics and watery diarrhea, this finding should prompt investigation of the colitis's causes.

Surgery plays a role in patients that develop abdominal complications such as bowel perforation and peritonitis or worsening symptoms despite adequate clinical treatment. As clinical deterioration can occur rapidly in patients with fulminant colitis, surgeons should be involved early in the care of these patients. Typically, a subtotal abdominal colectomy with end-ileostomy is the procedure of choice, but a diverting loop ileostomy with antegrade colonic lavage is also an option. It is important to note that the colon may occasionally appear normal on the serosa, yet the patient should still undergo total colectomy. Mortality following surgery for CDI is high, particularly for those with multiorgan failure.³ Early recognition of fulminant colitis, timely initiation of clinical treatment, and surgical evaluation are paramount to achieving good outcomes.

Informed Consent

Informed consent was obtained from the patient.

Data Availability

All data are included within the manuscript.

Author's Contribution

L.F.S., C.A., and S.R.S. contributed equally to the writing and editing of this manuscript. All authors read and approved the final manuscript.

Funding

No funding was received for this study.

Conflict of Interests

The authors have no conflict of interests to declare.

References

- 1 Poylin V, Hawkins AT, Bhama AR, et al. Prepared by the Clinical Practice Guidelines Committee of The American Society of Colon and Rectal Surgeons. The American Society of Colon and Rectal Surgeons Clinical Practice Guidelines for the Management of Clostridioides difficile Infection. *Dis Colon Rectum* 2021;64(06):650–668
- 2 Denève C, Janoir C, Poilane I, Fantinato C, Collignon A. New trends in Clostridium difficile virulence and pathogenesis. *Int J Antimicrob Agents* 2009;33(Suppl 1):S24–S28
- 3 Miller AT, Tabrizian P, Greenstein AJ, Dikman A, Byrn J, Divino C. Long-term follow-up of patients with fulminant Clostridium difficile colitis. *J Gastrointest Surg* 2009;13(05):956–959