



Reversible ifosfamide-induced encephalopathy with bursts of triphasic waves responsive to levetiracetam

Encefalopatia reversível induzida por ifosfamida com ondas trifásicas responsiva ao levetiracetam

Luis Eduardo Borges de Macedo Zubko¹ Lucas Altoé Brandão¹ Caio Cesar Diniz Dissero¹
Igor Ibrahim Nascimento¹ Luciano de Paola²

¹ Universidade Federal do Paraná, Complexo Hospital de Clínicas, Departamento de Neurologia, Curitiba PR, Brazil.

² Universidade Federal do Paraná, Complexo Hospital de Clínicas, Departamento de Neurofisiologia, Curitiba PR, Brazil.

Address for correspondence Luis Eduardo Borges de Macedo Zubko (email: luis.zubko@gmail.com).

Arq. Neuro-Psiquiatr. 2024;82(11):s00441789267.

A 42-year-old woman with a history of metastatic osteosarcoma and chronic kidney disease presented to our emergency department due to acute altered mental status that had started two days after chemotherapy infusion with ifosfamide and etoposide. Initially, she was alert, confused, and disoriented. On the third day, she developed echolalia, perseveration, and paroxysmal events of behavioral arrest. A brain magnetic resonance imaging (MRI) scan and the laboratory work up were unremarkable. An electroencephalogram (EEG) revealed diffuse slowing of background activity and bursts of triphasic waves (► **Figure 1**). The patient was managed with suspension of the ifosfamide and introduction of oral levetiracetam, which lead to improvements in the EEG and in cognition (► **Figure 2**). Reversible EEG changes and antiseizure-responsive encephalopathy may be observed during ifosfamide therapy.¹⁻³

Authors' Contributions

LEBMZ: conceptualization, data curation, methodology, and writing – original draft and editing; LAB: conceptualization,

investigation, supervision, validation, visualization, and writing – review; CCDD: conceptualization, investigation, supervision, validation, visualization, and writing – review; IAN: investigation, supervision, validation, visualization, and writing – review; LP: conceptualization, formal analysis, investigation, supervision, validation, visualization, and writing – review.

Conflict of Interest

The authors have no conflict of interest to declare.

References

- 1 Gusdon AM, Malani R, Chen X. Clinical and EEG Characteristics of Ifosfamide-Related Encephalopathy. *J Clin Neurophysiol* 2019;36(02):150–154. Doi: 10.1097/WNP.0000000000000539
- 2 Nicolao P, Giometto B. Neurological toxicity of ifosfamide. *Oncology* 2003;65(Suppl 2):11–16. Doi: 10.1159/000073352
- 3 Meira AT, Alves KF, Rezende TOP, Schelp AO, Betting LE. Source Analysis of Triphasic Waves Using Quantitative Neuroimaging. *J Clin Neurophysiol* 2022;39(06):466–473. Doi: 10.1097/WNP.0000000000000804

received

June 21, 2023

received in its final form

May 02, 2024

accepted

June 16, 2024

DOI <https://doi.org/>

10.1055/s-0044-1789267.

ISSN 0004-282X.

© 2024. The Author(s).

This is an open access article published by Thieme under the terms of the Creative Commons Attribution 4.0 International License, permitting copying and reproduction so long as the original work is given appropriate credit (<https://creativecommons.org/licenses/by/4.0/>).

Thieme Revinter Publicações Ltda., Rua do Matoso 170, Rio de Janeiro, RJ, CEP 20270-135, Brazil

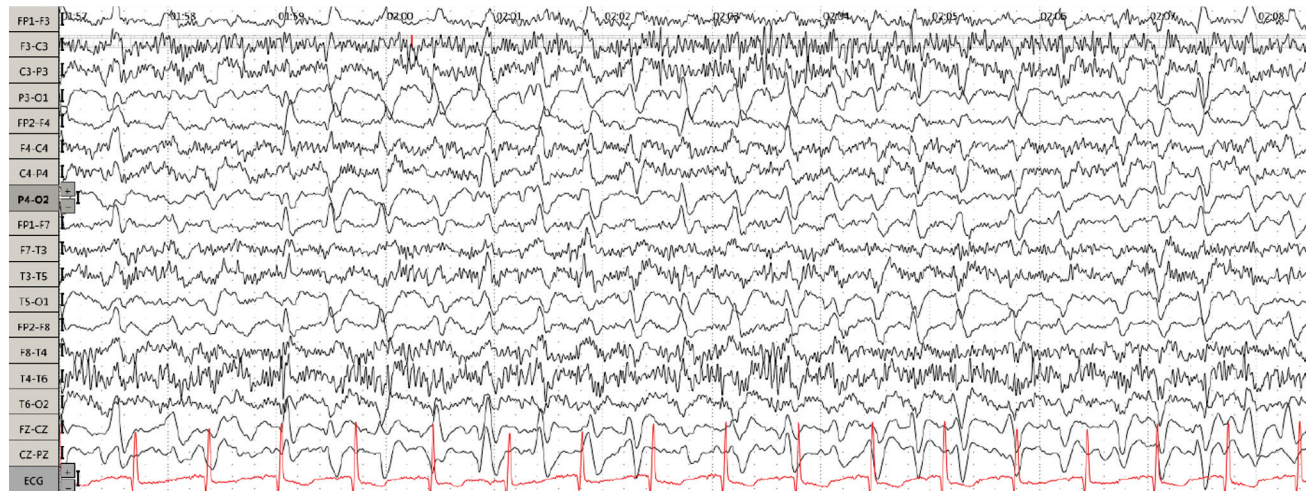


Figure 1 Three days after the onset of symptoms. Electroencephalogram (EEG) showing diffuse slowing of background activity and bursts of triphasic waves, with each burst lasting between 10 to 20 seconds.

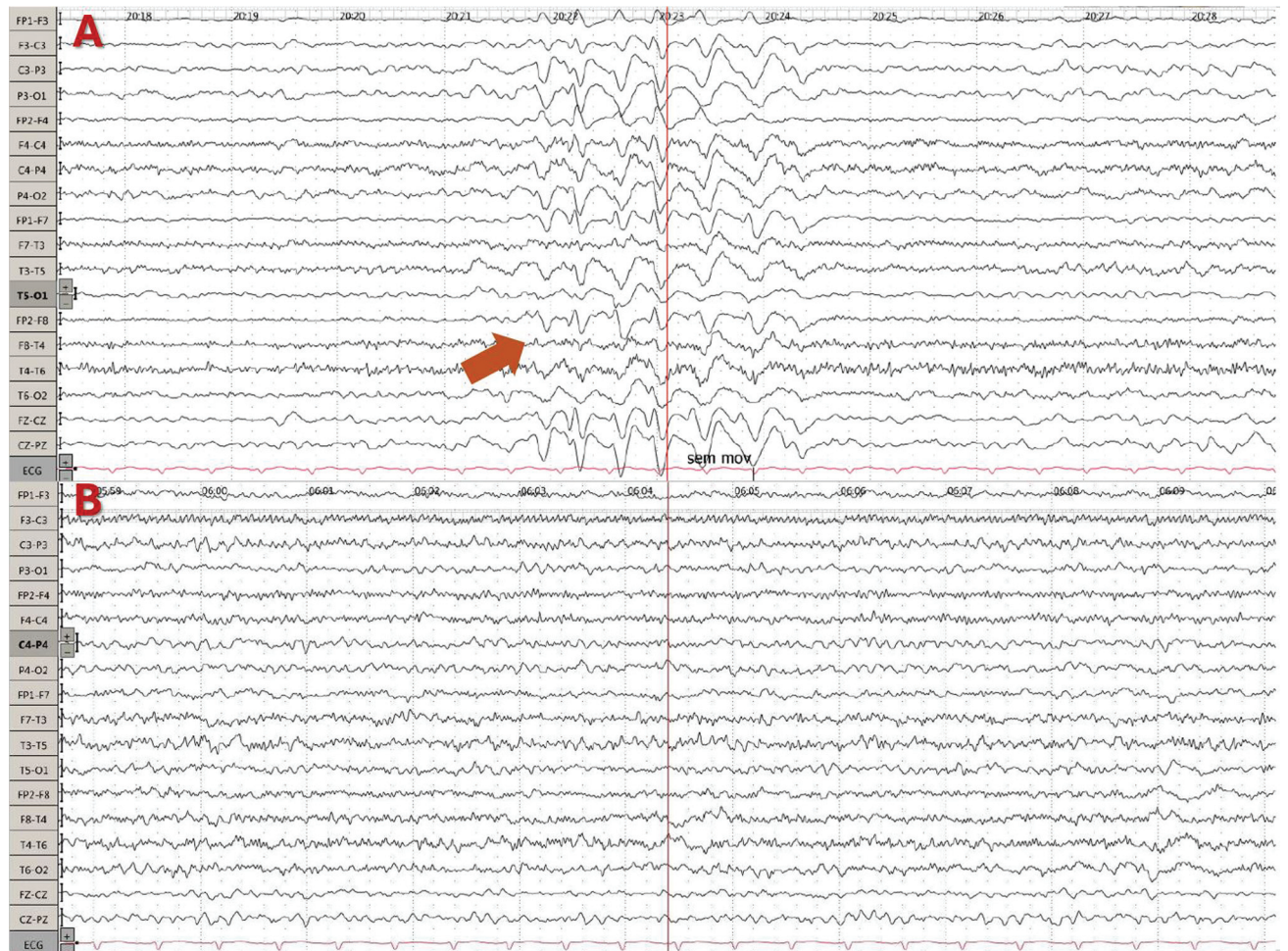

Figure 2 (A) Four days after the onset of symptoms. Second EEG after 1 day of levetiracetam introduction, showing partial improvement. (B) Eight days after the onset of symptoms. Third EEG, showing complete resolution.

Appendix A

Quiz

1. What are the predisposing factors for ifosfamide-induced encephalopathy?
 - A) Renal insufficiency.
 - B) Hepatic insufficiency.
 - C) Higher doses.
 - D) Poor functional status at treatment initiation.
 - E) All of the above.Answer: E.
2. What is the main pathophysiology for the central nervous system associated with ifosfamide?
 - A) A metabolic disturbance due to the depletion of glutathione caused by the toxic metabolite chloroacetaldehyde.
 - B) Excitotoxicity due to increase in glutamate transmission.
 - C) Neuroinflammation due to activation of microglia.
 - D) Direct neurotoxicity due to disruption of ion channels.
 - E) Disruption of the blood-brain barrier.Answer: A.
3. What other medications may be associated with triphasic waves on an electroencephalogram (EEG)?
 - A) Lithium.
 - B) Metronidazole.
 - C) Pregabalin.
 - D) Cefepime.
 - E) All of the above.Answer: E.
4. How long does it usually take for the CNS symptoms to improve with treatment after an episode of ifosfamide-associated encephalopathy?
 - A) 6 to 12 hours.
 - B) 12 to 24 hours.
 - C) 48 to 72 hours.
 - D) 72 to 96 hours.
 - E) None of the above.Answer: C.