

A 20-year-old prisoner presented to the emergency department with a history of recent deliberate foreign body ingestion and complaining of abdominal pain of 6 hours' duration. Abdominal radiographs showed metallic, cross-like foreign bodies in the upper gastrointestinal tract (Figure 1). Emergency laparotomy revealed perforations of the duodenum. The foreign bodies were removed, with a favorable outcome. Inspection of the surgically removed foreign bodies revealed that each one consisted of two 5-cm wires, tied together crosswise with rubber bands (Figure 2). The patient admitted that he had used straightened paperclips, cut in half, to make these "crosses". The elastic construction of the crosses enabled him to pull their branches together to lie parallel, wrap them in small strips of paper, and ingest them, with the expectation that gastric secretions would dissolve the wrap and release the sharp ends to cause gastrointestinal perforations. He anticipated that this would result in a vacation from jail and a prescription for narcotic analgesia.

Early endoscopic removal of ingested foreign bodies is considered the safest treatment [1], but this approach is contraindicated by Jackson's axiom that "advancing points puncture, trailing do not" [2]. The crosses ingested by this patient had two advancing and two trailing points, at roughly 90° angles to one another, precluding manipulation in any direction. Using latex protector hoods and overtubes to protect the gastrointestinal tract and facilitate safe foreign body removal is an attractive option, but its success remains unproven with this type of foreign object. It must also be noted that these tools can interfere with axis control and grip maintenance, might not have accommodated the "crosses" in this case, and may be perforated by the sharp ends of the foreign body [3–5].

The literature on foreign body ingestion provides numerous examples of successful early endoscopic foreign body remov-

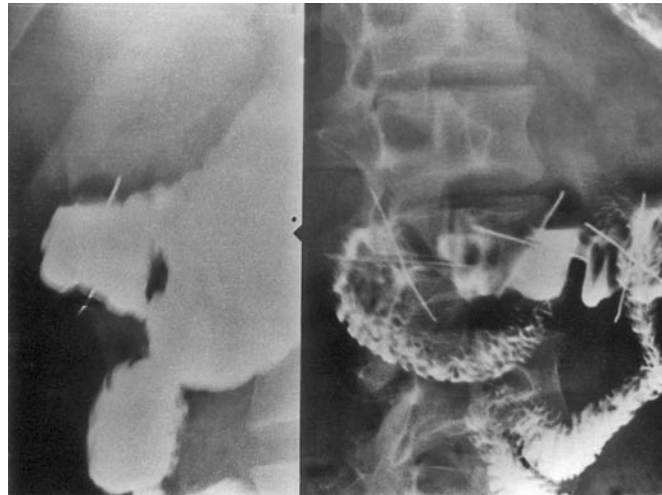


Figure 1 Abdominal meglumine amiodotriozate contrast radiographs. The view on the right shows one prepyloric "cross" and two crosses in the first part of the duodenum. The oblique view (left) demonstrates branches of a cross protruding beyond the confines of the duodenal lumen, indicating perforation.




Figure 2 Crosses made of paperclip halves, tied together with rubber bands (scale in centimeters).

al, so avoiding the high morbidity associated with perforations of the gastrointestinal tract [1–5]. In our experience, however, these "crosses" defeated this principle, necessitating emergency surgery to avoid life-threatening intra-abdominal sepsis.

J. E. Losanoff¹, K. T. Kjossev²

¹ Department of Surgery, University of Chicago

² Department of Surgery, Military Medical Academy, Sofia, Bulgaria.

References

- Eisen GM, Baron TH, Dominitz JA et al. American Society for Gastrointestinal Endoscopy: guidelines for the management of ingested foreign bodies. *Gastrointest Endosc* 2002; 55: 802–806

² Losanoff JE, Kjossev KT. Gastrointestinal "crosses": an indication for surgery. *J Clin Gastroenterol* 2001; 33: 310–314

³ Yong PTL, The CH, Look Met al. Removal of a dinner fork from the stomach by double-snare endoscopic extraction. *Hong Kong Med J* 2000; 6: 319–321

⁴ Faigel DO, Stotland BR, Kochman MLet al. Device choice and experience level in endoscopic foreign object retrieval: an in vivo study. *Gastrointest Endosc* 1997; 45: 490–492

⁵ Bertoni G, Sassatelli R, Conigliaro R, Bedogni G. A simple latex protector hood for safe endoscopic removal of sharp-pointed gastroesophageal foreign bodies. *Gastrointest Endosc* 1996; 44: 458–461

Corresponding Author

J. E. Losanoff, M. D.

Department of Surgery, University of Chicago, MC 5026, Room J 517
5841 South Maryland Avenue
Chicago, IL 60637
USA

Fax: +1-773-834-0361

E-mail: jelosanoff@yahoo.com