

Ileal Ascariasis Detected by Magnified Terminal Ileoscopy

A. Trecca¹, F. Gaj², S. Serafini¹,
M. Sperone¹

¹ Operative Units of Endoscopy and
Gastroenterology "Fabio Di
Giovambattista", Rome, Italy

² Department of General Surgery, Second
Surgical Clinic, University of Rome
"La Sapienza", Rome, Italy

Corresponding Author

A. Trecca, M. D.

Operative Units of Endoscopy and Gastro-
enterology "Fabio Di Giovambattista"

Via Reno, 30

00198 Rome

Italy

Fax: +39-06-8689-7737

E-mail: arimecme@tin.it

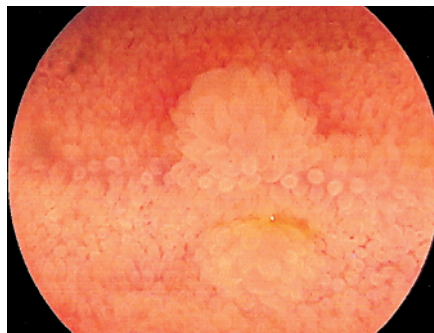

Figure 1 A 45-year-old Peruvian nun was referred to us for investigation of severe weight loss (more than 9 kg in 1 week) and asthenia. Esophagogastroduodenoscopy and total colonoscopy were negative, but terminal ileoscopy revealed an isolated finding of an enlarged submucosal follicle.

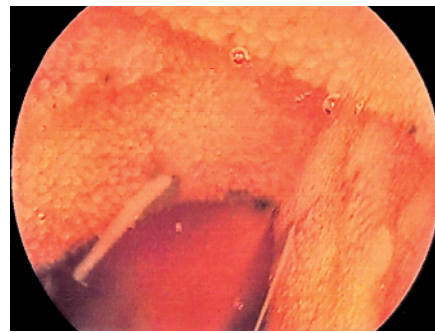


Figure 2 A biopsy was performed and suddenly two white worms became apparent. The view of the terminal ileum obtained using the Fujinon EC-410 CM magnifying colonoscope (Fujinon Co., Omiya, Japan) made it possible to biopsy one of the worms, and histological investigation revealed ileal ascariasis. The patient underwent substantial antibiotic therapy with a complete remission of weight loss and anemia within one week.