

Vascular malformation of the small intestine

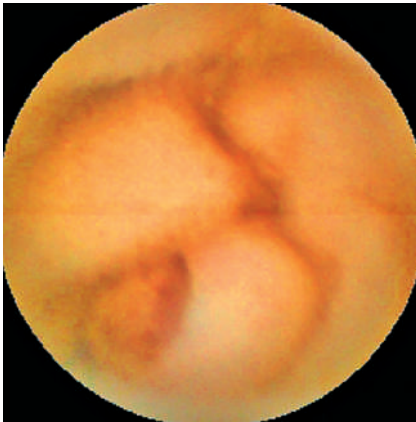

Fig. 1 Capsule endoscopy revealed a polypoid lesion in the small bowel, with surface ulceration.

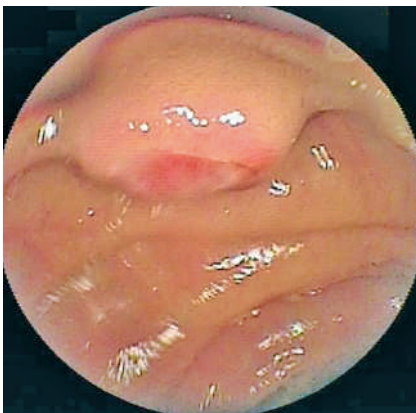


Fig. 2 Double-balloon enteroscopy showed a polypoid lesion with a surface ulcer in the jejunum, 70 cm distal (anal) to the ligament of Treitz.

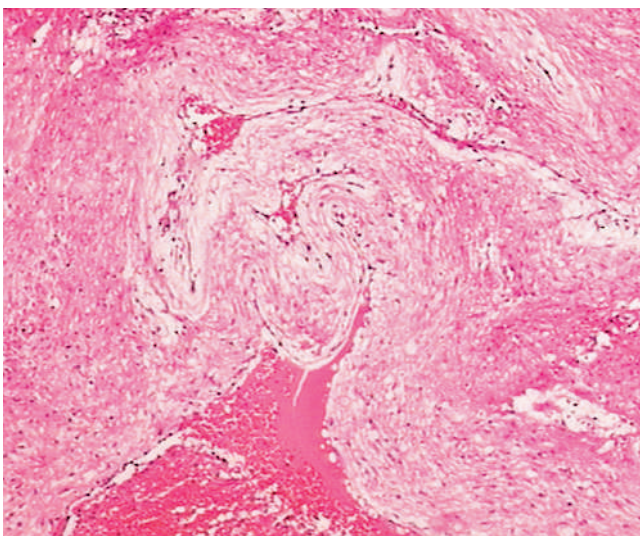


Fig. 3 Histologic examination revealed surface mucosal necrosis and enlarged, twisted, thick-walled blood vessels in the submucosa (hematoxylin and eosin stain, original magnification $\times 40$).

A 38-year-old Chinese man presented to our hospital with a 2-week history of dizziness and of passing black stools. Laboratory test results included the following (with normal ranges in parentheses): hemoglobin 4.9 g/dL (12–16 g/dL), red blood cell count $1.76 \times 10^{12}/L$ ($4.0–5.5 \times 10^{12}/L$), white cell count $8.01 \times 10^9/L$ ($4.0–10.0 \times 10^9/L$), platelet count $333 \times 10^9/L$ ($100–300 \times 10^9/L$). Biochemical parameters, including electrolytes and liver and renal function tests were within normal limits. Stool examination was positive for occult blood, but upper gastrointestinal endoscopy and colonoscopy examinations were both negative. The patient was transfused with 3 units of packed red blood cells. Capsule endoscopy (OMOM; Chongqing Jinshan Science & Technology Inc., China) was performed in order to further evaluate the patient's occult gastrointestinal tract bleeding and this showed a polypoid lesion with a surface ulcer in the small bowel (Fig. 1). Double-balloon enteroscopy confirmed this finding in the jejunum, 70 cm distal (anal) to the ligament of Treitz (Fig. 2). The patient underwent a jejunal resection and the surgical specimen showed a polypoid lesion measuring 0.8 cm \times 0.8 cm. Histologic examination revealed surface mucosal necrosis and the presence of enlarged, twisted, thick-walled blood vessels with local rupture and thrombosis in

the submucosa, surrounded by an inflammatory infiltrate (Fig. 3). The diagnosis of vascular malformation was suggested. There has been no recurrence of gastrointestinal bleeding 4 months after the jejunal resection.

This type of vascular lesion can cause occult gastrointestinal bleeding. Capsule endoscopy and double-balloon enteroscopy are useful in the diagnosis of such lesions, and surgical resection is regarded as a curative treatment. Perhaps, in the future, this type of vascular lesion will be removed by interventional double-balloon enteroscopy.

Endoscopy_UCTN_Code_CCL_1AC_2AB
Endoscopy_UCTN_Code_CCL_1AC_2AC

Z. Liao, R. Gao, Z.-S. Li

Department of Gastroenterology, Digestive Endoscopy Center, Changhai Hospital, The Second Military Medical University, Shanghai, China

Bibliography

DOI 10.1055/s-2007-966799
Endoscopy 2007; 39: E319

© Georg Thieme Verlag KG Stuttgart · New York · ISSN 0013-726X

Corresponding author

Z.-S. Li, MD

Department of Gastroenterology
Digestive Endoscopy Center
Changhai Hospital
The Second Military Medical University
174 Changhai Road
Shanghai 200433
China
Fax: +86-21-55621735
zhaoshenli@hotmail.com