

Calcifying tendinitis of the shoulder: arthroscopic needling versus complete calcium removal and rotator cuff repair. A prospective comparative study

ALESSANDRO CASTAGNA¹, SILVANA DE GIORGI², RAFFAELE GAROFALO³, MARCO CONTI¹, SILVIO TAFURI⁴, BIAGIO MORETTI¹

¹ Shoulder and Elbow Service, IRCCS Humanitas Institute, Rozzano, Milan, Italy

² Department of Basic Medical Sciences, Neurosciences and Sensory Organs, University of Bari, Italy

³ Shoulder Service, MIULLI Hospital, Acquaviva delle Fonti, Bari, Italy

⁴ Department of Biomedical Science and Human Oncology, University of Bari, Italy

Abstract

Purpose: the aim of the present study was to verify the differences in the clinical outcomes of two arthroscopic techniques used to treat calcifying tendinitis of the shoulder: needling *versus* complete removal of the calcium deposit and tendon repair.

Methods: from September 2010 to September 2012, 40 patients with calcifying tendinitis of the rotator cuff were arthroscopically treated by the same surgeon using one of the two following techniques: needling (Group 1) and complete removal of the calcium deposit and tendon repair with suture anchors (Group 2). Both groups followed the same rehabilitation program. The two groups were compared at 6 and 12 months of follow-up for the presence of residual calcifications and for the following clinical outcomes: Constant score, American Shoulder and Elbow Surgeons Evaluation Form (ASES) shoulder score, University of California Los Angeles (UCLA) shoulder rating scale, Simple Shoulder Test (SST) and Visual Analogue Scale (VAS).

Results: all the clinical scores (Constant, ASES, UCLA, SST and VAS scores) improved significantly between baseline and postoperative follow-up, both at

6 and at 12 months. No differences at final follow-up were found between the two groups.

Conclusions: both the techniques were effective in solving the symptoms of calcifying tendinitis of the shoulder. Clinical scores improved in both groups. Residual calcifications were found in only a few cases and were always less than 10 mm.

Level of evidence: Level II, prospective comparative study.

Keywords: calcium deposit, shoulder, calcifying tendinitis, needling, removal, rotator cuff.

Introduction

Calcifying tendinitis of the shoulder affects 2.5-3% of asymptomatic shoulders and is the cause of 7% of painful shoulders (a proportion that rises to about 20% if we consider only 40 to 50 year olds) (1). Calcifying tendinitis has, in the majority of cases, a benign evolution, which, according to Uhthoff, can be divided into different phases: formation, static phase and resorption (2). According to the French Arthroscopy Society (SFA), different types of calcifications can be identified on X-rays (**Fig. 1**): Type A: dense calcifications, homogeneous, unilobulated with sharp contours; Type B: dense calcifications with sharp contours, multi-lobulated; Type C: inhomogeneous calcifications with soft contours; and Type D: calcifications of the supraspinatus insertion area (3).

The results of arthroscopy are reported to be superior

Corresponding Author:

Silvana De Giorgi, MD
Department of Basic Medical Sciences, Neurosciences and Sensory Organs, University of Bari
Piazza G. Cesare 11, 70124 Bari, Italy
E-mail: silvana.degiorgi@uniba.it

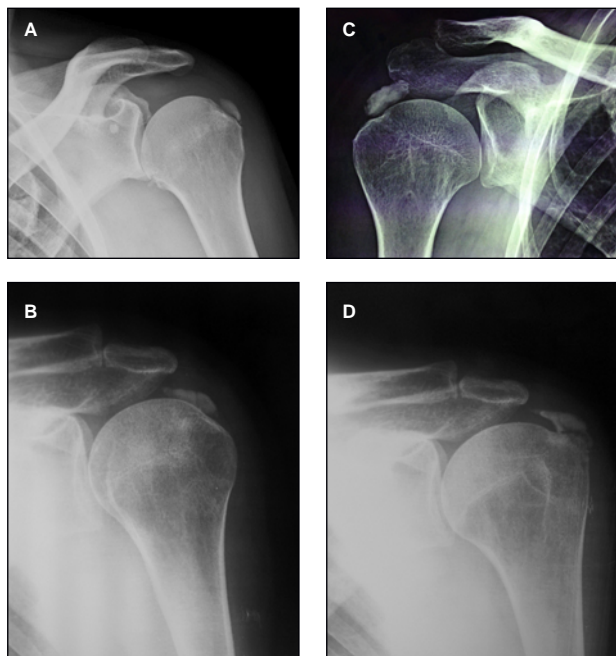


Fig. 1. SFA radiological classification. A: Type A, dense calcifications, homogeneous, unilobulated with sharp contours. B: Type B, dense calcifications with sharp contours, multi-lobulated. C: Type C, inhomogeneous calcifications with soft contours. D: Type D, calcifications of the supraspinatus insertion area.

to those obtained by ultrasound-guided lavage and the use of focal shock waves (4-6). The surgical technique used can vary: some surgeons prefer complete removal of the calcium deposit (leading to a clinical amelioration) without closure of the residual tendon defect, while others showed that suturing the tendon does not modify the evolution of the disease (7). Porcellini et al. (8) preferred to repair the tendon with suture anchors in spite of the absence of evidence of statistical differences between the two techniques.

According to some Authors, there is a strong correlation between total removal of the calcium deposit and resolution of clinical symptoms (3, 4, 7-9). Although acromioplasty has been suggested as associated procedure to reduce postoperative pain (10-12), this finding was not confirmed by other Authors (13). Finally, re-entering the glenohumeral space after the removal of the calcium deposit in order to perform a thorough lavage is strongly recommended in order to avoid the risk of capsulitis (10, 14).

In calcifying tendinitis of the cuff with osteolysis of the greater tuberosity, early surgery is recommended given

that, in this condition, any type of non-surgical treatment is destined to fail (15). Nevertheless, even after surgical treatment, in tuberosity osteolysis, Constant score can still be lower than that observed after treatment of non-osteolytic calcium deposits (16, 17).

In spite of the numerous reports published to date, it remains unclear which arthroscopic technique should be used in surgery for calcifying tendinitis of the shoulder.

The aim of our study was to compare two surgical techniques: needling of the tendon *versus* complete removal of the calcium deposit and reinsertion of the tendon with the placement of suture anchors. The hypothesis of the study was that calcium deposit removal and tendon repair provides a better outcome than tendon needling.

Methods

Participants and interventions

The present study was designed as a prospective comparative study. We obtained approval from the local IRB. All the patients signed an informed consent form for their data to be processed in an anonymous way for scientific purposes.

Forty consecutive patients were included in the study. All underwent surgical treatment for supraspinatus calcifications in our Department in the period September 2010 to September 2012. All the patients had presented clinical symptoms for at least one year and had previously undergone a cycle of focal shock wave treatment. We excluded other concomitant pathologies of the shoulder (including frozen shoulder) and clinical diseases like diabetes in all the patients.

The patients were divided into two groups: Group 1 underwent needling and arthroscopic aspiration/lavage (**Fig. 2**) and Group 2 underwent complete arthroscopic removal and tendon repair with suture anchors. The same rehabilitation program was followed by the two groups. It consisted of 15 days in a sling, followed by passive motion of the shoulder, and then active motion after the first postoperative month, to allow progressive recovery of strength.

All the patients underwent a clinical assessment at baseline and at 6 and 12 months after surgery. This was based on evaluation of the passive range of

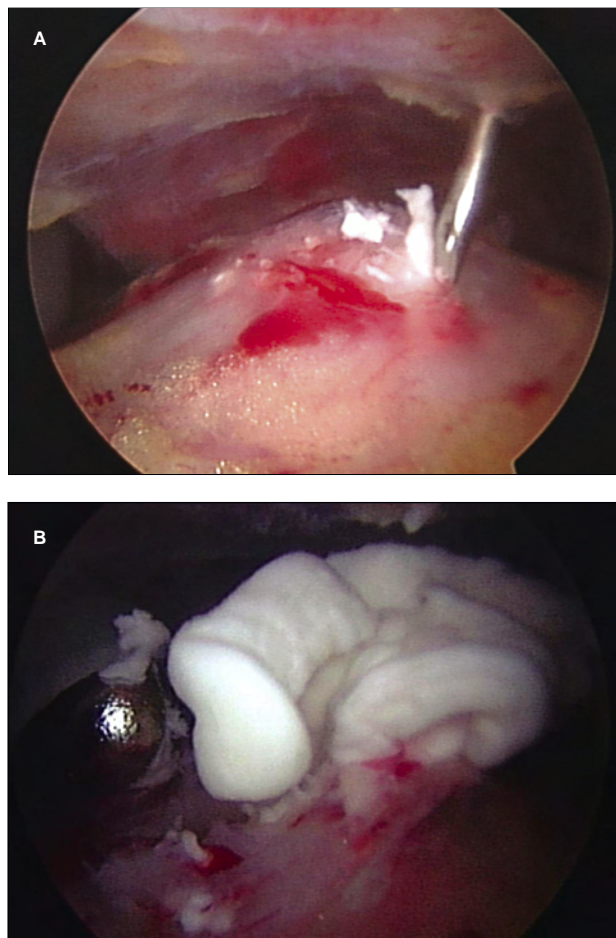


Fig. 2. Arthroscopic needling of calcium deposit in the supraspinatus tendon (A). The calcium deposit is removed by shaving and aspiration (B).

motion (PROM) and use of the following scoring systems for functional shoulder assessment and subjective evaluation: the Constant scoring system, the American Shoulder and Elbow Surgeons (ASES) Standardized Shoulder Assessment Form, the University of California Los Angeles (UCLA) shoulder rating assessment, the Simple Shoulder Test (SST) and a Visual Analog Scale (VAS). Ultrasound or magnetic resonance scans and X-rays were performed before surgery and at 6 months and 12 months of months follow-up. In order to assess the presence or absence of residual calcification and its correlation with the primary outcome, calcifications were classified according to the SFA radiographic classification (3) and also according to their size (type I, < 10 mm; type II, 10-

20mm, and type III, > 20 mm) (8). For each enrolled patient, a detailed form was filled in reporting all the evaluations carried out.

Data analysis

Sample size was calculated by assuming a difference of 50% in the primary outcome (Constant score) between the two groups, $\alpha=0.05$ and power=0.9. The minimum sample size was thus calculated to be 36. Data were analyzed using STATA® software. Quantitative variables are reported as means and standard deviations. To verify the differences between the two groups, a Student's t-test for unpaired samples was used. Differences in mean values of scores in each group before the treatment and at follow-up, were analyzed using the t-test for paired samples. A p-value of less than 0.05 was considered significant.

Results

The study population consisted of 15 males and 25 females. The dominant arm was involved in 27 cases. The mean age at the time of surgery was 48.4 ± 8.1 years (range, 31-66 years).

Group 1 included 28 patients: 11 with type A, 15 with type B and 2 with type C calcifications. Twenty-four patients underwent simple needling/aspiration, while in 4 patients side-to-side stitches with absorbable monofilament suture were used to close the residual tendon defect after the calcific deposit removal. Group 2 included 12 patients: 3 with type A, 6 with type B and 3 with C calcifications.

As regards the size of the calcium deposits, preoperative radiographs revealed type I (<10 mm) calcifications in 13 cases, type II (10-20 mm) in 22, and type III (> 20 mm) in five.

The two groups were homogeneous for sex, age, time between symptoms and surgery, size and location of calcifications, and dominance and side of the involved shoulder. The two groups' demographic details are shown in **Table 1**.

X-ray examinations at final follow-up demonstrated the absence of residual calcium deposits in 32 patients (80%) (**Fig. 3**), while microcalcifications (of 1 to 2 mm) were detected in 3 patients (7.5%) and calcium deposits smaller than 10 mm (type I) were found in 5 patients (12.5%).

Table 1. Distribution of enrolled patients per group and age, time between symptoms and surgery, size of calcifications, dominance and side of the involved shoulder.

	Group 1 (28)	Group 2 (12)	p
Males	10	5	0.72
Average age	47.3±8.8	51.3±5.6	0.08
Average time between symptoms and surgery	2.3±1.2	2.2±2.1	0.36
Mean size of calcifications	9.0±4.1	11.3±2.7	0.14
Dominant shoulder involved	22	6	0.071
Right shoulder involved	21	6	0.12

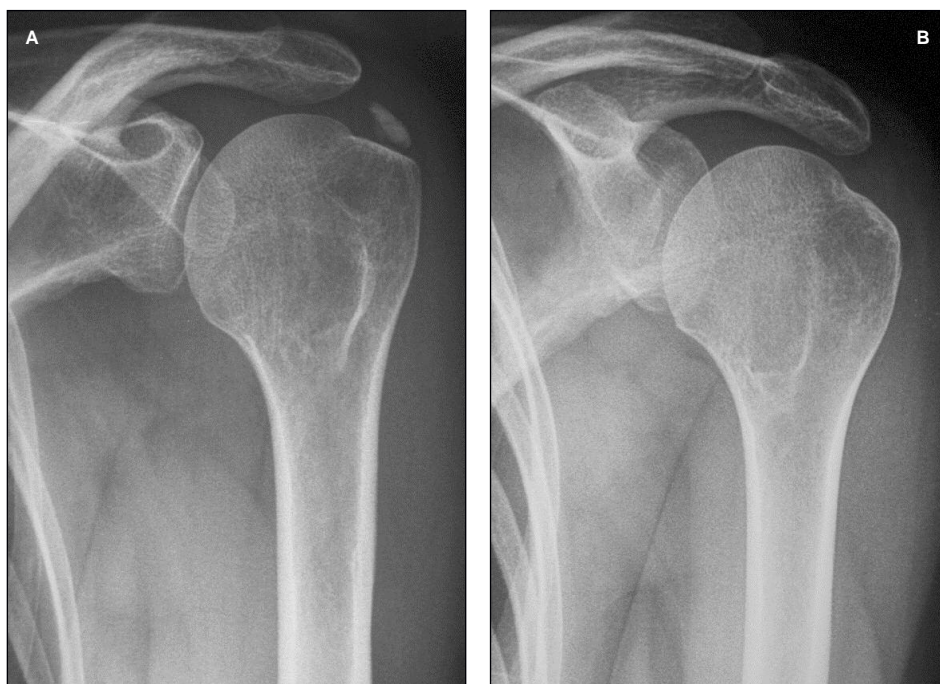

Fig. 3. Radiographic examination of a left shoulder with Type A calcification before surgery (A) and at follow-up (B).

The patients' Constant, ASES, UCLA, SST and VAS scores are reported in **Table 2**.

There were no differences between the groups in the mean value of the Constant score (CS) preoperatively ($p=0.36$), at 6 months ($p=0.38$) or at final follow-up ($p=0.17$).

In Group 1, the CS increased from 47.8 ± 17.2 preoperatively to 81 ± 9.9 at 6 months ($p < 0.0001$) and 91.7 ± 4.6 at final follow-up ($p < 0.0001$). In Group 2, the CS increased from 46 ± 12.5 preoperatively, to 80 ± 8.9 at 6 months ($p < 0.0001$) and 90 ± 4.9 at final follow-up ($p < 0.0001$).

The mean ASES score did not differ between the two groups preoperatively ($p=0.23$), at 6 months ($p=0.14$) or at 12 months ($p > 0.05$). Both in Group 1 and in Group 2 the score increased significantly from baseline to 6 months ($p < 0.0001$ and $p < 0.0001$, respectively) and from 6 months to the final follow-up ($p=0.0043$ and $p < 0.0001$, respectively).

The mean UCLA score did not differ between the two groups preoperatively ($p=0.21$) or at 6 months ($p=0.43$). At the final follow-up the value was higher in Group 1 than in Group 2 ($p=0.03$). In both groups, the mean UCLA score significantly increased from

Table 2. Mean values of Constant, ASES, UCLA, SST and VAS scores in Group 1 and Group 2 at baseline, at 6 months and at 12 months.

	Baseline	6 months	12 months
Constant scores			
Group 1	47.8±17.2	81±9.9	91.7±4.6
Group 2	46±12.5	80±8.9	90±4.9
ASES scores			
Group 1	65.6±15.8	94.2±20	113.3±9.3
Group 2	61.6±15.4	99.1±8.7	113±8
UCLA scores			
Group 1	15.5±3.6	28.2±5.4	34.4±0.9
Group 2	16.5±3.4	28±3	33.1±2.0
SST scores			
Group 1	4.1±2.8	7.8±1.4	9.8±0.4
Group 2	3.0±1.9	8.1±0.8	9.6±1.0
VAS			
Group 1	7.9±1.6	2.5±2.1	1±1.1
Group 2	8.2±1.1	2.7±1.1	1.1±1.4

baseline to 6 months ($p < 0.0001$ for both groups) and from 6 to 12 months ($p = 0.0007$ and $p < 0.0001$ for Group 1 and 2, respectively).

The mean SST score did not significantly differ between the two groups at any of the three time points (baseline: $p = 0.07$; 6 months: $p = 0.19$; 12 months: $p = 0.22$). It was found to increase from the baseline to the 6 months evaluation in Group 2 ($p < 0.0001$); this increase was not found in Group 1 ($p = 0.22$). Instead, both groups showed an increase in this score from 6 to 12 months ($p < 0.0001$ for both groups).

No significant difference in mean VAS score was found between the groups at any of the three time points (baseline: $p = 0.27$; 6 months: $p = 0.33$; 12 months: $p = 0.4$). It increased in Group 1 from baseline to 6 months ($p < 0.0001$) and from 6 months to 12 months ($p = 0.02$); similar increases were found in Group 2 ($p < 0.0001$ and $p < 0.0001$, respectively).

Table 3 shows the PROM in the two groups. Mean passive external rotation with arm at the side (ER1) was significantly higher in Group 2 than in Group 1 at baseline ($p = 0.03$) but no significant difference between the two groups was found at 6 months ($p = 0.09$) or at 12 months ($p = 0.10$). From baseline to 6 months, mean ER1 significantly increased in Group 1 ($p = 0.0038$) but not in Group 2 ($p = 0.42$). From 6 to 12 months, mean ER1 significantly increased in both groups ($p = 0.046$ and $p = 0.005$, respectively).

The mean value of passive abduction (ABD) was not different in the two groups at baseline ($p = 0.06$), at 6 months ($p = 0.23$) or at 12 months ($p = 0.61$). In Group 1, this value significantly increased from baseline to 6 months ($p = 0.0009$) and from 6 to 12 months ($p = 0.03$); in Group 2, it increased from baseline to 6 months ($p = 0.0008$) but there was no difference from 6 to 12 months ($p = 0.09$).

The groups were homogeneous for passive internal rotation (IR) before surgery ($p = 0.21$); at 6 months, the value was significantly higher in Group 1 ($p = 0.04$) but no difference was noted at the final follow up ($p = 0.08$). In the two groups, the mean value did not increase from baseline to 6 months ($p = 0.07$ and $p = 0.47$, respectively) or from 6 to 12 months ($p = 0.33$ and $p = 0.18$ respectively).

No correlation was found between residual calcification of the tendon and CS either at 6 ($p = 0.67$) or at 12 months ($p = 0.91$) of follow-up.

Discussion

Calcifying tendinitis of the rotator cuff is a common disorder of the shoulder. Women are affected more frequently than men (1, 7, 12), as our paper confirms. The clinical scores (Constant, ASES, UCLA, VAS, SST) improved significantly between baseline and 6 months

Table 3. Mean values of passive ER1, passive ADB and passive IR in Group 1 and Group 2 at baseline, at 6 months and at 12 months.

	Baseline	6 months	12 months
Passive ER1			
Group 1	40.8±16.6	57.9±11.4	65.9±10.2
Group 2	51.2±15.2	52±13.1	60.8±11
Passive ABD			
Group 1	73.3±15.6	85.8±6.7	90±0
Group 2	79.8±10.4	87.5±6.4	89.6±4.4
Passive IR			
Group 1	56.9±20.8	63.7±11.4	65.9±11.1
Group 2	50.4±27.5	56.6±12.3	59.6±12.5

postoperatively without any difference between the two groups (18). Furthermore, even after 6 months, both groups also showed further clinical improvements.

Passive ABD recovered in both groups within the first six months. No differences in passive IR were found between the groups at 6 or at 12 months, but there was a better recovery of IR at 6 months in Group 1. Satisfaction at follow-up was present in both groups. No correlation was found between residual calcification of the supraspinatus tendon and CS, either at 6 or at 12 months of follow-up. Residual calcifications, always less than 10 mm, were found in only a few cases.

A strength of this study is that only one surgeon performed all the surgeries, in order to ensure minimum variability; furthermore, the study was prospective and compared two treatment groups. All concomitant shoulder pathologies were excluded and the same rehabilitation program was used in the two groups. We considered only calcifications of the supraspinatus tendon so as to have a better homogeneity of the sample and this can be considered a further strength of the study.

A weakness is that the two groups were numerically different (Group 1 was bigger than Group 2), even though they were quite homogeneous in terms of distribution. A further limitation of the study is that we did not conduct a reliability analysis of the calcification assessments (the size and type of calcifications) and PROM assessments. Finally the sample was too small to allow the cases to be split into subclasses large enough for statistical analyses.

In conclusion, both the techniques considered – arthroscopic needling/lavage of the tendon *versus* complete removal of the calcium deposit and repair of the tendon with suture anchors – seem to be effective in treating pain and in improving function in chronic calcifying tendinitis of the rotator cuff recalcitrant to conservative treatment. Further prospective Level I studies are necessary to confirm the obtained results.

rososcopic needling/lavage of the tendon *versus* complete removal of the calcium deposit and repair of the tendon with suture anchors – seem to be effective in treating pain and in improving function in chronic calcifying tendinitis of the rotator cuff recalcitrant to conservative treatment. Further prospective Level I studies are necessary to confirm the obtained results.

References

1. Clavert P, Sirveaux F. Shoulder calcifying tendinitis. Rev Chir Orthop Reparatrice Appar Mot. 2008; 94 (8 Suppl): 336-355.
2. Uhthoff HK, Sarkar K. Calcifying tendinitis. In Rockwood CA, Matsen FA (Eds), The Shoulder. WB Saunders, Philadelphia. 1990; 774-789.
3. Molé D, Kempf J, Gleyze P, Rio B, Bonnomet F, Walch G. Résultats du traitement arthroscopique des tendinopathies non rompues de la coiffe des rotateurs 2ème partie: les calcifications de la coiffe des rotateurs. Rev Chir Orthop. 1993;79 :532-541.
4. Loew M, Jurgowski W, Hau HC, et al. Treatment of calcifying tendinitis of rotator cuff by extracorporeal shock waves: a preliminary report. J Shoulder Elbow Surg. 1995;4:101-106.
5. Rompe JD, Zoeliner J, Nafe B. Shock wave therapy versus conventional surgery in the treatment of calcifying tendinitis of the shoulder. Clin Orthop Relat Res. 2001; (387):72-82.
6. Rotini R, Bungaro P, Antonioli D, et al. Algorithm for the treatment of calcific tendinitis in the rotator cuff: indications for arthroscopy and results in our experience. Chir Organi Mov. 2005;90:105-112.
7. Molé D. Calcifying tendinitis. In: Gazielly DF, Gleyze P, Thomas T (Eds), The Cuff. Elsevier, Paris. 1997;141-185.
8. Porcellini G, Paladini P, Campi F, et al. Arthroscopic treatment of calcifying tendinitis of the shoulder: clinical and ultrasonographic follow-up findings at two to five years. J Shoulder Elbow Surg. 2004;13:503-508.
9. Ark JW, Flock TS, Flatow EL, et al. Arthroscopic treatment of calcific tendinitis of the shoulder. Arthroscopy. 1992;8:183-188.
10. Kempf JF, Bonnomet F, Nerisson D, et al. Arthroscopic isolated excision of rotator cuff calcium deposits. In: Gazielly DF, Gleyze P, Thomas T (Eds), The Cuff. Elsevier, Paris. 1997;144-147.

11. Resch H, Povacz P, Seycora P. Excision of calcium deposit and acromioplasty? In: Gazielly DF, Glayze P, Thomas T (Eds), *The Cuff*, Elsevier, Paris. 1997;169-171.
12. Balke M, Bielefeld R, Schmidt C, et al. Calcifying tendinitis of the shoulder: midterm results after arthroscopic treatment. *Am J Sports Med.* 2012;40: 657-661.
13. Kircher J, Morhard M, Patzer T, et al. Do anatomic variants of the acromion shape in the frontal plane influence pain and function in calcifying tendinitis of the shoulder? *Knee Surg Sports Traumatol Arthrosc.* 2012;20:368-372.
14. Snyder SJ, Eppley RA, Brewster S. Arthroscopic removal of subacromial calcification. *Arthroscopy.* 1991;7:320-321.
15. Porcellini G, Campi F, Battaglino M. Calcific tendinitis of the rotator cuff with trochiteal osteolysis. A rare clinical radiologic complication. *Chir Organi Mov.* 1996; 81:207-212.
16. Porcellini G, Paladini P, Campi F, et al. Osteolytic lesion of greater tuberosity in calcific tendinitis of the shoulder. *J Shoulder Elbow Surg.* 2009;18:210-215.
17. De Carli A, Pulcinelli F, Delle Rose G, et al. Calcific tendinitis of the shoulder. *Joints.* 2014;2: 130-136.
18. Constant C, Murley AH. A clinical method of functional assessment of the shoulder. *Clin Orthop.* 1987;214:160-164.