

Case Report

Variation of the latissimus dorsi

Ishani P Shah^{1,3}, Amit Yadav^{2,3}, Rujuta Mehta^{3,4,5,6}, Mukund Thatte^{3,5,7}

¹Departments of Paediatric Orthopaedics and ²Plastic and Hand Surgery, ³Bai Jerbai Wadia Hospital for Children, ⁴Department of Paediatric Orthopaedics, Nanavati Hospital, ⁵Shushrusha Citizens' Co-op Hospital, ⁶Jaslok Hospital and Research Center, ⁷Department of Plastic and Hand Surgery Bombay Hospital and Institute of Medical Sciences, Mumbai, Maharashtra, India

Address for correspondence: Dr. Mukund Thatte, 402, Vimal Smruti, 770 Ghanti Road, Dadar, Mumbai - 400 014, Maharashtra, India.
E-mail: mthatte@gmail.com

ABSTRACT

A typical muscle variation of latissimus dorsi — the axillary arch is represented by the muscular or fibromuscular slip detached from the anteroinferior border of the musculus latissimus dorsi passing over the axilla under the axillary fascia crossing the medial side of the brachial plexus to continue as a septum intermusculare mediale brachii distally to the medial epicondyle of humerus. The full extent of the muscle is rarely present. Slips of muscle extend from the latissimus dorsi at the inferior angle of scapula to insert into pectoralis major (Langer), coracobrachialis, biceps or coracoid process forming what is described as a common variant - the muscular axillary arch. We report three cases of variants of latissimus dorsi, one of which has not been reported in the literature before.

KEY WORDS

Axillary arch; latissimus dorsi; shoulder muscle transfer; variant

INTRODUCTION

A typical muscle variation of latissimus dorsi — the axillary arch was first described by Ramsey in 1795.^[1] It was called the musculus dorsoepitrochlearis costoeptitrochlearis, chondroepitrochlearis, chondrohumeralis, and pectorodorsalis by Bergman 1991 and Bergman *et al.* 1988.^[2] It is represented by the muscular or fibromuscular slip detached from the anteroinferior border of the musculus latissimus dorsi passing over the axilla under the axillary fascia crossing the medial side of the brachial plexus to continue as a septum intermusculare mediale brachii

distally to the medial epicondyle of humerus.^[1,3] The full extent of the muscle is rarely present. Slips of muscle extend from the latissimus dorsi at the inferior angle of scapula to insert into pectoralis major (Langer), coracobrachialis, biceps or coracoid process forming what is described as a common variant — the muscular axillary arch.^[3-5]

CASE REPORT

Here we are reporting three cases of variants of the axillary arch. One of which has not been reported before in the literature.

A 7-year-old male with right obstetric brachial plexus palsy (OBPP), 4-year-old male with left OBPP and a 12-year-old female with left OBPP were operated for their shoulder contracture. A shoulder muscle transfer was done. During the dissection, a variant of the latissimus dorsi was found.

In the first case, a muscular slip was found originating from the anterior inferior border of latissimus dorsi at

Access this article online	
Quick Response Code:	Website: www.ijps.org
	DOI: 10.4103/0970-0358.146668

the inferior angle of scapula arching over the axillary neurovascular bundle and inserting with the main tendon into the intertubercular sulcus unlike the variants mentioned in the literature [Figures 1 and 2]. It measured 6 cm in length, 1.5 cm in width and 0.5 cm in thickness. In the second case, the slip was found originating from the anterior superior border of latissimus dorsi and inserting into the pectoralis minor muscle. It measured 5.3 cm in length, 1 cm in width and 0.5 cm in thickness [Figure 3]. In the third case, it was originating from the anterior border and inserted into pectoralis major muscle measuring 5 cm in length, 1 cm in width and 0.5 cm in thickness

In all three cases, the muscle was erased from the insertion and sutured with the conjoint tendon to complete the shoulder muscle transfer. No separate neuro-vascular pedicle to the muscle was found.

DISCUSSION

All forms of musculus dorsoepitrochlearis, complete or incomplete can be explained by the development of musculus latissimus dorsi. It is a phylogenetically ancient structure found in quadruped mammals, amphibians and reptiles (Leche 1900, Ribbing 1938). The musculus latissimus dorsi in small embryos (15-16 mm crown-rump length) appears as a narrow craniocaudal strip on the lateral side of the body extending from the eleventh rib and adjacent vertebrae to the humerus. It then spreads out in a fan shaped form in cranial and in antero-caudal directions to attain definitive positions of its attachments on vertebral spines and on the iliac crest. In the course of its development, it forms two distinct primordia, the cranial and the caudal one, each with the independent neurovascular hilum. Both these parts later fuse together, but they may be surgically separated even in the adult. In human embryos between 15- and 18-mm crown-rump length, a well-formed dorsoepitrochlearis primordium is visible. Later on, the arch of the muscle primordium is interrupted and disappears, probably by cell death (apoptosis). The remaining strips of the musculus dorsoepitrochlearis detaching from the anteroinferior border of the musculus latissimus and going to the axilla either fully disappear or remain in the form of strips known as typical muscle variants under the axillary fascia on the medial side of the brachial plexus. They can be secondarily attached to various structures in the axilla:

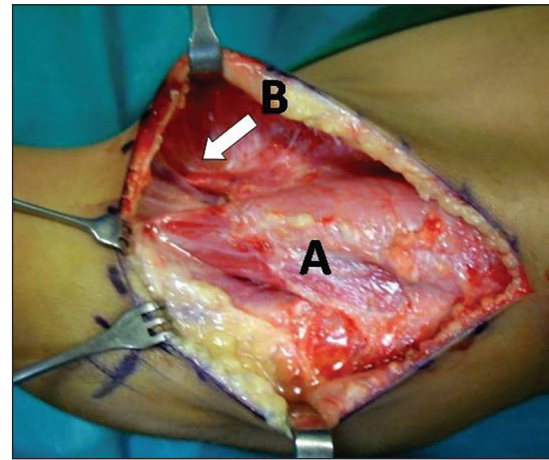


Figure 1: (a) Latissimus dorsi (b) muscular slip

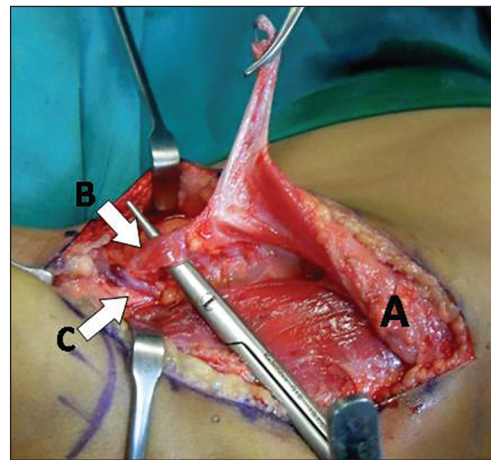


Figure 2: (a) Latissimus dorsi (b) muscular slip (c) axillary neurovascular bundle

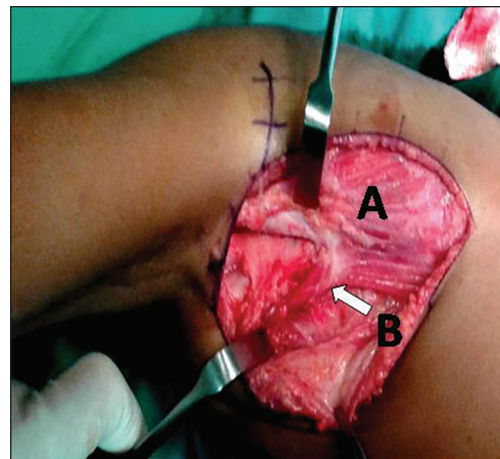


Figure 3: (a) Latissimus dorsi (b) muscular slip

To the capsule of the shoulder joint, to the coracoid process at its tip or its inferior surface, to the fasciae of neighboring muscles, to the fascia of musculus biceps or musculus triceps brachii, to the crest of the greater tubercle of humerus, or into the musculus pectoralis

major or to the belly of latissimus dorsi and into the intertubercular sulcus as in this case.

The axillary arch muscle usually receives its nerve supply from the medial pectoral nerve, suggesting that it is derived from the pectoral muscles.^[6] When closely associated with the latissimus dorsi, the axillary arch muscle can be supplied by the thoraco-dorsal nerve.^[7] In our case, it appeared as the latter. The blood supply is generally from the lateral thoracic vessels. However, in our cases, we did not see a separate pedicle entering the muscle.

Arch-shaped variations in the axilla could be considered in two groups, muscular form (type I) and tendinous form (type II), accompanying different subtypes based on their nerve supplies and site of their attachment points.^[8] However, clinical classification of the axillary arches could be defined as superficial and deep arch groups. Superficial group arches cross in front of the vessels and nerves, and the veins could be affected primarily within this variation that may play a role in intermittent obstruction of the axillary vein.^[9] Deep group arches occur deeply on the posterior or lateral walls of the axilla. These arches usually cross only parts of the neurovascular bundle and axillary or radial nerves could be affected.

In our cases of OBPP, it was an incidental finding with no specific symptoms, and its presence did not alter the surgical plan. Only a complete detachment of the muscle and the variant slip needs to be ensured, and both can be sutured together as one muscle to the infraspinatus tendon. Missing the slip could result in a persistent internal rotation contracture with the poor result of the surgery.

Clinically it has been implicated in costoclavicular compression syndrome, axillary vein entrapment, median nerve entrapment, hyperabduction syndrome, and thoracic outlet syndrome and shoulder instability syndrome.^[10] This muscle can obscure palpability of axillary lymph nodes. In axillary lymph node clearance, it can obscure nodes and lead to incomplete clearance. In

the case of a latissimus dorsi flap for coverage in axilla, failure to recognise this variant will result in compression of the thoraco-dorsal pedicle and subsequent loss of the flap. The superficial arch group can cause axillary vein obstruction. In the case of an inexperienced surgeon, a large muscle can baffle the surgeon and lead to unsatisfactory results. In the case of latissimus dorsi flap for coverage in axilla, failure to recognise this variant could result in compression of the thoraco-dorsal pedicle thereby resulting in loss of the flap.

REFERENCES

1. Ramsey A. Account of unusual conformations of some muscles and vessels. *Edinb Med Surg J* 1812;8:281-3.
2. Bergman RA. Doubled pectoralis quartus, axillary arch, chondroepitrochlearis, and the twist of the tendon of pectoralis major. *Anat Anz* 1991;173:23-6.
3. Loukas M, Noordeh N, Tubbs RS, Jordan R. Variation of the axillary arch muscle with multiple insertions. *Singapore Med J* 2009;50:e88-90.
4. Besana-Ciani I, Greenall MJ. Langer's axillary arch: Anatomy, embryological features and surgical implications. *Surgeon* 2005;3:325-7.
5. McWhirter D, Malyon A. The axillary arch: A rare but recognised variation in axillary anatomy. *J Plast Reconstr Aesthet Surg* 2008;61:1124-6.
6. Soubhagya RN, Latha VP, Ashwin K, Madhan KS, Ganesh CK. Coexistence of an axillary arch muscle (latissimocondyloideus muscle) with an unusual axillary artery branching: Case report and review. *Int J Morphol* 2006;24:147-50.
7. Turgut HB, Peker T, Gülekon N, Anil A, Karaköse M. Axillopectoral muscle (Langer's muscle). *Clin Anat* 2005;18:220-3.
8. Takafuji T, Igarashi J, Kanbayashi T, Yokoyama T, Moriya A, Azuma S, *et al.* The muscular arch of the axilla and its nerve supply in Japanese adults. *Kaibogaku Zasshi* 1991;66:511-23.
9. Jeleu L, Georgiev GP, Surchev L. Axillary arch in human: Common morphology and variety. Definition of "clinical" axillary arch and its classification. *Ann Anat* 2007;189:473-81.
10. Mérida-Velasco JR, Rodríguez Vázquez JF, Mérida Velasco JA, Sobrado Pérez J, Jiménez Collado J. Axillary arch: Potential cause of neurovascular compression syndrome. *Clin Anat* 2003;16:514-9.

How to cite this article: Shah IP, Yadav A, Mehta R, Thatte M. Variation of the latissimus dorsi. *Indian J Plast Surg* 2014;47:453-5.

Source of Support: Nil, **Conflict of Interest:** None declared.