

Case Report : Primary Hydatid Cyst of Muscle - A Rare Site

V ARORA, IS NIJJAR, KS GILL, G SINGH

Ind J Radiol Imag 2006 16:2:239-241

Key words : Hydatid Cyst, Muscle

H ydatid cyst affecting a muscle is very rare, the clinical and radiological diagnosis of which requires a high index of suspicion. We report a case of a lady presenting with a swelling in the thigh thought to be an abscess, the preoperative diagnosis of which was hydatid cyst on MRI. Though hydatid disease is endemic in India, we present this case due to the rarity of site and typical MR picture.

CASE REPORT :

A fifty year lady presented with a large painless swelling in the thigh for four months.

There was no history of trauma, fever or weight loss. Physical examination revealed a diffuse, non tender cystic swelling occupying nearly the whole of the medial aspect of the thigh with fixity of the muscles.

On blood examination, the total leucocyte count was 7500 cells UL^{-1} (2% eosinophils).

The patient was sent for an MRI for the exact localisation and extent of the mass and to rule out any involvement of the bone.

A routine MRI examination (1.5 T symphony, Siemens) included STIR sequence in coronal plane and GRE T2 W and SE T1 W sequences in axial plane. The study (Fig 1 & 2) revealed a large multiloculated cystic lesion in the medial compartment of the thigh mainly occupying the adductor magnus muscle. It measured 28.0 x 11.5 x 12.0cm in size. Multiple smaller daughter cysts and a free floating membrane were seen in it. A diagnosis of hydatid cyst was made. Inferiorly, it was encasing the sciatic nerve (fig 3).

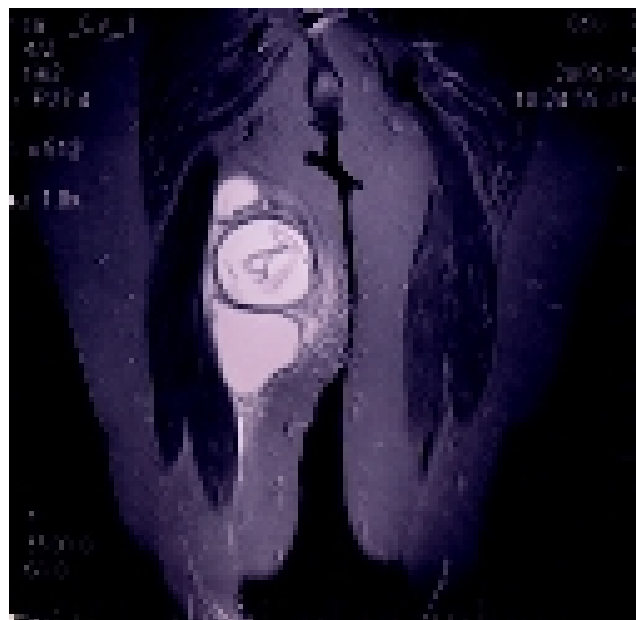
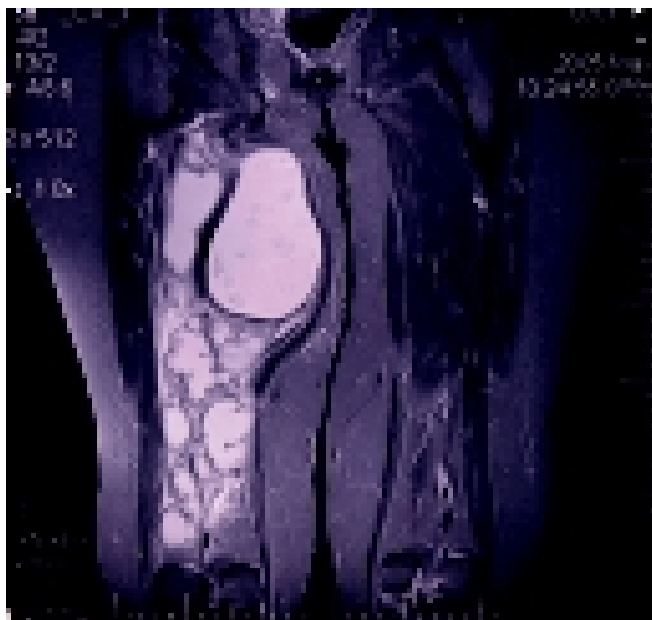

FIG.1 & 2 TSE T2W coronal images show the multiloculated lesion with multiple daughter cysts and a floating membrane.

From the Nijjar Scan & Diagnostic Centre, Amritsar

Request for Reprints: Dr. Vijinder Arora, Nijjar Scan & Diagnostic Centre, Amritsar - 143001 (Pb)

Received 18 July 2005; Accepted 15 December 2005

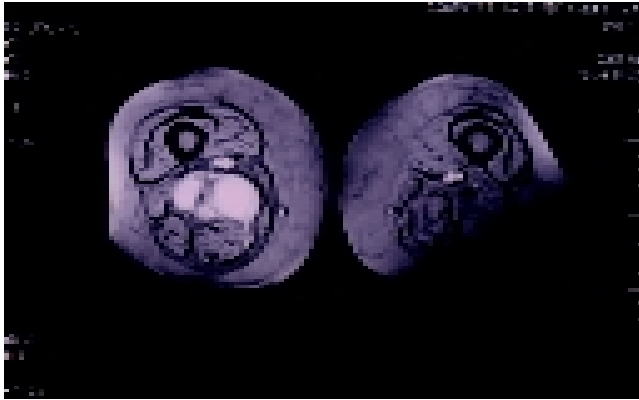


FIG. 3 TSE T2W axial image displaying the lower part of the cyst encasing the sciatic nerve.

Ultrasound guided FNAC was done which yielded whitish fluid with the smear showing hooklets and pinkish homogenous chitinous material with evidence of superadded infection (fig 4).

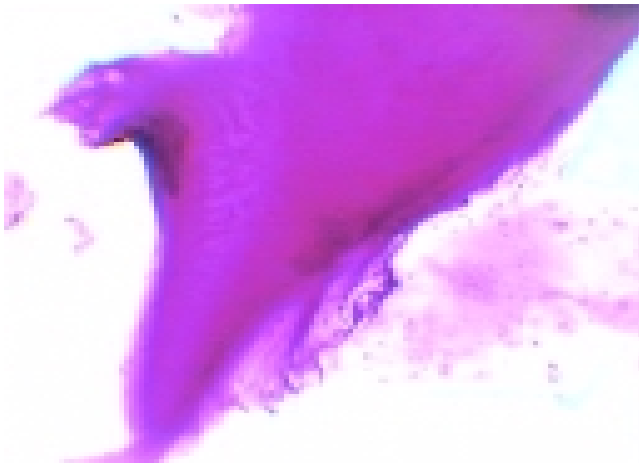


FIG. 4 Cytology smear.

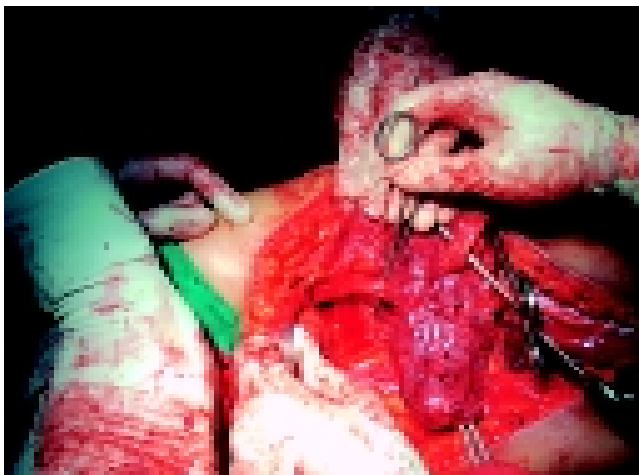


FIG. 5 Per-operative photograph - the cyst is seen encasing the sciatic nerve.

Ultrasound of the abdomen and x-ray chest were normal.

The patient was taken up for surgery after three weeks. Per-operative photograph (fig 5) demonstrates the cyst in the thigh encasing the sciatic nerve. It was dissected away from the nerve and removed in toto. Gross specimen (fig 6) shows irregular grey brown to grey white cyst measuring 23x9x8cm. Cut section revealed cystic spaces containing whitish material resembling white of egg. Histopathology confirmed the diagnosis of hydatid cyst.

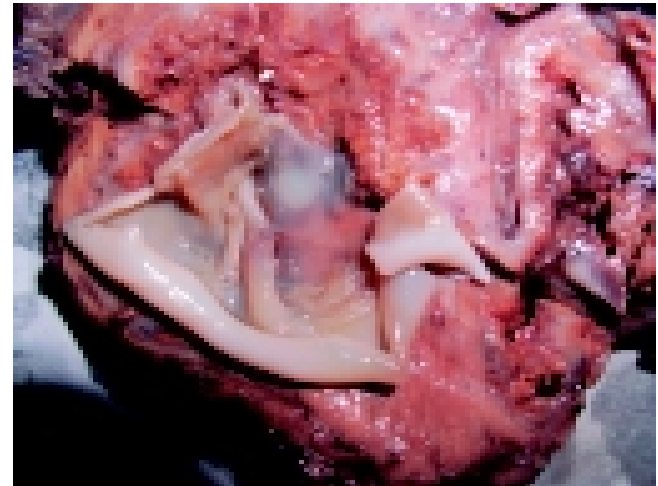


FIG.6 Gross specimen of the hydatid cyst.

DISCUSSION:

Hydatid disease is caused by the larval tapeworm of the genus *Echinococcus granulosus*, *E. multilocularis* and *E. oligarthus*. *E. granulosus* is the most common cause of hydatid disease (1). It is endemic in the Middle East as well as other parts of the world, including India, Africa, South America, New Zealand, Australia, Turkey and Southern Europe (2,3,4). Infestation by hydatid disease in humans most commonly occurs in the liver (55-70%) followed by the lung (18-35%), the two organs can be affected simultaneously in about 5-13% of cases (5,6). It can also affect the brain, heart, kidney, ureter, spleen, uterus, fallopian tube, mesentery, pancreas, diaphragm and muscles (7).

Hydatid disease of muscle is rare (8). Classically the patient presents with a long history of cystic lump with muscle fixation. Although eosinophilia is expected in patients with parasitic infestations, this may not always be seen (8). Pre-operative diagnosis can be made on Ultrasound, CT or MRI by the characteristic appearance of a unilocular or multilocular cyst with multiple daughter cysts, as was seen in our case. Aspiration of fluid by fine needle is safe, simple and an effective means to reach a working diagnosis (8).

The treatment of hydatid cyst is principally surgical. However, pre-operative medical treatment should be considered in order to sterilize the cyst, to decrease the tension in the cyst and thus reduce the chances of spillage and resultant anaphylaxis. Post-operative medical treatment reduces recurrence rate (7).

We conclude that hydatid disease can affect any organ in the body and a high suspicion of this disease is justified in any cystic neoplasm of any organ with a pre-operative diagnosis being possible radiologically and by FNAC.

REFERENCES :

1. Mirdha BR, Biswas A. Echinococcosis: Presenting as palpable lumps of breast. *Indian J Chest Dis Allied Sci* 2001;43:241.
2. Goel MC, Aggarwal MR, Misra A. Percutaneous drainage of renal hydatid cyst: early results and follow-up. *Br J Urol* 1995; 75:724-8.
3. Altinors N, Senveli E, Donmez T, Bavbek M, Kars Z, Sanli M. Management of problematic intracranial hydatid cysts. *Infection* 1995;23:283-7.
4. Brown RA, Millar AIW, Steiner Z, Krige JEJ, Burkimsher D, Cywes S, Hydatid cyst of the pancreas: a case report in a child. *Eur J Pediatr Surg* 1995;5:121-4.
5. Kir A, Baran E. Simultaneous operation for hydatid cyst of right lung and liver. *Thorac cardiovasc surgeon* 1995;43:62-4.
6. Guntz M, Coppo B, Lorimier G, Cronier P. Hydatid cyst of the liver appearing late (10-22 years) after surgical treatment of pulmonary hydatidosis. *Physiopathologic problems J Chir Paris* 1990;127:375-81.
7. Eshy SAA. Some rare presentations of hydatid cyst. *JR Coll Surg Edinb* 1998;43:347-52.
8. Kacheriwala S.M, Mehta K.D, Pillai B, Jain Y, A rare presentation of primary hydatid cyst. *Indian Journal of surgery* 2004; Vol. 66, Issue 1: 47-49.

Errata

1. **Demonstration of Entrapment in a totally Occluded Popliteal Artery - A Case report on Page 63-64**

The Authors are

NK BODHEY, AK GUPTA, M UNNIKRISHNAN

The name of the department is **Interventional Radiology**

Institute is **SCTIMST**

The city name is **Thiruvananthapuram**

2. **Endovascular Coiling of Ruptured Internal Iliac Artery Aneurysm in a Leukemia Patient - A Case Report**

The Authors are

S PURKAYASTHA, S VATTOTH, AK GUPTA, NK BODHEY, B THOMAS

The name of the department is **Interventional Radiology**

Institute is **SCTIMST**

The city name is **Thiruvananthapuram**



CME on

“Clinical Applications of Newer MRI techniques in Neurosciences”

CME on “Clinical Applications of Newer MRI techniques in Neurosciences” being organized by our department from 9th – 11th February 2007 in Lucknow

**Sanjay Gandhi Postgraduate
Institute of Medical Sciences
Raebareli Road, Lucknow – 226014**