

# Endodontic management of dens invaginatus Type IIIb: Case series

Jorge N. R. Martins<sup>1</sup>, Rui Pereira da Costa<sup>2,3</sup>, Craig Anderson<sup>4</sup>, Sérgio André Quaresma<sup>2</sup>,  
Luís S. M. Corte-Real<sup>2</sup>, Adam D. Monroe<sup>4</sup>

<sup>1</sup>Department of Endodontics, Implantology Institute, Lisbon, Portugal,  
<sup>2</sup>Department of Endodontics, International University of Catalunya, Barcelona, Spain,  
<sup>3</sup>Department of Endodontics, Lisbon University Dental School, Lisbon, Portugal,  
<sup>4</sup>Private Practice, USA

**Correspondence:** Dr. Jorge N. R. Martins  
Email: jnr\_martins@yahoo.com.br

## ABSTRACT

Dens invaginatus may be seen as a developmental malformation. It is characterized by an invagination of the enamel and dentin, creating a lumen inside the affected tooth, which may extend as deep as the apical foramen. Oehlers Type IIIb is considered the most challenging clinical conditions. The purpose of this study is to discuss the nonsurgical endodontic management of vital and necrotic dens invaginatus Type IIIb cases. Due to the complex anatomical consideration of dens invaginatus Type IIIb, endodontic treatment is extremely technique sensitive. A conservative approach was used in a vital case to treat the invaginated lumen only, to preserve the vitality of the pulp, and a more invasive approach was used in a necrotic case to debride the lumen and necrotic pulp for proper disinfection of the root canal system. Although different, all the approaches were successful. The clinical signs and symptoms were resolved. The vital case remains vital after 19 months, and the recall radiographs were able to show satisfactory periapical healing both in vital and necrotic cases. Due to the highly complex anatomy of dens invaginatus Type IIIb, the decision of preserving the pulp vitality may not be related only to pulpal diagnosis but also to the technical requirements of the treatment. Although very technically sensitive, it may be possible to treat the invaginated lumen exclusively, while preserving the vitality of the pulp. Necrotic cases may require a more aggressive approach to achieve a favorable prognosis.

**Key words:** Dens in dente, dens invaginatus, endodontic treatment

## INTRODUCTION

Dens invaginatus is a developmental anomaly that may present with a complex root canal anatomy. It has been described as an infolding of the enamel organ into the dental papilla during the soft-tissue stage of tooth formation, which may be restricted to the pulp chamber, extend to the root, or in extreme cases to the apex.<sup>[1]</sup> There is not a consensus regarding the etiology of this phenomenon, and several theories have been proposed.<sup>[1-5]</sup>

Several authors have proposed classifications systems<sup>[6,7]</sup> for dens invaginatus, also known as dens in dente, dentoid in dente, invaginated odontome, or dilated composite odontome,<sup>[8]</sup> but the most commonly used system is proposed by Oehlers.<sup>[9]</sup> This system classifies the invagination into three types, based on the extent of the invaginated dental tissues and communication with the periodontal or periapical

This is an open access article distributed under the terms of the Creative Commons Attribution-NonCommercial-ShareAlike 3.0 License, which allows others to remix, tweak, and build upon the work non-commercially, as long as the author is credited and the new creations are licensed under the identical terms.

**For reprints contact:** reprints@medknow.com

**How to cite this article:** Martins JN, da Costa RP, Anderson C, Quaresma SA, Corte-Real LS, Monroe AD. Endodontic management of dens invaginatus Type IIIb: Case series. *Eur J Dent* 2016;10:561-5.

**DOI:** 10.4103/1305-7456.195176

### Access this article online

Quick Response Code:



Website:  
www.eurjdent.com

tissues. Type I is an enamel lined minor invagination that remains in the crown, not extending beyond the cemento-enamel junction. Type II is an enamel lined invagination that goes beyond the cemento-enamel junction forming a blind sac inside the root and it may or may not communicate with the dental pulp. Type IIIa is an invagination that extends through the root and opens laterally in the periodontal tissues. Type IIIb is an invagination that extends through the root and opens apically in the periapical tissues.

These teeth may present with unusually shaped crowns often described as dilated, peg-shaped, or barrel-shaped.<sup>[1]</sup> Exaggerated palatal cingula, talon cusps, notching of the incisal edges with palatal grooving or a deep foramen coecum may also be present.<sup>[10]</sup> Dens invaginatus is usually diagnosed on a routine radiograph. The affected teeth typically display a radiolucent sac surrounded by a radiopaque enamel border. This sac can range in presentation, from a fissure to a tear-shaped loop for Type I configurations, to more extensive and unusual shapes for Type III configurations. Histologically, the invaginated tissues may show different patterns when compared to the regular tissues. The invaginated dentin may appear regular or irregular with a hypomineralized structure<sup>[11]</sup> and may contain strains of vital connective tissue<sup>[12]</sup> or even canals connecting with the dental pulp.<sup>[4]</sup> The internal enamel has been described as a hypomineralized tissue<sup>[11]</sup> that may present a different chemical constitution when compared with the external enamel.

The global prevalence of this developmental anomaly ranges from 0.3%<sup>[13]</sup> to 12%,<sup>[8]</sup> and also varies between types. A study by Kirzioglu and Ceyhan<sup>[8]</sup> evaluated 2477 patients, from those, 87.8% had regular anatomy. 11.3% showed Type I configurations, whereas Types II and III were present only in 0.7% and 0.8%, respectively, making those a quite rare occurrence. This same study reported that none of the Type I cases displayed periapical pathosis, while Types II and III had lesions in 4% and 33% of cases, respectively. Interestingly, some reports identified the presence of normal, vital pulp tissue in Types III invaginations with periapical pathology, and hypothesized that the invaginated tissues may directly communicate with the periodontal and periapical tissues, allowing microorganism progression without damaging the dental pulp.<sup>[14]</sup> Double invaginations in a single tooth have also been reported.<sup>[15]</sup>

It is hard to say which approach is better to treat Type IIIb cases that require endodontic treatment.

Each case has to be assessed on an individual basis. Preservation of the tooth structure is also one of the goals of the endodontic treatment. Although the dens removal may facilitate the proper root canal disinfection, that may result in compromised tooth structure. Keeping the invaginated tissue part and performing endodontic microsurgery to seal the apex can be one option to treat these cases and preserving more tooth structure.<sup>[16]</sup> However, surgery is a more invasive approach and should not be taken if there is an alternative, in addition, it may be refused by some patients or may not be advisable in medical compromised patients. In these cases, nonsurgical treatment options must be available.

The aim of this work is to present the nonsurgical treatment of three cases of dens invaginatus Type IIIb with or without healthy pulp. Both pulp diagnosis and technical requirements were important factors when choosing the best clinical approach for each case.

## CASE REPORT

### Case #1 - vital pulp (normal pulp)

A 20-year-old male presented without complaint for a routine dental appointment. Radiographic examination revealed atypical pulp anatomy on tooth #7 [Figure 1a], consistent with a dens invaginatus Oehlers Type IIIb, with periapical pathology [Figure 1b]. The normal response to the ice sensibility test was noted. The endodontic diagnosis of normal pulp and asymptomatic apical periodontitis was made. Direct connection between the oral environment and periapical tissue through the complete invagination was evident. The clinical condition was explained to the patient, and endodontic therapy was proposed and accepted. A cone-beam computed tomography (CBCT) scan was performed for a more comprehensive understanding of the anatomy [Figure 1c and d] and revealed that it would be possible to access the invagination without penetrating the root canal system. The treatment of the invagination alone was planned. After proper anesthesia and rubber dam isolation, a conservative access cavity into the invagination was prepared with a small round bur and a ProUltra ultrasonic tip (ProUltra, Dentsply Maillefer, USA) to avoid exposure of the dental pulp. Patency was achieved with stainless steel ISO size 15 hand files and the invagination apical opening was instrumented with a 40/0.04 Profile rotary file (Profile, Dentsply Tulsa Dental, USA) [Figure 1e-g]. No mechanical instrumentation was necessary due to the extremely large size of the invagination. Abundant irrigation with 5.25% NaOCl was performed. After

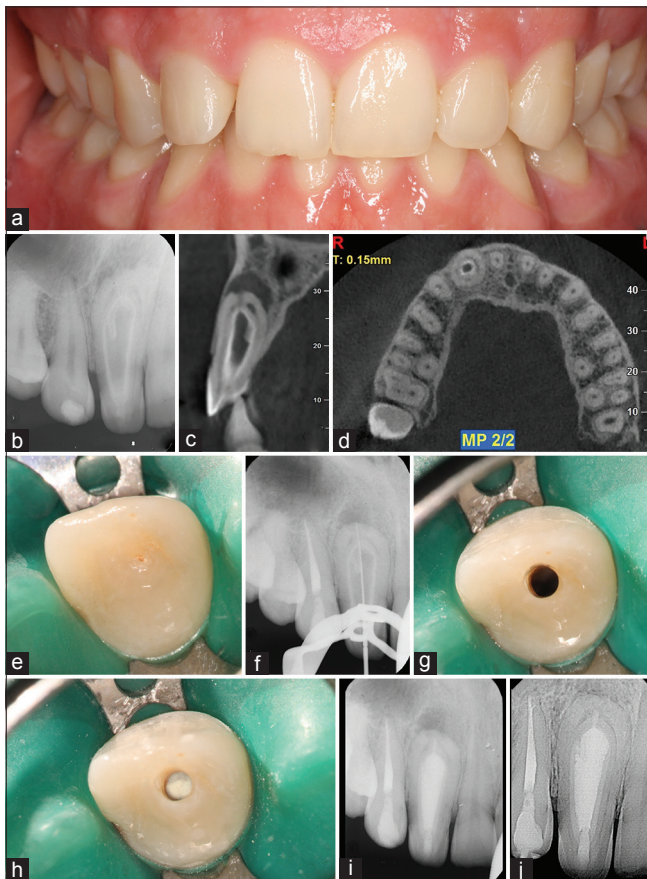


drying with paper points, the invaginated canal was filled with ProRoot MTA [Figure 1h and i]. The access opening was restored with a composite filling at the same appointment. The patient returned 19 months later for ice sensibility test and the tooth responded positively, consistent with a normal vital pulp. The recall radiograph reveals complete periapical healing when compared to preoperative and postoperative films [Figure 1j].

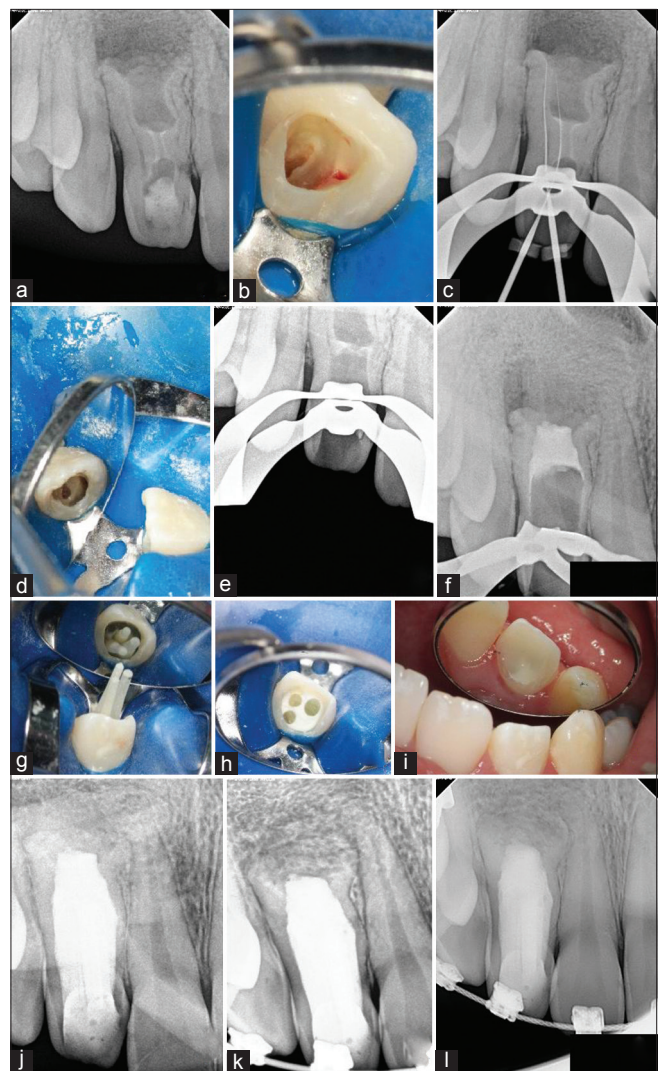
**Case #2 - vital pulp (previously initiated treatment)**

A 15-year-old female patient presented for evaluation of the upper anterior region. She had a history of pain and swelling but was asymptomatic at the initial consultation. The endodontic treatment of tooth #7 had been previously initiated by her general dentist. A clinic examination revealed a firm buccal swelling above tooth #7 with pain to palpation. There were

no other symptoms noted, and all adjacent teeth were normal to all endodontic tests. The radiographic examination revealed a dens invaginatus Oehlers Type IIIb with a malformed apex and an adjacent periapical radiolucency [Figure 2a]. A diagnosis of previously initiated endodontic therapy with asymptomatic apical periodontitis was made. Since the endodontic therapy had already been initiated and the patient's parents disliked the surgical approach option, the nonsurgical endodontic treatment plan was presented and accepted. After proper anesthesia and rubber dam isolation, the temporary filling was removed to reveal the dens [Figure 2b]. After the access was enlarged to provide better visualization, extensive vital tissue was noted around the



**Figure 1:** Treatment of tooth #7 (a) preoperative photograph (b) preoperative periapical radiograph, (c) preoperative cone-beam computed tomography sagittal slice showing a complete communication between the invagination and the periodontal tissues, (d) preoperative cone-beam computed tomography apical third axial slice, the ring shaped pulp system can be observed surrounding the invagination, (e) foramen coecum, (f) working length determination, (g) conservative access made to avoid violating the main pulp space, (h) MTA root canal obturation (i) postoperative radiograph, (j) 19 months recall (Case performed by JM)

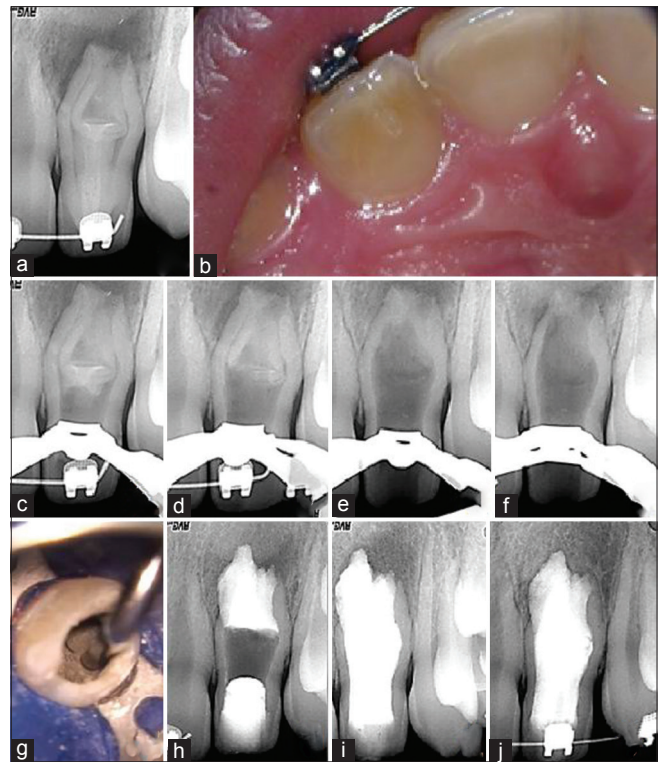


**Figure 2:** Treatment of tooth #7 (a) preoperative periapical radiograph, (b) photo of dens upon initial access showing vital pulp, (c) working length determination, (d) photo of ultrasonic removal of dens, (e) radiograph of dens removal, (f) radiographic confirmation of MTA placement in apical third, (g) fiber post photograph, (h) fiber post buildup photograph, (i) final restoration, (j) postoperative radiograph, (k) 12 months recall, (l) 24 month recall (Case performed by CA)

perimeter of the dens. Working length was obtained radiographically [Figure 2c]. Initially, the plan was to not remove the dens, however, it became apparent that the case could not be performed without its complete removal. The remainder of the dens was removed with ultrasonics over two visits [Figure 2d and e]. At this point, the periapical tissue could be visualized thru the dental operating microscope. Due to the immature apex and extremely large canal size, mechanical instrumentation was of limited benefit and irrigation with 5.25% NaOCl was contraindicated. Copious irrigation with 2% chlorhexidine was performed. After three sessions of instrumentation, irrigation and calcium hydroxide paste placement, the buccal swelling and apical palpation tenderness were resolved. The canal was obturated with MTA in the apical third [Figure 2f] followed by placement of three DT Light Fibercore post (D.T. Light - Post, Bisco, USA) and Build-it Dual Cure resin (Build-It FR, Pentron, USA) [Figure 2g and h]. A lingual composite was placed as the final access restoration [Figure 2i and j]. The patient was warned of the guarded long-term prognosis due to the amount of tooth structure lost. Recalls at 12 months [Figure 2k] and 24 months [Figure 2l] show complete periapical healing.

### Case #3 - necrotic pulp

A 13-year-old male presented with biting sensitivity and discomfort to percussion on tooth #10. The radiographic exam revealed atypical pulpal anatomy and a large periapical radiolucency [Figure 3a]. An enamel-lined invagination could be identified, running the entire length of the root, and parallel to the pulp system. This type of anatomy is consistent with dens invaginatus Oehlers Type IIIb. A palatal sinus tract was identified, and a talon cusp was present on the palatal surface [Figure 3b]. There was no response to the ice test. A diagnosis of necrotic pulp with chronic apical abscess was made. The clinical situation and treatment options were debated with the patient's parents, which excluded from the beginning the surgical approach. Due to the age of the patient and the need to limit appointment length, endodontic therapy was performed over four visits using a surgical operating microscope and rubber dam isolation. After endodontic access, rotary instrumentation was used on the invaginated canal with GTX 35/0.12 and GTX 50/0.12 rotary files (GTX, Dentspy Maillefer, USA). Start X n°3 ultrasonic tip (Start X, Dentsply Maillefer, Switzerland) and Endosonore files (Endosonore, Dentspy Maillefer, USA) were then used to eliminate the enamel-lined invagination, creating a single, and large canal. The



**Figure 3:** Treatment of tooth #10 (a) preoperative periapical radiograph, (b) photo of a talon cusp on the palatal surface, (c) radiograph showing dens removal from the coronal third, (d) radiograph showing dens removal from the middle third, (e) radiograph showing dens removal from the apical third, (f) radiograph showing complete removal of the invaginated tissues, (g) photo of the ProRoot MTA apical barrier placement, (h) radiograph showing MTA obturation, (i) fiber post buildup radiograph, (j) 12 months recall (Case performed by RPC)

canal was irrigated with 5.25% NaOCl, 10% citric acid, with passive ultrasonic agitation. Radiographs were taken during various phases of the treatment to ensure the complete removal of the invaginated tissues [Figure 3c-f]. An apical barrier was created using ProRoot MTA [Figure 3g and h], and the root was reinforced with fiber posts and dual-cure resin [Figure 3i]. A 12 months recall radiograph shows complete periapical healing [Figure 3j].

## DISCUSSION

Complex root canal morphologies require complex endodontic treatment approaches to correctly clean, disinfect, and obturate the root canal system. Each dens invaginatus configuration requires a different approach.

Dens invaginatus Type III is characterized by an extensive enamel lined invagination that penetrates through the entire root, communicating with the lateral periodontal tissues (Type IIIa) or periapical tissues (Type IIIb). The prophylactic approach for these cases should be a minimal invasive treatment.



If the pulp is vital and there are no indications of deep coronal caries or periapical pathosis, conservatively restoring the invagination with fissure sealant is the treatment of choice followed by periodic clinical and radiographic observation.<sup>[10]</sup> An extraction has been proposed in some Type III configurations as the only possible treatment,<sup>[1,17]</sup> so extra care should be taken in the treatment planning of these cases.

Apical periodontitis may be observed in teeth with pulps that remain vital; therefore, pulp sensibility tests are mandatory for obtaining a proper pulpal diagnosis, regardless of the radiographic presentation. Case #1 responded normally to ice sensibility test, suggesting a healthy pulp, although there was a clear presence of periapical periodontitis. This situation is attributed to microorganisms progressing through the lumen of the invagination to the periapical tissues without invading the dental pulp. In such cases, only the treatment of the invagination is required<sup>[14]</sup> aiming to preserve the pulp vitality. It is important to avoid any type of perforation into the dental pulp while accessing the invaginated lumen, so access is achieved with small burs and the lumen is minimally instrumented and debrided with copious irrigation and the use of ultrasonic tips. CBCT exams are also very useful diagnostic tools in these complex cases. This conservative treatment approach has been proposed for Type IIIa configuration<sup>[10,14]</sup> but not to Type IIIb because of the proximity to dental pulp. However, in this case, we were able to successfully treat a Type IIIb vital case preserving the healthy pulp. It is important to recognize that this type of conservative approach may not be always possible, as was the situation with Case #2. Although it was possible to find vital pulp (however it was not possible to know in which condition) inside the root canal system in an already initiated treatment, it was not possible at all to preserve the vitality or the invaginated tissues. In this particular case, the invaginated tissues and pulp were removed to allow a better disinfection and instrumentation of the root canal system.

In Type IIIa necrotic cases, endodontic therapy should be performed for both the root canal and the invaginated space, treating them as two independent environments. Although it may be possible to treat the root canal and the invagination separately in Type IIIb necrotic cases, it may be necessary to combine the spaces during the treatment to allow for proper debridement and disinfection, as with Case #3. In all the three cases, the root filling was performed using MTA and to balance the fragility of the remaining

dentin walls, fiber post build-up was placed in both cases where the invaginated tissues were removed.

## CONCLUSIONS

Nonsurgical endodontic therapy of dens invaginatus Type IIIb may require the treatment of the invaginated lumen only or the entire root canal system, and pulpal diagnosis and technical requirements must be considered before the execution of any treatment plan. Although dens invaginatus cases present significant challenges, if endodontic treatment is performed properly and with reference to prevailing biological principles, long-term prognosis can be positive and similar to other, less complicated morphologies.

## Financial support and sponsorship

Nil.

## Conflicts of interest

There are no conflicts of interest.

## REFERENCES

- Hülsmann M. Dens invaginatus: Aetiology, classification, prevalence, diagnosis, and treatment considerations. *Int Endod J* 1997;30:79-90.
- Grahnen H. Hereditary factors in relation to dental caries and congenitally missing teeth. In: Witkop CJ, editor. *Genetics and Disorder*. New York: McGraw-Hill; 1962. p. 194-204.
- Rushton MA. A collection of dilated composite odontomas. *Br Dent J* 1937;63:65-85.
- Kronfeld R. Dens in dente. *J Dent Res* 1934;14:49-66.
- Gustafson G, Sundberg S. Dens in dente. *Br Dent J* 1950;88:83-8.
- Hallett GE. Incidence, nature, and clinical significance of palatal invaginations in the maxillary incisor teeth. *Proc R Soc Med* 1953;46:491-9.
- Schulze C, Brand E. Dens invaginatus (dens in dente). I. *ZWR* 1972;81:569-73.
- Kirzioglu Z, Ceyhan D. The prevalence of anterior teeth with dens invaginatus in the western Mediterranean region of Turkey. *Int Endod J* 2009;42:727-34.
- Oehlers FA. Dens invaginatus (dilated composite odontome). I. Variations of the invagination process and associated anterior crown forms. *Oral Surg Oral Med Oral Pathol* 1957;10:1204-18.
- Bishop K, Alani A. Dens invaginatus. Part 2: Clinical, radiographic features and management options. *Int Endod J* 2008;41:1137-54.
- Beynon AD. Developing dens invaginatus (dens in dente). A quantitative microradiographic study and a reconsideration of the histogenesis of this condition. *Br Dent J* 1982;153:255-60.
- Omnell KA, Swanbsck G, Lindahl B. Dens invaginatus. II. A microradiographical, histological and micro X-ray diffraction study. *Acta Odontol Scand* 1960;18:303-30.
- Boyne PJ. Dens in dente: Report of three cases. *J Am Dent Assoc* 1952;45:208-9.
- Tsurumachi T. Endodontic treatment of an invaginated maxillary lateral incisor with a periradicular lesion and a healthy pulp. *Int Endod J* 2004;37:717-23.
- Zengin AZ, Sumer AP, Celenk P. Double dens invaginatus: Report of three cases. *Eur J Dent* 2009;3:67-70.
- Ozbas H, Subay R, Orduli M. Surgical retreatment of an invaginated maxillary central incisor following overfilled endodontic treatment: A case report. *Eur J Dent* 2010;4:324-8.
- Decurcio DA, Silva JA, Decurcio RA, Silva RG, Pécora JD. Influence of cone beam computed tomography on dens invaginatus treatment planning. *Dent Press Endod* 2011;1:87-93.