

# Which should be appropriate surgical treatment for subtentorial epidural empyema? Burr-hole evacuation versus decompressive craniectomy: Review of the literature with a case report

Vaner Köksal, Abdulkadir Özgür<sup>1</sup>, Suat Terzi<sup>1</sup>

Departments of Neurosurgery and <sup>1</sup>Otorhinolaryngology, School of Medicine, Recep Tayyip Erdoğan University, Rize, Turkey

## ABSTRACT

Subtentorial empyema is a rare intracranial complication of chronic otitis media. Moreover, if not correctly treated, it is a life-threatening infection. Epidural and subdural empyemas on subtentorial space have different effects. This difference is not mentioned in literature. If the distinction can be made, surgical treatment method will be different, and the desired surgical treatment may be less minimal invasive. A 26-year-old male patient was found to have developed epidural empyema in the subtentorial space. We performed a burr-hole evacuation in this case because there was low cerebellar edema. Also, the general condition of the patient was good, the empyema was a convex image on the lower surface of tentorium on magnetic resonance images, and when the dura mater base is reached during mastoidectomy for chronic otitis media, we were observed to drain a purulent material through the epidural space. After 10 days from surgery increased posterior fossa edema caused hydrocephalus. Therefore, ventriculoperitoneal shunt insertion was performed. The patient fully recovered and was discharged after 6 weeks. Complete correction in the posterior fossa was observed by postoperative magnetic resonance imaging. Burr-hole evacuation from inside of the mastoidectomy cavity for subtentorial epidural empyema is an effective and minimal invasive surgical treatment.

**Key words:** Chronic otitis media, drainage, epidural empyema, hydrocephalus, subtentorial empyema

## Introduction

Subtentorial empyema (SE) is a serious, rare, and, if untreated, life-threatening infection. It is the most feared intracranial inflammatory complication of chronic otitis media in cases of ineffective and inadequate treatment.<sup>[1,2]</sup> The subtentorial area is a rare location for the occurrence of empyema.<sup>[3-5]</sup> Emergency treatment is required for this rapidly progressive pathology. We set a surgical treatment strategy that took into account both cleaning of the primary origin of infection and its complication: Empyema had developed in the brain parenchyma. For this

purpose, two pathologies were treated during the same session through a single surgical cavity. The mastoidectomy cavity is rarely used in neurosurgery. Therefore, we intended to improve the orientation to the anatomical structures within the cavity. And also, we wanted to emphasize that the different effects of the epidural and subdural empyemas in subtentorial space.

## Case Report

A 26-year-old male with foul-smelling discharge from the left ear, since childhood which was not regularly treated, was admitted to the otorhinolaryngology clinic with complaints of severe headache, vertigo, nausea, and vomiting. The patient was hospitalized with a diagnosis of complicated

Access this article online	
Quick Response Code:	Website: www.asianjns.org
	DOI: 10.4103/1793-5482.175630

## Address for correspondence:

Dr. Vaner Köksal, Department of Neurosurgery, School of Medicine, Recep Tayyip Erdoğan University, 53020 Rize, Turkey.  
E-mail: vanerkoksal@hotmail.com

This is an open access article distributed under the terms of the Creative Commons Attribution-NonCommercial-ShareAlike 3.0 License, which allows others to remix, tweak, and build upon the work non-commercially, as long as the author is credited and the new creations are licensed under the identical terms.

**For reprints contact:** reprints@medknow.com

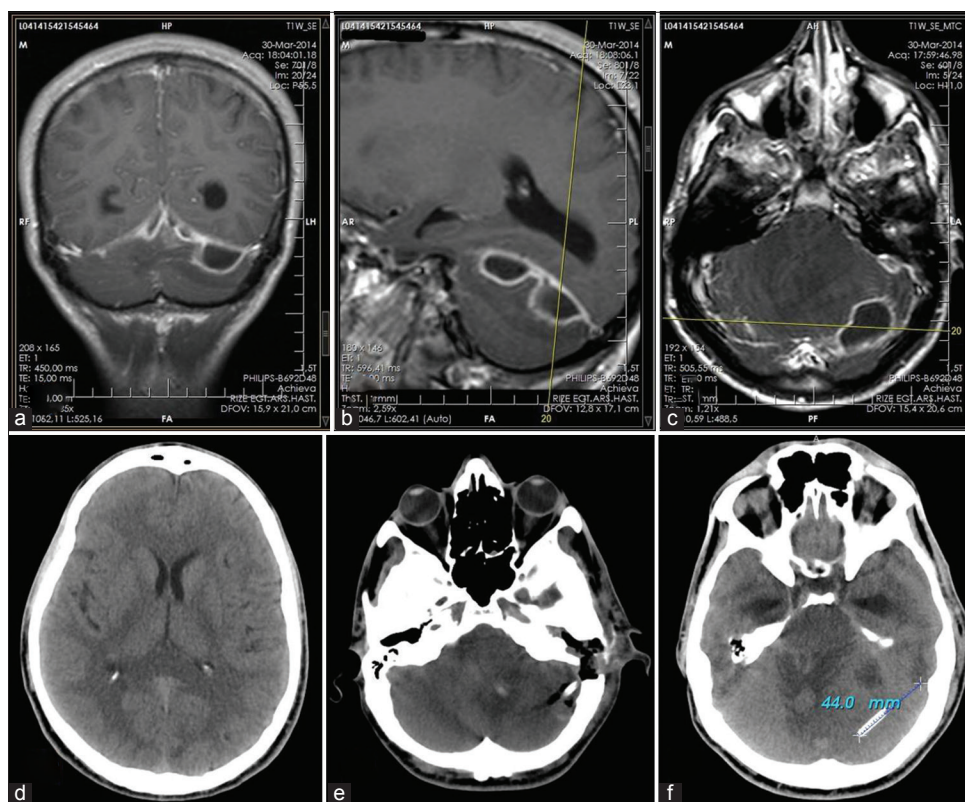
**How to cite this article:** Köksal V, Özgür A, Terzi S. Which should be appropriate surgical treatment for subtentorial epidural empyema? Burr-hole evacuation versus decompressive craniectomy: Review of the literature with a case report. Asian J Neurosurg 2016;11:81-6.

chronic otitis media. Computed tomography (CT) showed enhanced soft tissue density in the antrum, the middle of the left ear, and a defect in the lateral semicircular canal. Cranial magnetic resonance imaging (MRI) determined that the patient had no intracranial complications, and the patient was treated with ceftriaxone (2 × 2 g/day) and metronidazole (4 × 500 mg/day). After 5 days of this treatment, the patient had not improved, and a new treatment was subsequently set: Meropenem (3 × 2 g/day) and teicoplanin (400 g/day) after a loading dose. Deterioration in the patient's state of consciousness was observed in response to this antibiotherapy. A contrast MRI was performed [Figure 1a-c]. Empyema was identified in the area starting from an adjacent intracranial space, reaching to the ear with chronic otitis media, and spreading through subtentorial region, pineal region at the front, and the epidural space. Empyema was localized in two areas. Smooth contrast was identified around these cavities [Figure 1a-c]. Lesions were associated with each other through epidural space. The largest cavity was 4.4 cm away from the left ear with chronic otitis media. Despite medical treatment, the patient's condition worsened; therefore, surgery was scheduled. During the same surgical session, a mastoidectomy was performed, and SE drainage was then achieved by expanding the mastoidectomy cavity through the posterior retro-sigmoid region.

### Surgical Technique

We entered into the middle ear by folding the tympanomeatal flap forward. Granulation tissue was observed in the area of the ossicles extending through the attic. A cortical mastoidectomy was performed. The antrum was fully filled with purulent material. The infected tissues were removed. The mastoidectomy cavity was fully oriented to the course of the sigmoid and transverse sinus by being expanded through the middle and back of the cavity [Figure 2a and b]. We opened a small burr-hole on the presigmoid area. Initially, a very small amount of white-gray fluid drainage from the epidural space was observed. This drained purulent material supported our preoperative diagnosis. The burr-hole was then extended to the retrosigmoid area with a 2 mm Kerrison rongeur [Figure 2a and b]. We reached into the empyema at the 4<sup>th</sup> cm using a Nelaton probe with a stiff guidewire by initially entering the burr-hole parallel to the external ear canal, then following the canal by targeting the posterior and midline of the surface of the cranium at about a 45° horizontal angle; the guide was then removed [Figure 1d-f].

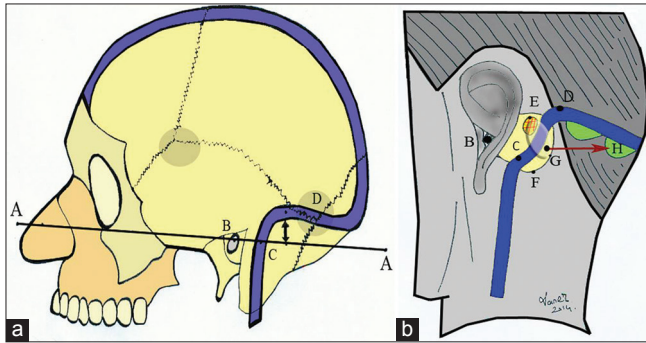
About 15 cc of purulent material was spontaneously drained out at high pressure. A light suction was performed when the spontaneous drainage stopped. Collected purulent material



**Figure 1:** Preoperative magnetic resonance imaging and early postoperative computed tomography images. (a-c) Re-operative magnetic resonance imaging of a 26-year-old male patient. Coronal, sagittal, and axial images with peripheral contrast enhancement. Subdural empyema viewed on the lower surface of tentorium (d) axial tomography of the patient 2 days before the first surgery (e and f) course of the catheter on computed tomography image and view of the mastoidectomy cavity in the bone

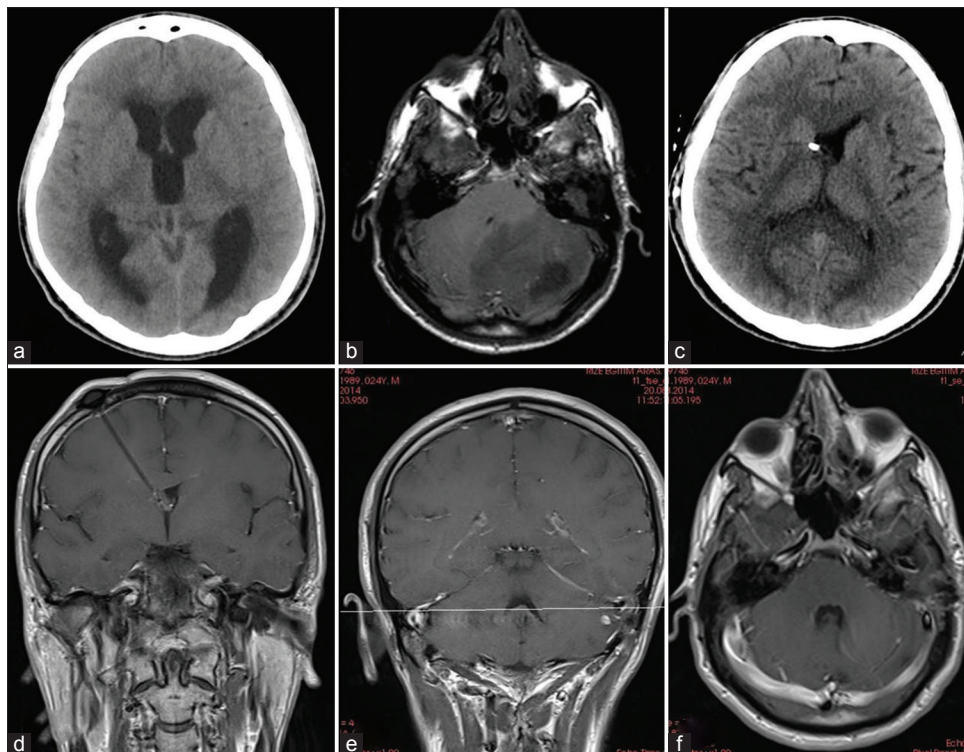
was sent for microbiological testing for both aerobic and anaerobic cultures. The drain was fixed at 3–4 cm away from the skin incision, and the lesion was left to provide a free

release of drainage. Suction was performed every other day. We did not observe any sign of empyema on the 5<sup>th</sup> day by control CT with contrast or any spontaneous drainage of empyema; therefore, drainage was stopped.



**Figure 2:** Anatomical landmarks and surgical planning. (a and b) A–A line = Reid's base line; the base line of the skull; line extending from the inferior orbital margin to the center of the external acoustic meatus (B point). C point: Sigmoid sinus. The distance between the points B and C is approximately 15–20 mm. D point: Asterion. The D point is just below the transverse sinuses. E point: Presigmoid burr-hole point. F point: Posterior edge of the mastoidectomy cavity. G point: Retrosigmoid burr-hole point. H point: Subtentorial empyema (our target). Figures were drawn for orientation to the sigmoid sinus according to the patient's surgical position and sagittal view of the cranium. The mastoidectomy cavity is depicted throughout the course of the sigmoid and transverse sinuses, and the relationship between these two sinuses is shown. The C point is 1 cm above the level A–A line. The transverse sinus is proximal to the C point

The patient had a dramatic and quick postoperative neurological improvement. However, the patient began to have a headache again on the 3<sup>rd</sup> postoperative day. Moreover, he had mild neck stiffness together with intermittent vomiting. There was a significant expansion on the third and lateral ventricle, whereas the fourth ventricle could not be selected by repeated CT in comparison to preoperative findings. It was first thought that hydrocephalus had occurred secondary to meningitis. Antiedema treatment was started due to the radiological findings of an enhanced edema in the posterior fossa by the brain CT compared to previous CT images [Figure 3a and b]. Although the patient's complaints including headache and vomiting initially resolved for 3 days, the patient began suffering from these complaints again. Therefore, a ventriculoperitoneal shunt (VPS) was inserted for acute hydrocephalus 10 days after the first surgery. Drainage of cerebrospinal fluid (CSF) with high-pressure was observed following the insertion of the ventricular catheter [Figure 3c]. The CSF was clear. Urgent CSF microscopy was performed, and white cells were not detected in the CSF. It was supposed that edema at the posterior fossa may have led to an obstructive



**Figure 3:** Computed tomography and magnetic resonance imaging images after burr-hole evacuation. (a) Hydrocephalus occurred in the early postoperative computed tomography image. (b) Posterior fossa edema on axial T1 magnetic resonance imaging 1 week after the first operation. (c) A ventriculoperitoneal shunt was inserted on the 10<sup>th</sup> postoperative day. The view 1 day after the ventriculoperitoneal shunt was inserted. (d) Coronal T1 magnetic resonance imaging after ventriculoperitoneal shunt. (e and f) Posterior fossa view on T1 magnetic resonance imaging with contrast enhancement 3 months after ventriculoperitoneal shunt insertion

type of hydrocephalus. The patient was placed on intravenous meropenem (3 × 2 g/day) and teicoplanin (400 mg/day) treatment for 20 days in the hospital. Microorganism could not be produced in microbiological cultures taken from empyema.

Following the great improvement in his general condition, he was discharged home with oral antibiotics. Total cure of subtentorial epidural empyema and complete correction in the irregularities in the posterior fossa were observed by postoperative MRI at the 1<sup>st</sup> and 3<sup>rd</sup> postoperative months [Figure 3d-f].

## Discussion

Currently, there is an increase in the use of antibiotics. However, the intracranial complications can still be seen in otitis media.<sup>[2]</sup> Although there are only a few articles on SE in literature, it is an important cause of morbidity and mortality.<sup>[1]</sup> It is more common in population with a low socioeconomic status. It occurs, especially frequently as a complication of chronic suppurative otitis media (CSOM). In this way, subdural empyema has been reported to usually develop in the temporal lobe and rarely in the cerebellum.<sup>[6]</sup> Moreover, it has been noted that empyema can spread through the posterior fossa due to the bone destruction seen when the otitis media is associated with mastoiditis.<sup>[6]</sup> We also observed that transmission of empyema occurred in the same way in our case.

Recently, Yorgancilar *et al.* identified intracranial complications in 37 out of 121 complicated CSOM cases (30.6%). In addition, brain abscess developed in 6.5% of these cases.<sup>[7]</sup> Considering this current retrospective study, it is understood that SE a type of brain abscess rarely occur in patients. However, SE is a highly progressive complication that may lead to a potentially fatal clinical entity. Despite the current application of strong antibiotherapy, the possibility of mortality is 10%.<sup>[1,2]</sup> Patients are predominantly male, and the majority of the patients in literature are children.<sup>[6]</sup> Following diagnosis, urgent antibiotherapy is recommended, with surgical drainage when necessary. Correct timing of surgery is supposed to be the most important determinant of the success of treatment.<sup>[6]</sup> Further follow-up on our patient revealed that the emergency surgical drainage of the abscess caused the infection to be only localized in the subdural space. Despite the elimination of the mass effects of the cerebellar abscess, the continued and worsening edema in the cerebellar tissue led to acute hydrocephalus. The patient's clinical condition showed improvement 15 days after the VPS was inserted. The patient's CSF was found to be uncontaminated during shunt surgery. The pia-arachnoid barrier remained intact; therefore, infection could not spread to the whole brain.<sup>[6]</sup> This result indicates the efficiency of the treatment.

The most common infectious agent is streptococci. On the other hand, a group of multiple organisms is usually responsible for otitis, mastoiditis, sinusitis, or lung abscess.

This group includes anaerobic streptococci, *Bacteroides*, and *Enterobacteriaceae*. In addition, staphylococci and *Enterobacteriaceae* are usually found in posttraumatic infections.<sup>[1,4,5]</sup> Our cultures were negative.

Furthermore, one of the indications for a canal wall down mastoidectomy (CWDM) is complicated chronic otitis media with a defect in the semicircular canal. CWDM was emergently performed in the present case due to a defect in the lateral semicircular canal and the presence of an intracranial complication.<sup>[9]</sup> However, this generated mastoidectomy cavity is an unused area in the practice of neurosurgery. Therefore, we tried to be oriented to the anatomical structures within the cavity.

Different types of surgical approaches are used in the treatment of subdural or epidural empyema. Some of these include radiological imaging-guided aspiration, irrigation in combination with a stereotactic endoscopic aspiration, and suboccipital retrosigmoid craniectomy.<sup>[8,10]</sup> In supratentorial empyema, it is possible that the pus may seep into the infratentorial compartment aided by gravity and changing head position.<sup>[11]</sup> Thus, it leads to a greater effect on neural tissue and all cerebral hemisphere. Infratentorial empyema usually different from supratentorial empyema why stay limited on subtentorial space. And it was not reaching outside of the subtentorial area on MRI. Also, we were observed to drain a purulent material through the epidural space on during surgery. This is a proof for empyema that formed in subtentorial epidural space. This is a proof for empyema that formed in epidural space.<sup>[12,13]</sup> In supratentorial empyema, because it is usually in the subdural space, emergency bifrontal decompressive craniectomy may be necessary both to reduce the intracranial pressure and to drain the subdural empyema.<sup>[14]</sup> Cerebral or cerebellar swelling induced by pus overlying the cerebral or cerebellar cortex is also affected in this way.<sup>[11]</sup> And also, our surgical method can be changed according to formed edema or the amount of swelling in the neural tissue. In our case, the most convenient point at which to open the burr-hole that enabled us to reach the empyema cavity generated by the mastoidectomy was determined to be the back side of sigmoid sinus in the same surgical cavity [Figure 2b]. Although the suboccipital retrosigmoid approach is one of the basic methods used in neurosurgery that was initially developed for vestibular schwannoma, it can be applied to treat a number of pathologies in the cerebellopontine angle.<sup>[10]</sup> Recently, many case reports on the application of retrosigmoid surgery for different tumoral lesions on the cerebellopontine angle were added to literature.<sup>[6]</sup> However, there are no publications on the use of this method we utilized in our case. Moreover, it has been reported that subtentorial epidural empyema may finally lead to hydrocephalus caused by its edematous and mass effect.<sup>[6]</sup>

One fundamental question is why did we not perform large posterior fossa craniectomy with drainage during the first

**Table 1: Advantages and disadvantages (pros-cons) for the chosen of surgical method in a subtentorial empyema**

	Pros	Cons
Decompressive craniectomy for posterior fossa	It would be enough alone and it prevents the development of hydrocephalus It may treat edema	It is not minimal invasive. And cranium defects is large  It may need duraplasty and therefore, additional areas may be contaminated with infection <sup>[6]</sup> Surgical time is long
Burr-hole evacuation	If antibiotics are effective, It would be enough alone <sup>[6,8]</sup>  A quick drainage provides If swelling decreases, hydrocephalus may improve <sup>[6,8]</sup> If the cerebellar edema less, It might be enough to subtentorial epidural empyema	Second surgical intervention may be necessary. Hydrocephalus may develop (92.5%) <sup>[6]</sup> It does not treat edema Shunt placement may require in only 21% <sup>[9]</sup> If the cerebellar edema severe, it would not be enough (such as acute supratentorial subdural empyema) <sup>[13]</sup>

treatment. In fact, the patient showed cerebellar edema and deviation of the fourth ventricle, but the lateral ventricles are not large and severe cerebellar edema formed after the first operation. Therefore, we had to perform VPS to correct the hydrocephalus after the drainage. If retrosigmoidal drainage with large posterior fossa decompression was performed, the shunt procedure might have been avoided. Nevertheless, problems associated with the shunt were observed at the end of the 1<sup>st</sup> postoperative year. We consider that a shunt is less invasive than a posterior fossa craniectomy. Craniectomy is a method of treatment applied to remove the effect of edema on the brain stem and the fourth ventricle and subsequently decrease hydrocephalus.<sup>[6,7,15,16]</sup> However, the dura membrane must be open for complete cerebellar decompression. Therefore, this procedure may lead to meningitis in patients due to contamination of the CSF.<sup>[16,17]</sup> For these reasons, we believe that performing a wide craniectomy was unnecessary, and the observation of a postoperative spontaneous drainage prevented us from planning further major surgery. However, we eventually had to perform a VPS insertion due to continued edema in the posterior fossa that led to obstructive hydrocephalus. A dramatic improvement in the patient's neurological condition was observed after the shunt insertion. Following the elimination of the pathology in the posterior fossa and the opening of the fourth ventricle, the patient no longer needed the shunt. Advantages and disadvantages (pros-cons) to the chosen of surgical method in a SE are shown in Table 1.

## Conclusion

Subtentorial epidural empyema is a suppurative intracranial infection that is rare, aggressively progressive, and potentially life-threatening. If there is subtentorial epidural empyema after orientation with both the sigmoid and the transvers sinus through the mastoidectomy cavity, surgical drainage can be applied to the empyema cavity. In addition, this is a minimally invasive procedure according to decompressive craniectomy. If

there is the subtentorial subdural empyema in posterior fossa, decompressive craniectomy is more appropriate.

## Financial support and sponsorship

Nil.

## Conflicts of interest

There are no conflicts of interest.

## References

1. Sim SK, Ch'ng CH, Tan YC, Kandasamy R, Abdullah JM. Bilateral subtentorial empyema complicated with nosocomial acinetobacter ventriculitis: A case report. *Med J Malaysia* 2014;69:86-8.
2. Wanna GB, Dharamsi LM, Moss JR, Bennett ML, Thompson RC, Haynes DS. Contemporary management of intracranial complications of otitis media. *Otol Neurotol* 2010;31:111-7.
3. Gupta M, Singh K, Lehl SS. Subdural empyema in chronic suppurative otitis media: A rarely encountered complication. *BMJ Case Rep* 2011;2011. pii: Bcr0320113976.
4. Migirov L, Duvdevani S, Kronenberg J. Otogenic intracranial complications: A review of 28 cases. *Acta Otolaryngol* 2005;125:819-22.
5. Seven H, Coskun BU, Calis AB, Sayin I, Turgut S. Intracranial abscesses associated with chronic suppurative otitis media. *Eur Arch Otorhinolaryngol* 2005;262:847-51.
6. Taha MM, Hassanain S. Subtentorial subdural empyema: Report of two cases and review of the literatures. *Turk Neurosurg* 2011;21:669-73.
7. Yorgancilar E, Akkus Z, Gun R, Yildirim M, Bakir S, Kinis V, *et al.* Temporal bone erosion in patients with chronic suppurative otitis media. *B-ENT* 2013;9:17-22.
8. Singh B, Maharaj TJ. Radical mastoidectomy: Its place in otitic intracranial complications. *J Laryngol Otol* 1993;107:1113-8.
9. Mehta RP, Harris JP. Mastoid obliteration. *Otolaryngol Clin North Am* 2006;39:1129-42.
10. Alimehmeti R, Seferi A, Stroni G, Sallavaci S, Rroji A, Pilika K, *et al.* Burr hole evacuation for infratentorial subdural empyema. *World J Clin Cases* 2013;1:172-5.
11. Nathoo N, Nadvi SS, van Dellen JR. Infratentorial empyema: Analysis of 22 cases. *Neurosurgery* 1997;41:1263-8.
12. Bonfield CM, Sharma J, Dobson S. Pediatric intracranial abscesses. *J Infect* 2015;71 Suppl 1:S42-6.
13. Colpaert C, Van Rompaey V, Vanderveken O, Venstermans C, Boudewyns A, Menovsky T, *et al.* Intracranial complications of acute otitis media and Gradenigo's syndrome. *B-ENT* 2013;9:151-6.
14. Ong YK, Goh KY, Chan C. Bifrontal decompressive craniectomy for acute subdural empyema. *Childs Nerv Syst* 2002;18:340-3.
15. Gupta A, Karanth SS, Raja A. Infratentorial subdural empyemas

- mimicking pyogenic meningitis. *J Neurosci Rural Pract* 2013;4:213-5.
16. Sengül G. Infratentorial subdural empyema. *Turk Neurosurg* 2009;19:200-2.
  17. Wilson MN, Simon LM, Arriaga MA, Nuss DW, Lin JA. The management of spontaneous otogenic CSF leaks: A presentation of cases and review of literature. *J Neurol Surg B Skull Base* 2014;75:117-24.
  18. Madhugiri VS, Sastri BV, Srikantha U, Banerjee AD, Somanna S, Devi BI, *et al.* Focal intradural brain infections in children: An analysis of management and outcome. *Pediatr Neurosurg* 2011;47:113-24.
  19. Venkatesh MS, Pandey P, Devi BI, Khanapure K, Satish S, Sampath S, *et al.* Pediatric infratentorial subdural empyema: Analysis of 14 cases. *J Neurosurg* 2006;105 5 Suppl: 370-7.