

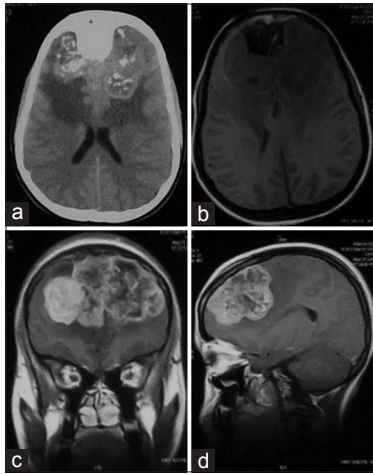
## Primary intracranial mesenchymal chondrosarcoma mimicking meningioma

Sir,

Intracranial chondrosarcoma (Ch-S) is a rare, slow-growing, locally recurrent, malignant cartilaginous skull base tumor. Intracranial mesenchymal chondrosarcoma (MsCh-S) is a rarer, more malignant variant and is rarely encountered in clinical practice.<sup>[1-2]</sup> We hereby report a case of huge MsCh-S in a young lady.

An 18-years-old girl presented with progressive headache, vomiting, and vision impairment for 1 month. Two days back, she became blind following a generalized seizure. Neurologic examination revealed bilateral no perception of light, dilated and nonreacting pupils and chronic papilledema. Computed tomography (CT) head [Figure 1a] showed a partially calcified mixed density bifrontal (L > R) lesion with midline frontal bone hyperostosis, perilesional edema and mass effect.

Magnetic resonance imaging (MRI) brain [Figure 1b, c, d] demonstrated a giant, multilobulated, heterogeneously enhancing bifrontal mass measuring  $9.3 \times 6.5 \times 6$  cm with perilesional edema and mass effect. Falx cerebri and superior sagittal sinus could not be identified in the region of tumor. A presumptive diagnosis of aggressive parasagittal-falcine meningioma was made.

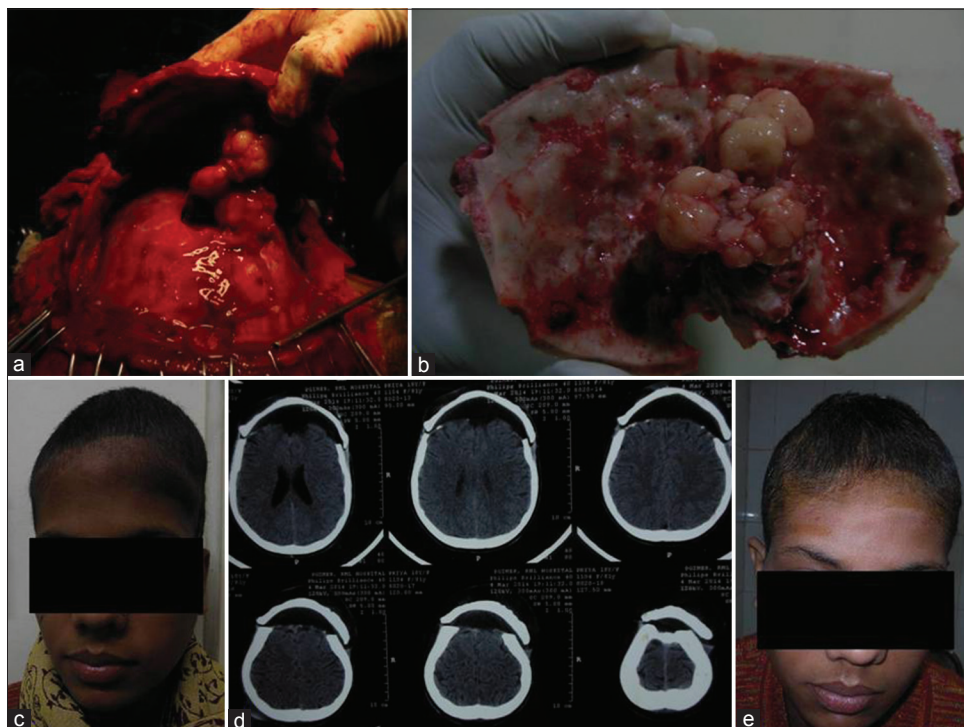


**Figure 1:** (a) Computed tomography head showing a partially calcified mixed density bifrontal (L > R) lesion with hyperostosis of midline frontal bone with perilesional edema causing mass effect and effacement of bilateral frontal horns; (b-d) magnetic resonance imaging brain showing a giant, multilobulated, heterogeneously enhancing bifrontal mass with perilesional edema causing mass effect on bilateral frontal lobes

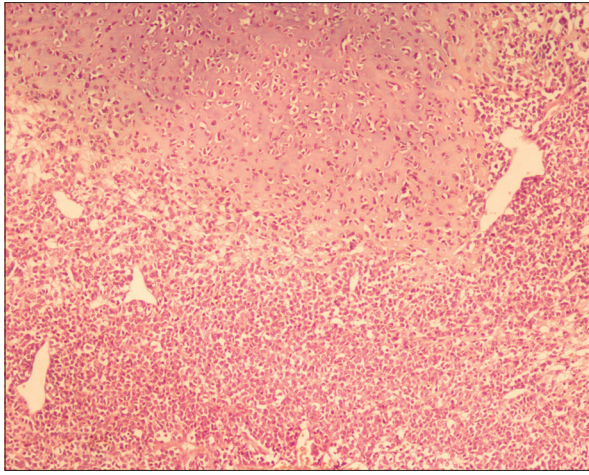
She underwent bifrontal craniectomy, total tumor excision, duraplasty using G-PATCH (an artificial dural substitute), exteriorization of frontal sinus using pedicled pericranial graft, and polymethylmethacrylate (PMMA) cranioplasty. Though falx and superior sagittal sinus were involved in the lesion [Figure 2a, b], there was a well-defined plane between the lesion and brain parenchyma. Postoperatively, she developed bifrontal CSF collection without any CSF leak, meningitis or ventriculomegaly; recurring despite repeated needle aspiration and circumferential scalp compression bandage- finally treated by theco-peritoneal shunt. Histopathological examination [Figure 3] revealed mesenchymal chondrosarcoma (MsCh-S). At 5 months follow-up, she has completed radiotherapy treatment (60 Gy), can notice hand movements close to face in left eye, and there is no recurrence.

Cartilaginous tumors (chondromas and chondrosarcomas) are usually localized in the epiphysis of long bones and pelvic bones.<sup>[3]</sup> Ch-S arises either de novo (primary Ch-S) or following malignant degeneration (1-2%) in a benign chondroma (secondary Ch-S).<sup>[1]</sup>

Primary intracranial chondrosarcomas constitute <0.16% of all brain tumors. They generally occur in young adults<sup>[1-2]</sup> with a peak around the third decade, with



**Figure 2:** (a) Peroperative photograph while elevating bifrontal bone flap; (b) elevated bone flap showing adhered tumor, bony hyperostosis, and erosion of inner table; (c) clinical photograph showing massive bifrontal swelling after tumor excision (before theco-peritoneal shunt); (d) postoperative computed tomography head showing cerebrospinal fluid collection beneath scalp and artificial bone flap; and (e) clinical photograph showing resolution of bifrontal swelling after theco-peritoneal shunt



**Figure 3:** Histopathological examination (H and E, ×10) showing sheets of undifferentiated oval to spindle shaped cells surrounded by islands of well-differentiated cartilaginous tissue

an equal sex distribution.<sup>[4]</sup> These tumors usually arise from cartilaginous synchondroses at the skull base, but occasionally from the pluripotential mesenchymal cells of the meninges.<sup>[4-5]</sup> Rare intracranial locations include brain parenchyma, choroid plexus, dura mater, tentorium,<sup>[6-7]</sup> orbit<sup>[8]</sup> etc., They usually present with seizures and symptoms secondary to mass effect-thus mimic meningiomas.<sup>[4]</sup> Though contrast MRI is the imaging modality of choice for proper anatomical delineation of these tumors, CT scan is necessary to study the extent of bone involvement and calcification. Meningiomas, solitary fibrous tumor, chordoma, hemangiopericytoma, metastasis, and vascular malformations should be considered as radiological differential diagnoses.<sup>[3]</sup> Radical tumor removal followed by adjuvant therapy and close followup is the preferred treatment strategy.<sup>[2-3]</sup> During the surgery, excessive bleeding may be encountered; for which preoperative radiotherapy or embolization has been advocated.<sup>[1]</sup>

Light microscopy showing a bimorphic pattern (undifferentiated primitive cells in a myxoid background and islands of well-differentiated cartilage) and immunohistochemical analysis are essential for correct diagnosis.<sup>[2,5,9]</sup> The cartilaginous portion is positive for S-100 protein. The undifferentiated tumor cells are positive for vimentin, but negative for glial fibrillary acidic protein, neuron-specific enolase, and cytokeratin.<sup>[10]</sup>

Intracranial chondrosarcomas carry a poor prognosis, often recurring locally and subsequently having metastatic potential.<sup>[9]</sup> The overall 5 and 10-year survival for patients with mesenchymal chondrosarcoma (all sites inclusive)

is 55% and 27% respectively.<sup>[2]</sup> Large recurrence may need re-surgery.

In our patient, preoperative clinico-radiological diagnosis of aggressive parasagittal-falcine meningioma was finally corrected to primary intracranial mesenchymal chondrosarcoma by histopathological examination, which carries a totally different prognosis. We were lucky that the extent of resection was not compromised by wrong preoperative diagnosis.

Rajeev Sharma, Banwari Lal Bairwa<sup>1</sup>,  
Minakshi Bhardwaj<sup>2</sup>, Laxmi Naraian Gupta<sup>1</sup>

Department of Neurosurgery, All India Institute of Medical Sciences,  
<sup>1</sup>Departments of Neurosurgery and <sup>2</sup>Pathology,  
PGIMER, Dr RML Hospital, New Delhi, India  
E-mail: rajufbd79@rediffmail.com

## REFERENCES

1. Marshman LA, Gunasekera L, Rose PE, Olney JS. Primary intracerebral mesenchymal chondrosarcoma with rhabdomyosarcomatous differentiation: Case report and literature review. *Br J Neurosurg* 2001;15:419-24.
2. Kan Z, Li H, Zhang J, You C. Intracranial mesenchymal chondrosarcoma: Case report and literature review. *Br J Neurosurg* 2012;26:912-4.
3. Günes M, Günaldi O, Tugcu B, Tanriverdi O, Güler AK, Cöllüoğlu B. Intracranial chondrosarcoma: A case report and review of the literature. *Minim Invasive Neurosurg* 2009;52:238-41.
4. Boccardo M, Bavaresco E, Sola S, Vitali A. Parafalcine chondrosarcoma: Report of a case and review of the literature. *J Neurosurg Sci* 2009;53:137-40.
5. Oruckaptan HH, Berker M, Soylemezoglu F, Ozcan OE. Parafalcine chondrosarcoma: An unusual localization for a classical variant. Case report and review of the literature. *Surg Neurol* 2001;55:174-9.
6. Reyaz N, Ashraf M. Intracranial extra-skeletal mesenchymal chondrosarcoma. *J Ayub Med Coll Abbottabad* 2006;18:86-7.
7. Wakabayashi Y, Kodama T, Yamashita M, Nagatomi H. Intracranial mesenchymal chondrosarcoma arising from the cerebellar tentorium: Case report. *No Shinkei Geka* 1998;26:59-64.
8. Khouja N, Ben Amor S, Jemel H, Kchir N, Boussen H, Khaldi M. Mesenchymal extraskeletal chondrosarcoma of the orbit. Report of a case and review of the literature. *Surg Neurol* 1999;52:50-3.
9. Crosswell H, Buchino JJ, Sweetman R, Reisner A. Intracranial mesenchymal chondrosarcoma in an infant. *Med Pediatr Oncol* 2000;34:370-4.
10. Chen JY, Hsu SS, Ho JT. Extraskeletal intracranial mesenchymal chondrosarcoma: Case report and literature review. *Kaohsiung J Med Sci* 2004;20:240-6.

Access this article online	
Quick Response Code:	Website: www.ijns.in
	DOI: 10.4103/2277-9167.138928