

Dental management of a child with Goldenhar syndrome

Priya Subramaniam, K. L. Girish Babu, Shurti Jayasurya, Divya Prahalad

Department of Pedodontics and Preventive Dentistry, The Oxford Dental College and Hospital, Bangalore, Karnataka, India

Address for correspondence:

Dr. Priya Subramaniam,
Department of Pedodontics and
Preventive Dentistry,
The Oxford Dental College
and Hospital, Hosur Road,
Bomanahalli, Bangalore - 560 068,
Karnataka, India.
E-mail: drpriyapedo@yahoo.com

ABSTRACT

Goldenhar syndrome is a condition with a multitude of abnormalities, classically involving ocular and ear defects, hemifacial microsomia and vertebral anomalies, which may also be associated with cardiovascular and renal malformations. This case-report presents the dental management of a 5-year-old boy diagnosed with Goldenhar syndrome.

Key words

Dental, Goldenhar syndrome, medical evaluation

INTRODUCTION

Hemifacial microsomia is a congenital asymmetry of the lower face that may be associated with a wide range of clinical manifestations. The variability of its presentation has resulted in multiple names for the same condition.

The first observation of the anomaly was reported by Arlt F in 1881.^[1] Dr. Maurice Goldenhar described three patients with epibulbar dermoids, pre-auricular skin tags, mandibular asymmetry and cervical vertebrae abnormalities in 1952. This combination of anomalies was subsequently called Goldenhar syndrome. Gorlin and Pindborg noted that hemifacial microsomia may range from mild to severe and facial development was limited to one side of the face in most cases.^[2] Goldenhar syndrome is typically associated with anomalous development of structures that originate from the first and second branchial arches.^[3]

Subsequently, Gorlin suggested the term oculo-auriculo-vertebral spectrum (OAVS), since the realization of associated systemic anomalies, such as

renal, cardiac and skeletal anomalies in addition to those in facial development.

Oculo-auriculo-vertebral spectrum is the fourth most common human craniofacial anomaly after cleft lip with or without cleft palate and craniosynostosis. The incidence has been reported to range from 1 in 3,500 to 1 in 5,600 live births; however, in children with congenital deafness, it is much higher at 1 in 1000. There is a male predominance of the syndrome at a ratio of 3:2. It is unilateral in 85% of cases with the right side more frequently affected than the left with a ratio of 3:2 and bilateral in 10-33% cases.^[4,5]

The effect of Goldenhar syndrome is more evident as the child grows, because of delays in the growth and development of the affected areas. Thus, the early detection of this condition plays an important role in prognosis.

This is a case of a 5-year-old male child having ear and eye abnormalities, reported for dental treatment and was subsequently diagnosed with Goldenhar syndrome.

CASE REPORT

A 5-year-old male child reported to the Department of Pedodontics and Preventive Dentistry, the Oxford Dental College and Hospital, Bangalore with complaint of pain in the lower left and right back teeth region. The child was born to healthy parents who had a non-consanguineous marriage. The prenatal and antenatal histories were

Access this article online

Quick Response Code:



Website:
www.ejgd.org

DOI:
10.4103/2278-9626.134849

uneventful and there was no significant family history. Medical history was non-contributory and there were no signs of developmental delay in the child as reported by the parents.

No signs of intellectual disability or any other neurological symptoms were detected. No vertebral or skeletal abnormalities were noted. Extraoral-frontal examination revealed facial asymmetry with deviation of the face to the left, mandibular hypoplasia and loss of malar prominence on the affected side. There was a marked deviation of the nasal septum towards the left side; the facial profile was convex. The left orbit was smaller in size with micro-cornea, congenital nevus, iris and retinal coloboma [Figure 1]. Hearing impairment was present with microtia on the left side and pre-auricular tags were present bilaterally [Figure 2]. The right and left sub-mandibular glands were palpable and tender.

Intra-oral examination revealed a V-shaped high arched palate [Figure 3]. Multiple carious lesions were

present with no evidence of developmental anomalies in the teeth [Figure 4]. Examination of the functional tongue movements revealed anterior tongue thrusting habit [Figure 5]. A non-spaced deciduous dentition with a bilateral flush terminal plane molar relation and an anterior open bite were noted. Panoramic radiograph revealed hypoplasia of condylar and coronoid processes, ramus and body of mandible with accentuation of the antegonial notch on the left side [Figure 6].

The child was referred to a pediatrician, ophthalmologist, cardiologist and otolaryngologist for further evaluation. Congenital and structural echocardiography, were performed to rule out cardiovascular malformations. Renal scan found renal measurements to be within normal limits. Hemogram was also found to be within the normal range. The ophthalmologic examination of the left eye confirmed congenital nevus and coloboma of retina and iris. Bilaterally, the vision was within normal range. Audiometric tests revealed mild conductive hearing loss in the right ear and moderately severe conductive hearing loss in the left. Minimal adenoidal hypertrophy was radiologically confirmed.



Figure 1: Hypertelorism with micro-cornea, congenital nevus and retinal coloboma in left orbit

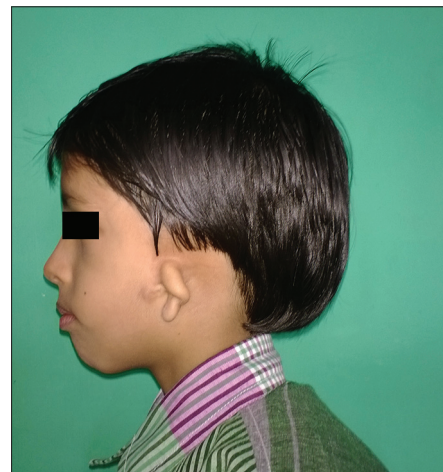

Figure 2: Malformation of the left ear

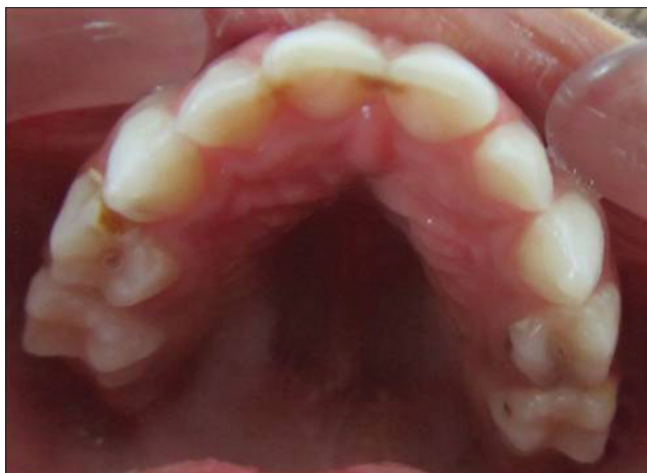

Figure 3: Pre-operative view of upper arch

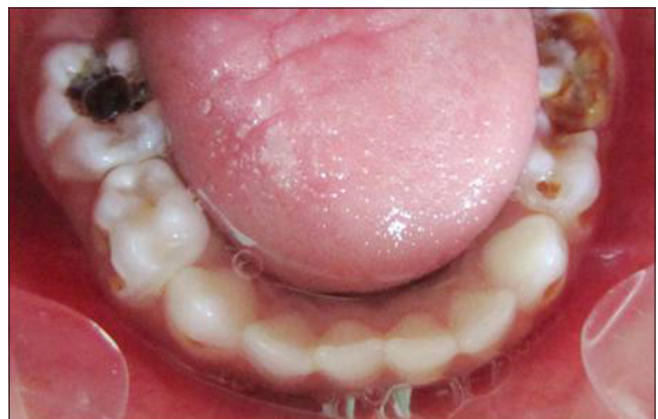

Figure 4: Pre-operative features of lower arch

The patient was diagnosed with Goldenhar syndrome based on above observations. On referral to a genetic counselor, he was found to have an autosomal dominant (DeNovo) pattern of inheritance.

From the oral health perspective, the child was placed in the high caries risk category following which full mouth rehabilitation was planned. Bite force was determined on both the sides and was found to be 142N on the right side and 340N on the left.

As there were no systemic abnormalities, antibiotic prophylaxis was not recommended. Oral hygiene was improved through professional prophylaxis and home care instructions. Composite restorations were placed on 54, 65, 73 and 83. Pulpectomy was carried out in relation to 51, 52, 61, 75 and 85 followed by stainless steel crowns for 75 and 85 and composite esthetic restorations with 51, 52 and 61. Caries excavation and glass ionomer restoration was done on 84 followed by placement of stainless steel crown. Extraction of 74 was carried out followed by placement of crown, band and loop space maintainer [Figures 7 and 8]. A fixed habit-breaking appliance was given to intercept the tongue thrusting habit [Figure 9]. Open bite correction was seen at the end of four-month recall visit [Figure 10].

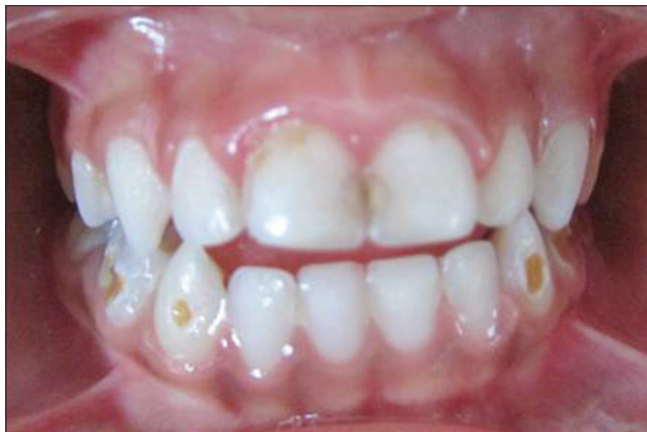

Figure 5: Anterior tongue thrust

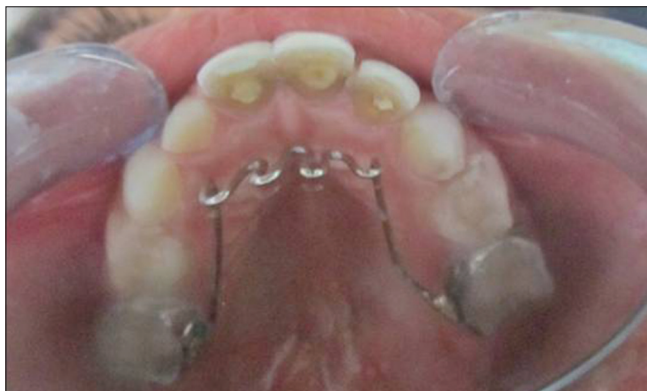

Figure 7: Post-operative view of upper jaw with tongue cribs

The consent was obtained from the patient for the use of unblinded photos as eye features, which are important for the diagnosis of Goldenhar syndrome.

DISCUSSION

Goldenhar syndrome is a condition characterized by numerous anomalies involving structures that arise from the first and second branchial arches, first pharyngeal pouch, the first branchial cleft and the primordia of the temporal bone.^[4] Etiology is said to be heterogeneous. An effect on development of a region in the embryo that will give rise to the involved structures during a critical time of embryogenesis may be a consistent factor. This effect could be a type of vascular perturbation and/or neural crestopathy.^[2]

During the time of shift in the blood supply of the first and second arches from stapedia to the external carotid artery, a resultant fetal hemorrhage can also lead to the anomaly.^[6] Experimental observations have shown that destruction of differentiating tissue in the region of the ear and jaw by an expanding hematoma can produce branchial dysplasia. Severity of the dysplasia is related to the degree of local destruction, which could help to explain the syndrome's variability of expression.^[7] Kallen *et al.*, related the mechanism of OAVS to a disturbance in neural crest development.^[8]

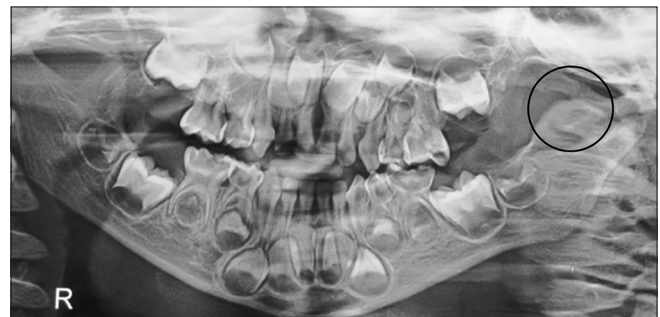


Figure 6: OPG showing hypoplasia of mandible on left side with accentuation of the antegonial notch

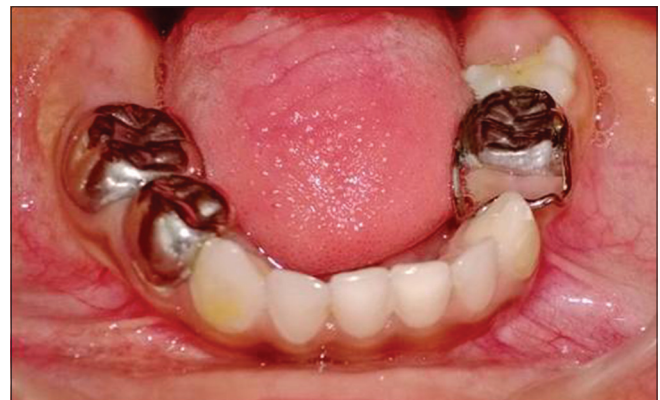

Figure 8: Post-operative view of lower jaw with crown band and loop irt 74

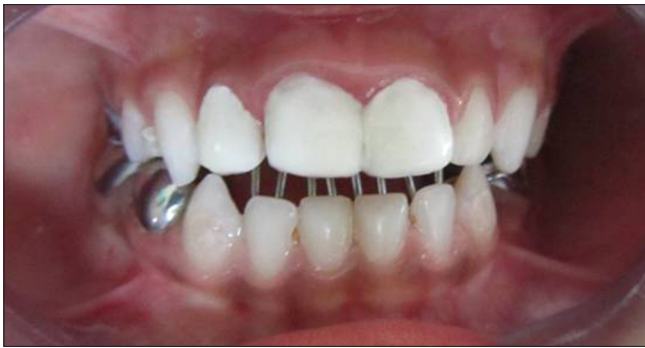

Figure 9: Tongue crib appliance for correction of anterior tongue thrust

Soltan and Holmes suggested a link between genetic causes and vascular disruption in Goldenhar syndrome.^[9] Although, most of the cases are said to be sporadic, familial cases of autosomal dominant and autosomal recessive inheritance have been reported.^[10] Furthermore, multi-factorial modes of inheritance have also been suggested. The other etiological factors include use of vasoactive drugs in the first 10 weeks of gestation, especially in conjunction with smoking, multiple gestations, fetal exposure to primidone,^[11] retinoic acid,^[12] thalidomide,^[13] maternal diabetes,^[14] rubella and influenza.^[3] In the present case, maternal history was non-contributory with no positive history of a similar condition in the family. The case was found to have an autosomal dominant (DeNovo) pattern of inheritance.

The characteristic combination of external ear anomalies and ipsilateral facial under development is the hallmark of Goldenhar syndrome.^[3] The clinical presentation of the condition may vary widely with ocular anomalies seen in 60% of cases, vertebral anomalies and ear malformations in 40% of cases and with systemic involvement in 50% of cases. Among cardiovascular anomalies, Tetralogy of Fallot and ventricular septal defects are most common.^[15] Sometimes structural kidney defects, cleft palate and other visceral anomalies may be associated with the syndrome. Craniofacial anomalies which include mandibular, zygomatic and/or maxillary hypoplasias are found in 50% of the patients.^[16]

The findings in the present case were in accordance with criteria given by Feingold and Baum, which included a lipodermoid or lipoma of the conjunctiva, an epibulbar dermoid or an upper eye lid coloboma and two of the following three: Small size or abnormal shape of the ears or pre-auricular skin tags or both, unilateral aplasia or hypoplasia of the ramus of the mandible and vertebral anomalies for the delineation of Goldenhar syndrome.^[1] However, no vertebral, cardiovascular or renal malformations were found to be associated. Although, the right side is frequently involved, in most cases our patient showed involvement of the left side of the face. A significant finding was the presence of an anterior tongue thrusting habit. The child had a deviated

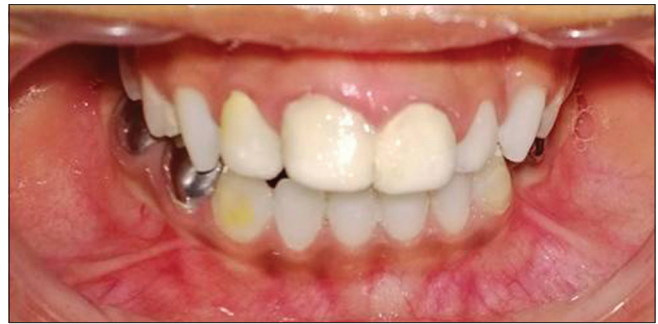

Figure 10: Correction of tongue thrust after 4 months

nasal septum and the resulting nasal congestion could have caused the tongue to lie at a lower level in the oral cavity leading to an anterior tongue thrust. The dentition showed a well circumscribed anterior open bite. Tongue training was advocated to change the pattern of swallow, following which a fixed habit-breaking appliance with palatal crib was given.

Other conditions may also resemble Goldenhar syndrome in their clinical manifestations. Kallen *et al.*, suggested a relationship between OAVS and VATER (Vertebral anomalies, Anal atresia, Tracheoesophageal fistula, Esophageal atresia, Renal anomalies and Radial Dysplasia) or CHARGE (Coloboma, Heart defects, Atresia choanae, Retardation of growth and development, Genital and urinary abnormalities and Ear abnormalities and/or hearing loss) and proposed that the connection among these anomalies could be a common pathogenetic mechanism namely, disturbed neural crest development.^[8] Klippel Feil sequence is a heterogenous condition characterized by a defect in the formation of cervical vertebrae that can have associated anomalies.

Children with Goldenhar syndrome may have limited oral opening and/or a malocclusion, oral hygiene is more difficult, putting them at increased risk of both dental caries and gingivitis.^[17] Tooth brushes with smaller heads and water-jet systems to improve mechanical removal of plaque can be recommended in those with limited mouth opening. Periodic dental visits that include topical fluoride application with emphasis on prevention of future disease are an important consideration in these individuals.

With continued growth of the child, the effects of Goldenhar syndrome may become more pronounced since the affected areas will show a significant delay in development. This can result in cosmetic concerns, breathing difficulties and malocclusion. Orthodontic therapy may be started with removable appliances. With the appearance of secondary dentition fixed orthodontic therapy can be initiated to create a proper occlusal plane and to correct malocclusions and tooth discrepancies.^[5] There are also several methods of surgical treatment, such as conventional surgical procedures (costochondral

rib graft and classical osteotomy) and the distraction technique.^[18]

Reconstruction of the external ear may be performed at six to eight years of age and structural anomalies of the eye and ears can be corrected with plastic surgery. Prognosis is good in cases without systemic involvement.^[15] A long-term periodic follow-up is necessary to monitor the child's growth and development.

REFERENCES

1. Jena AK, Duggal R. Atypical goldenhar syndrome: A case report. *J Clin Pediatr Dent* 2006;31:118-22.
2. Hartsfield JK. Review of the etiologic heterogeneity of the oculo-auriculo-vertebral spectrum (Hemifacial Microsomia). *Orthod Craniofac Res* 2007;10:121-8.
3. Vinay C, Reddy RS, Uloopi KS, Madhuri V, Sekhar RC. Craniofacial features in Goldenhar syndrome. *J Indian Soc Pedod Prev Dent* 2009;27:121-4.
4. Kokavec R. Goldenhar syndrome with various clinical manifestations. *Cleft Palate Craniofac J* 2006;43:628-34.
5. Bielicka B, Nęcka A, Andrych M. Interdisciplinary treatment of patients with Goldenhar syndrome – Clinical Reports. *Dent Med Probl* 2006;43:458-62.
6. Ryan CA, Finer NN, Ives E. Discordance of signs in monozygotic twins concordant for the Goldenhar anomaly. *Am J Med Genet* 1988;29:755-61.
7. Poswillo D. Mechanism and pathogenesis of malformation. *Br Med Bull* 1976;32:59-64.
8. Kallen K, Robert E, Castilla EE, Mastroiacovo P, Källén B. Relation between oculo-auriculo-vertebral (OAV) dysplasia and three other non-random associations of malformations (VATER, CHARGE, and OEIS). *Am J Med Genet A* 2004;127A:26-34.
9. Soltan HC, Holmes LB. Familial occurrence of malformations possibly attributable to vascular abnormalities. *J Pediatr* 1986;108:112-4.
10. Regenbogen L, Godel V, Goya V, Goodman RM. Further evidence for an autosomal dominant form of oculoauriculovertebral dysplasia. *Clin Genet* 1982;21:161-7.
11. Gustavson EE, Chen H. Goldenhar syndrome, anterior encephalocele, and aqueductal stenosis following fetal primidone exposure. *Teratology* 1985;32:13-7.
12. Lammer EJ, Chen DT, Hoar RM, Agnish ND, Benke PJ, Braun JT, *et al.* Retinoic acid embryopathy. *N Engl J Med* 1985;313:837-41.
13. Smithells RW. The incidence of limb and ear defects since the withdrawal of thalidomide. *Lancet* 1963;1:1095-7.
14. Ewart-Toland A, Yankowitz J, Winder A, Imagine R, Cox VA, Aylsworth AS, *et al.* Oculoauriculovertebral abnormalities in children of diabetic mothers. *Am J Med Genet* 2000;90:303-9.
15. Mehta B, Nayak C, Savant S, Almadi S. Goldenhar syndrome with unusual features. *Indian J Dermatol Venereol Leprol* 2008;74:254-6.
16. Lima Mde D, Marques YM, Alves Sde M Jr, Ortega KL, Soares MM, Magalhães MH. Distraction osteogenesis in goldenhar syndrome: Case report and 8-year follow-up. *Med Oral Patol Oral Cir Bucal* 2007;12:E528-31.
17. Norwood KW Jr, Slayton RL, Council on children with disabilities; Section on oral health. Oral health care for children with developmental disabilities. *Pediatrics* 2013;131:614-9.
18. Tuna EB, Orino D, Ogawa K, Yildirim M, Seymen F, Gencay K, *et al.* Craniofacial and dental characteristics of Goldenhar syndrome: A report of two cases. *J Oral Sci* 2011;53:121-4.

How to cite this article: Subramaniam P, Girish Babu KL, Jayasurya S, Pahalad D. Dental management of a child with Goldenhar syndrome. *Eur J Gen Dent* 2014;3:158-62.

Source of Support: Nil, **Conflict of Interest:** None declared.