

# Improving smile and dental esthetics: A comprehensive periodontal and restorative approach after orthodontics

Eros Chaves, Juan Rodriguez, Maria F. S. Peres, Geoffrey Cunningham

University of Oklahoma, College of Dentistry, Oklahoma City, OK, United States of America

Address for correspondence:

Dr. Eros Chaves,  
1201 N, Stonewall Avenue,  
Oklahoma City, OK 73117,  
United States of America.  
E-mail: eros-chaves@ouhsc.edu

## ABSTRACT

The esthetic demands in smile are continually rising, being thus, critical factors such as; dental midline, smile line, incisal embrasures, tooth position, width to length crown ratio, symmetry of contra-lateral gingival margins, and gingival display need to be taken into consideration. The aim of this case report is to describe the improvement of smile esthetics in a patient that after orthodontic therapy, presented excessive gingival display, asymmetric gingival margins, and shape altered upper right and left lateral incisors, which in turn compromised dental esthetics. The present clinical case required comprehensive treatment process, including proper diagnosis and excellent communication between the prosthodontist and periodontist in order to carry out successful esthetic crown lengthening and restorative dentistry. Results were followed-up for 2 years after the case completion. A pleasant smile was obtained, showing stability over time.

## Key words

Excessive gingival display, gingival margins, periodontal surgery, prosthodontics, smiling

## INTRODUCTION

As esthetic demands in smile design continually rise, critical factors such as; dental midline, smile line, incisal embrasures, tooth position, width to length crown ratio, symmetry of contra-lateral gingival margins, and gingival display need to be taken into consideration.<sup>[1-3]</sup>

Smile esthetics has been shown to play a major role in the perception of beauty and attractiveness.<sup>[2-4]</sup> Several factors that can influence smile esthetics include tooth form, position and gingival tissue levels.<sup>[1]</sup> When considering soft tissue conditions, an excessive gingival display and asymmetry of the gingival margins can impair the esthetic value of the smile.<sup>[2]</sup>

The etiology of the excessive gingival display can include vertical maxillary excess, anterior dentoalveolar

extrusion, a short or hyperactive upper lip, altered passive eruption, or a combination of these factors.<sup>[1]</sup>

When altered passive eruption is present, crown lengthening techniques such as gingivectomy and flap surgeries with bone remodeling must be performed. These critical procedures improve smile esthetics by reducing excessive gingival display, exposing anatomical crowns, and re-establishing the appropriate biologic width to facilitate restorative procedures.<sup>[5]</sup>

In some cases, esthetic crown lengthening by itself will not solve a smile esthetic problem therefore; a comprehensive treatment must be delivered via the utilization of restorative procedures to improve tooth shape, position, and color.<sup>[6]</sup>

The present case report describes a patient that, after complete orthodontic treatment, still requested improvement of his smile and esthetics. With proper diagnosis and communication, a comprehensive treatment plan was employed to provide a surgical and conservative restorative solution to manage excessive gingival display, asymmetric gingival margins, and displeasing tooth form.

## CASE REPORT

A 27-year-old systemically healthy male presented with the chief complaint of “a gummy smile” and a dislike

### Access this article online

Quick Response Code:



Website:  
www.ejgd.org

DOI:  
10.4103/2278-9626.134856

of the shape of his lateral incisors. Clinically, it was observed that under developed clinical crowns were present on the upper right and left lateral incisors and overall asymmetry of the gingival margins with excessive gingival display [Figures 1 and 2].

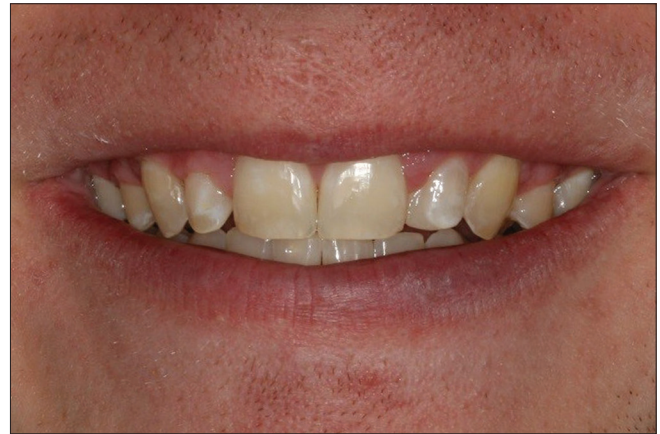The dental history included orthodontic treatment, extraction of 1<sup>st</sup> premolars and third molars, and composite restoration of upper left lateral incisor. The patient received a comprehensive examination that included evaluation of the occlusion and masticatory system to determine the health of the temporomandibular joints (TMJs), muscles of mastication, and occlusal function. Smile esthetics evaluation included documenting the initial shade, the dental/facial midline, width to height ratios of the anterior teeth, the buccal corridor, the curve of Spee in relation to the lower lip at smile and the free gingival margins, and incisal edge position in relation to lips in repose, full smile, and to F/V sounds. Complete periodontal examination, including probing depth, clinical attachment level, bleeding on probing, plaque index and crown and bone height were performed. Examination also included the crucial step of taking preliminary photographs and diagnostic casts. With this information, a diagnostic wax-up was completed to visualize the “ideal” tooth shape, potential smile frame, and gingival contour producing a clear visual of the potential restorative outcome to the prosthodontist and periodontist [Figure 3a and b].

Comprehensive examination showed that the TMJs and muscles of mastication bilaterally were without signs or symptoms of pathology. Occlusal findings showed an orthodontically corrected Class I occlusion with anterior guidance present in protrusive and canine protected guidance without crossover contact of the laterals in excursive bilaterally. Esthetically, it was found that the initial shade presented as a Vita A2 with moderate fluorosis. The dental midline was in alignment with facial midline and the incisal edge of the maxillary centrals and the occlusal plane at smile was within esthetic acceptability of the upper lip and lower lip during repose and full smile respectively. The central incisor width was 9.5 mm while the length was 11.5 mm giving a ratio of 80%. According to Tarnow *et al.*,<sup>[7]</sup> this is within the limits of esthetic acceptance. Measurement of the distance between the contact point and the bone between the centrals was approximately 5.5 mm. According to Chu *et al.*,<sup>[8]</sup> this is within the limits of maintaining a predictably filled gingival embrasure. Evaluation of the free gingival margins of the centrals in relation to the upper lip at full smile also showed an esthetically acceptable position. From there, the free gingival margins and the gingival embrasures of the lateral incisors and second premolars dropped dramatically to create an excessive gingival display and uneven gingival margins.

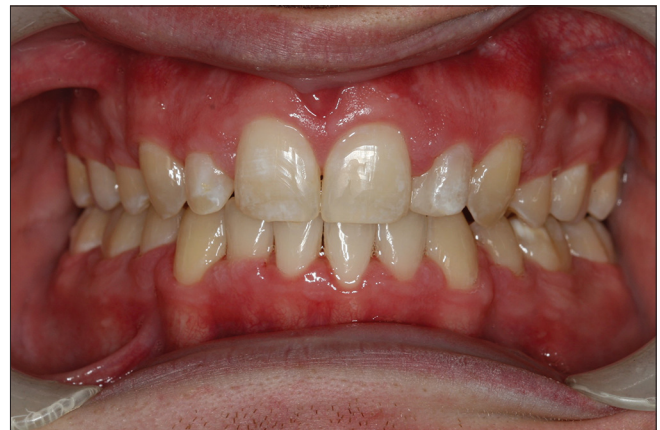After diagnosis and work-up, the patient was brought in for consultation and two treatment plans were discussed.

The first treatment plan option consisted of bleaching via take home bleaching trays, surgical crown lengthening with flap surgery and bone recontouring from the diagnostic wax-up of the proposed gingival levels, and the restoration of upper right first molar to upper left first molar with conservative preparation pressed ceramic veneers. The second treatment plan option consisted of bleaching via take home bleaching trays, surgical crown lengthening with flap surgery and bone remodeling, and restoration of the upper right and left lateral incisors with conservative preparation pressed ceramic veneers.

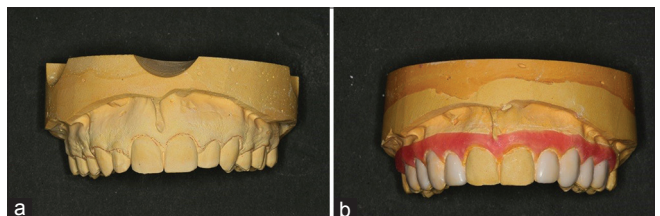
The patient decided to pursue take home bleaching (10% carbamide peroxide) for a period of 6 weeks and decide



**Figure 1:** Initial smile. After completion of orthodontic treatment and before the periodontal surgery and restorative procedures



**Figure 2:** Initial panoramic view. Under developed clinical crowns on teeth number's 7 and 10 and an overall asymmetry of the gingival margins



**Figure 3:** (a) Initial cast. (b) Diagnostic wax-up



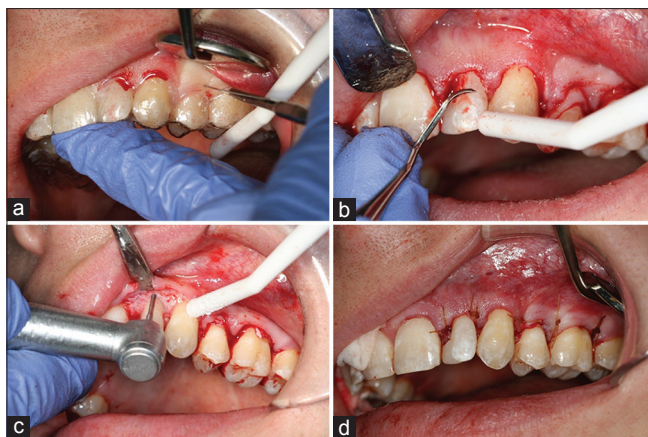
after evaluation of the results whether or not he would pursue veneers on upper right first molar to upper left first molar, or just upper right and left lateral incisors. Bleaching produced a base shade of Vita A1 but, did not completely mask the fluorosis. According to the patient, an acceptable result was achieved therefore he decided to only pursue veneers on the upper lateral incisors.

### Surgical technique

From the diagnostic wax-up, a surgical template was obtained to guide the initial incisions and to emulate the new clinical crown dimensions in the upper lateral incisors. Initially, the internal bevel incisions were performed following the surgical guide [Figure 4a] and the collar tissue was removed [Figure 4b]. A total thickness flap was then raised and the bone crest levels were visualized. Bone remodeling was performed to re-establish the biological width and finally, the flaps were sutured [Figure 4c and d]. These procedures were performed in both maxillary quadrants. The sutures were removed 1-week after the surgical procedure.

### Restorative technique

Eight weeks after crown lengthening, upper right and left lateral incisors were minimally prepared and temporized from a stent (Sil-Tech®, Ivoclar Vivodent, Amherst, NY/USA) of the diagnostic wax-up. Careful attention was given to the gingival embrasure space between the laterals and centrals. After 1-month of wearing the temporaries, it was determined that the proper contact points were established from healthy gingiva completely filling in the gingival embrasure spaces. Impressions were taken of the preparations and the information was sent to the laboratory (Valley Dental Arts, Stillwater, MN/USA) for fabrication of Lithium Disilicate Pressed Ceramic Veneers (IPS e.max® Press, Ivoclar Vivodent, Amherst, NY/USA). The veneers were waxed to full contour, pressed, cut back, and hand layered with IPS e.max® layering porcelain.



**Figure 4:** (a) Surgical template positioned and initial incisions. (b) Gingival collar being removed. (c) Total thickness flap and bone recontouring. (d) Immediate postoperative

The try-in/insertion appointment involved removal of the temporaries, cleaning the teeth, and try-in with a water soluble try-in paste. Once the patient approved the restorations, the restorations and teeth were prepared for bonding according to the manufacturer's instructions (Bisco Inc., Schaumburg, IL/USA). The veneers were then luted with Choice™ 2 light cured veneer cement according to the manufacturer's instructions (Bisco Inc.).

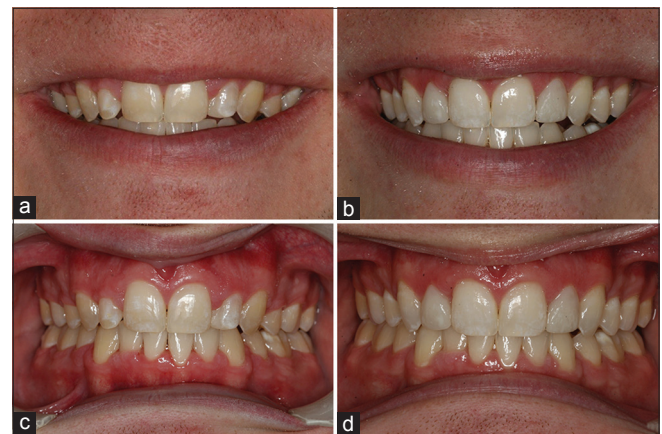The healing after the surgical and restorative procedures was uneventful. The 2 years follow-up revealed stability of the crown lengthening restorative results [Figure 5a-d].

### DISCUSSION

This case report described the successful management of delayed passive eruption after orthodontic treatment via crown lengthening and conservative restorative procedures, resulting in an esthetically pleasing smile.

Several parameters are important to achieve a pleasant smile, including teeth shape and position, and also gingival tissue levels.<sup>[1]</sup> Magne and Belser,<sup>[9]</sup> have reported an ideal zenith position of gingival contour in maxillary anterior teeth, the canines might be at a similar level or slightly apical than at central incisors, whereas a more coronal gingival contour is suggested for lateral incisors.

Investigations have shown that minimal gingival display during smile is considered more attractive. Usually, dental professionals are more critical than laypersons regarding gingival display.<sup>[10]</sup> However, it has been shown that even laypersons classify the smile as "unattractive" when it shows an inadequate amount of gum tissue and/or asymmetric crown length or width.<sup>[2]</sup> In our case, the proposed treatment that solved the asymmetry



**Figure 5:** (a) Initial smile, before the periodontal and restorative treatment. (b) Final smile, 24-month after the periodontal and restorative treatment. (c) Initial panoramic view, before the periodontal and restorative treatment. (d) Final panoramic view, 24-month after the periodontal and restorative treatment

in gingival margins, shade, and discrepancy of lateral incisor width and length lead to the patient's satisfaction with an enhanced smile.

It cannot be stressed enough that careful interdisciplinary preoperative planning is crucial in order to enhance the stability of the gingival margins after surgical treatment of altered passive eruption. In the present clinical case, a gingival and dental diagnostic wax set-up was built from which surgical guides were obtained and served as guides for the new gingival and boney contour. This type of guide might be useful not only to the surgical procedure, but also as a mockup for the patient to aid in the decision making process and to provide valuable information to the laboratory when there are demanding esthetic restorative procedures involved.<sup>[11]</sup>

Considering the surgical technique, the identification of cemento-enamel junction level and bone crest location will allow an appropriate surgical resection that appears to be stable over time thus, optimizing esthetics.<sup>[12]</sup> A recent study compared the efficacy of gingivectomy and osteotomy with apically positioned flap for crown lengthening.<sup>[5]</sup> After a 6-month evaluation, the authors concluded that the group that received osteotomy presented with better results considering stability of the crown lengthening results. These findings are in accordance with other studies that show that osseous resection is strongly recommended to obtain stable improvement of the smile.<sup>[12]</sup> Based upon that evidence, in our clinical case it was chosen to raise a full thickness flap and change the bone contour in some areas to re-establish the biologic width and assure a stable result over time.

The present case report described a comprehensive interdisciplinary approach to improve smile esthetics combining periodontal plastic surgery with conservative restorative procedures. The treatment result showed stability over time and a pleasant smile was obtained.

## REFERENCES

1. Garber DA, Salama MA. The aesthetic smile: Diagnosis and treatment. *Periodontol* 2000 1996;11:18-28.
2. Kokich VO, Kokich VG, Kiyak HA. Perceptions of dental professionals and laypersons to altered dental esthetics: Asymmetric and symmetric situations. *Am J Orthod Dentofacial Orthop* 2006;130:141-51.
3. Van der Geld P, Oosterveld P, Van Heck G, Kuijpers-Jagtman AM. Smile attractiveness. Self-perception and influence on personality. *Angle Orthod* 2007;77:759-65.
4. Malkinson S, Waldrop TC, Gunsolley JC, Lanning SK, Sabatini R. The effect of esthetic crown lengthening on perceptions of a patient's attractiveness, friendliness, trustworthiness, intelligence, and self-confidence. *J Periodontol* 2013;84:1126-33.
5. Ganji KK, Patil VA, John J. A comparative evaluation for biologic width following surgical crown lengthening using gingivectomy and osteotomy procedure. *Int J Dent* 2012;2012:479241.
6. Hempton TJ, Dominici JT. Contemporary crown-lengthening therapy: A review. *J Am Dent Assoc* 2010;141:647-55.
7. Tarnow DP, Magner AW, Fletcher P. The effect of the distance from the contact point to the crest of bone on the presence or absence of the interproximal dental papilla. *J Periodontol* 1992;63:995-6.
8. Chu SJ, Tan JH, Stappert CF, Tarnow DP. Gingival zenith positions and levels of the maxillary anterior dentition. *J Esthet Restor Dent* 2009;21:113-20.
9. Magne P, Belser UC. Natural oral esthetics. In: Magne P, Belser UC, editors. *Bonded Porcelain Restorations in the Anterior Dentition. A Biomimetic Approach*. 1<sup>st</sup> ed. Chicago: Quintessence Books; 2002. p. 57-96.
10. Pinho S, Ciriaco C, Faber J, Lenza MA. Impact of dental asymmetries on the perception of smile esthetics. *Am J Orthod Dentofacial Orthop* 2007;132:748-53.
11. Malik K, Tabiat-Pour S. The use of a diagnostic wax set-up in aesthetic cases involving crown lengthening – A case report. *Dent Update* 2010;37:303-4, 306-7.
12. Cairo F, Graziani F, Franchi L, Defraia E, Pini Prato GP. Periodontal plastic surgery to improve aesthetics in patients with altered passive eruption/gummy smile: A case series study. *Int J Dent* 2012;2012:837658.

**How to cite this article:** Chaves E, Rodriguez J, Peres MF, Cunningham G. Improving smile and dental esthetics: A comprehensive periodontal and restorative approach after orthodontics. *Eur J Gen Dent* 2014;3:170-3.

**Source of Support:** Nil, **Conflict of Interest:** None declared.