

Occipital Interhemispheric Approach for Surgical Removal of the Middle Third Falx Meningioma: Two Case Reports

Abstract

Obtaining adequate working space is difficult for complete and safe resection of meningioma located in the middle third of the falx, because of the risk of damage to the bridging veins that flow into the superior sagittal sinus and the location near the eloquent area. Consequently, surgical resection of the meningioma in the middle third of the falx tends to result in neurological disorders caused by retraction of the brain and injury of the bridging vein. Two patients underwent tumor removal of the falx meningiomas located in the middle third of the falx through the occipital interhemispheric approach (OIA) in the lateral semiprone position with the affected side down. Tumor resection was achieved safely and less invasively. Both patients suffered numbness and motor weakness, but these neurological dysfunctions improved and clinical courses were uneventful. Postoperative computed tomography showed neither brain swelling nor contusion in both cases. The OIA can remove tumor in the middle third of the falx, because the approach avoids the bridging veins, and provides working space without excessive mechanical cerebral retraction.

Keyword: Falx meningioma, microneurosurgery, occipital interhemispheric approach

Introduction

Surgical removal of parietal falx meningioma located in the middle third of the falx, especially with large size or severe lateral extension, is still challenging and generally associated with higher morbidity. Obtaining adequate working space is difficult for complete and safe resection of meningioma located in the middle third of the falx, because of the risk of damage to the bridging veins such as the rolandic vein that flow into the superior sagittal sinus (SSS) and the location near the eloquent area. Injury to the bridging vein may induce severe neurological deficit, so the bridging veins must be preserved. Consequently, surgical resection of the meningioma in the middle third of the falx tends to result in neurological disorders caused by retraction of the brain. The occipital interhemispheric approach (OIA) was originally advocated for the removal of the pineal region tumors.^[1,2] In addition, OIA with gravity retraction of the occipital lobe is useful to identify the conditions requiring increased exposure of the operative field, which can reduce the blood loss and postoperative brain swelling.^[3,4]

This is an open access journal, and articles are distributed under the terms of the Creative Commons Attribution-NonCommercial-ShareAlike 4.0 License, which allows others to remix, tweak, and build upon the work non-commercially, as long as appropriate credit is given and the new creations are licensed under the identical terms.

For reprints contact: reprints@medknow.com

We describe our experience and surgical results using OIA with gravity retraction in the lateral semiprone position for removal of parietal falx meningioma located in the middle third of the falx, and assess the advantages and pitfalls.

Case Report

Case 1

A 74-year-old male presented with numbness of the right lower extremity and right homonymous hemianopia. On admission, magnetic resonance (MR) imaging showed an extra-axial tumor lesion of 6-cm diameter with dural attachment in the middle third of the falx, with homogeneous enhancement by contrast agent [Figure 1a and b]. The corpus callosum was compressed downward [Figure 1c]. Three-dimensional computed tomography venography revealed several bridging veins including the rolandic vein passing adjacent to the tumor [Figure 1d]. However, no bridging veins flowed into the SSS in the occipital lobe [Figure 1e]. The tumor was removed through an OIA with gravity retraction of the occipital lobe in the lateral semiprone position

How to cite this article: Otani N, Wada K, Toyooka T, Mori K. Occipital interhemispheric approach for surgical removal of the middle third falx meningioma: Two case reports. *Asian J Neurosurg* 2018;13:789-91.

**Naoki Otani,
Kojiro Wada,
Terushige Toyooka,
Kentaro Mori**

*Department of Neurosurgery,
National Defense Medical
College, Tokorozawa, Saitama,
Japan*

Address for correspondence:

*Dr. Naoki Otani,
Department of Neurosurgery,
National Defense Medical
College, 3-2 Namiki,
Tokorozawa, Saitama 359-8513,
Japan.
E-mail: naotani@ndmc.ac.jp*

Access this article online

Website: www.asianjns.org

DOI: 10.4103/ajns.AJNS_158_16

Quick Response Code:



[Figure 2a and b]. Devascularization and detachment from the falx were performed, then internal decompression and dissection from the surrounding anatomical components. Macroscopic complete removal was achieved [Figure 2c-f]. The postoperative clinical course was uneventful. Five years after surgery, activities of daily living (ADL) was independent without radiological recurrence [Figure 2g and h].

Case 2

A 58-year-old female suffered left lower extremity weakness and hemianopia. MR imaging showed an extra-axial mass lesion of 7-cm diameter with dural attachment in the middle third of the falx, with homogeneous enhancement by contrast agent [Figure 3a and b]. The tumor was

removed through an OIA with gravity retraction of the occipital lobe in the lateral semiprone position [Figure 3c]. Devascularization and detachment from the falx were performed [Figure 3d and e]. Thereafter, internal decompression and dissection from the surrounding anatomical components were completed. Macroscopic complete removal was achieved [Figure 3f]. Postoperative clinical course was uneventful. Three years after the operation, ADL was independent without radiological recurrence [Figure 3g].

Discussion

Tumor localization is a major factor in selecting the surgical approach for removal of falx meningioma, which is located in the anterior, middle, or posterior third of the falx. In particular, extremely vital structures such as the vein of Trolard and rolandic vein are located adjacent to falx meningioma in the middle third of the falx. Preservation of these venous systems is crucial during resection of falx meningioma. Any vascular injuries represent major risks for both life and neurological function. Therefore, several techniques have been described for preserving the bridging veins.^[5-9] However, these bridging veins usually flow into the SSS at a right angle with the formation of venous lacunae, which will further limit the dural opening to the narrow working space of the interhemispheric fissure of the parietal lobe area.

Bridging veins are rather poorly developed or do not occur within the 4–5 cm parietal side from the torcular herophili, which enters the SSS at a 45° acute angle. Therefore, the OIA can provide adequate working space. In addition, gravity retraction in the lateral semiprone position decreases the requirement for brain retraction of the occipital lobe using a mechanical retractor, which has

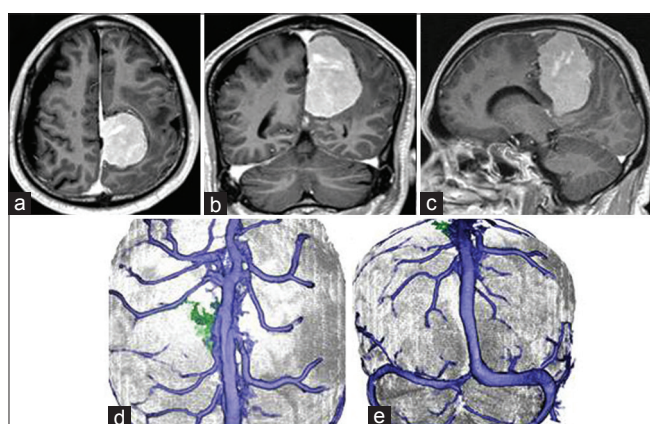


Figure 1: Case 1 – (a-c) Magnetic resonance images on admission showing an extra-axial tumor lesion of 6-cm diameter with dural attachment in the middle third of the falx, with homogeneous enhancement by contrast agent. (d and e) Three-dimensional computed tomography venograms revealing several bridging veins including the rolandic vein passing adjacent to the tumor (d). No bridging veins flowed into the superior sagittal sinus in the occipital lobe (e)

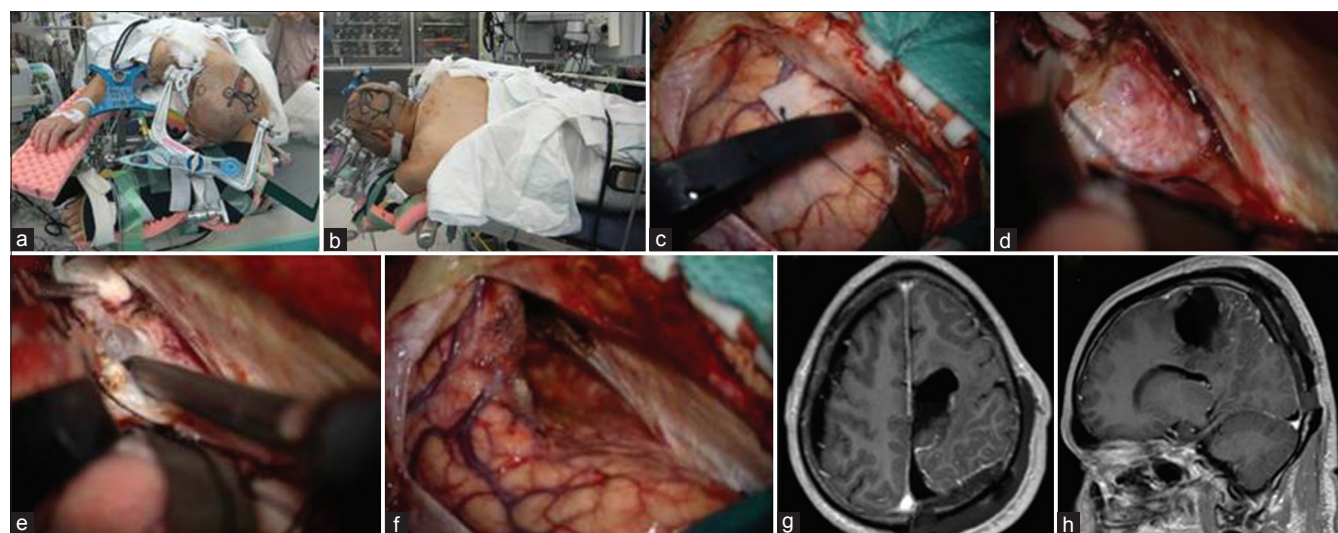


Figure 2: Case 1 – (a-f) Operative photographs showing surgical removal of the tumor through an occipital interhemispheric approach with gravity retraction of the occipital lobe in the lateral semiprone position (a and b). Devascularization and detachment from the falx were performed (c and d). Thereafter, internal decompression and dissection from the surrounding anatomical components were completed (e). Macroscopic complete removal was achieved (f). (g and h) Postoperative magnetic resonance images showing no remnant tumor or brain contusion

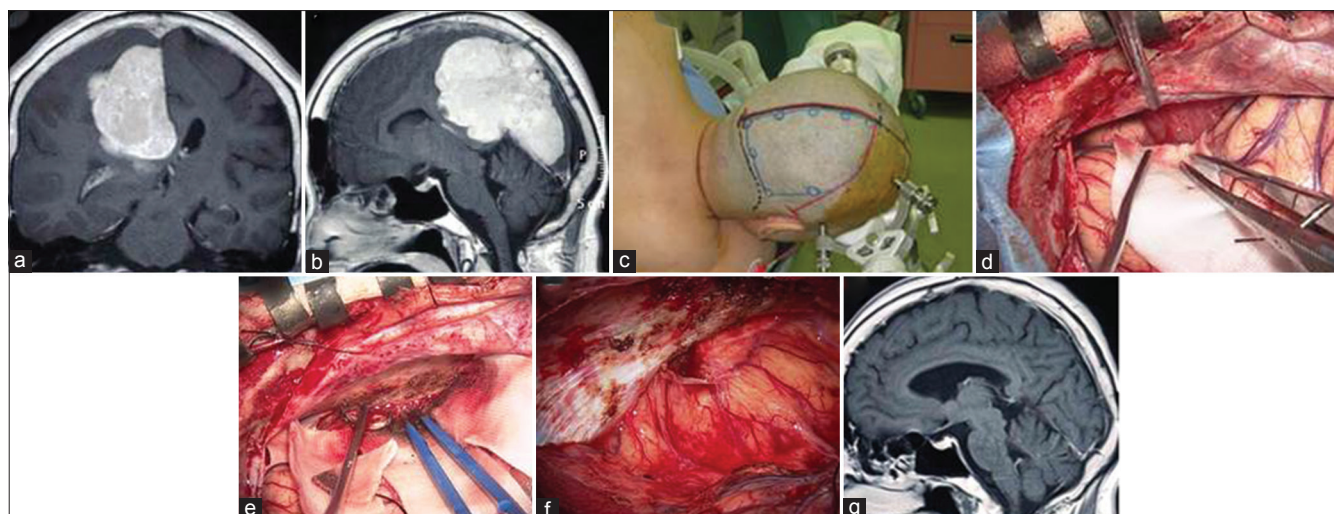


Figure 3: Case 2 – (a and b) Magnetic resonance images showing an extra-axial mass lesion of 7-cm diameter with dural attachment in the middle third of the falx, with homogeneous enhancement by the contrast agent. (c-f) Operative photographs showing surgical resection of the tumor through an occipital interhemispheric approach with gravity retraction of the occipital lobe (c). Devascularization and detachment from the falx were completed (d and e). Macroscopic complete removal was achieved (f). (g) Postoperative magnetic resonance image showing no remarkable abnormalities

important advantages for the lateral position such as lower blood loss and reduces postoperative brain swelling and cardiac, pulmonary loading.^[9] In particular, for large tumor extending to the deep venous system with considerable lateral extension, the OIA allows the deep venous system to be secured and dissected in the early stage of surgery.

Neurological complications associated with the OIA include new or worsened visual field deficit. Temporary or permanent visual disturbance occurred in one-third of the patients with lateral position after surgery,^[3] suggesting that this is related to brain retraction. However, these visual field deficits were reported to be temporary and usually resolved over the course of 3 months.^[3] The surgical corridor tends to limit the operative field to the upper lateral side in this approach, which may induce excessive retraction of the occipital lobe. Therefore, the OIA requires cerebrospinal fluid discharge via lumbar drainage, ventricular drainage of the occipital horn, or cistern opening. In addition, an adequate craniotomy to expose the torcular herophili, SSS, and transverse sinus, and dural opening will be needed to improve the surgical corridor from the inferior medial side.

Conclusion

The OIA can secure adequate working space without excessive retraction of the occipital lobe because the operative field is not limited by the presence of bridging veins. Gravity retraction in the lateral semiprone position, cerebrospinal fluid drainage, and sufficient craniotomy to expose the confluence are required for this approach.

Financial support and sponsorship

Nil.

Conflicts of interest

There are no conflicts of interest.

References

1. Kurokawa Y, Uede T, Hashi K. Operative approach to mediosuperior cerebellar tumors: Occipital interhemispheric transtentorial approach. *Surg Neurol* 1999;51:421-5.
2. Matsuda Y, Inagawa T. Surgical removal of pineal region meningioma – Three case reports. *Neurol Med Chir (Tokyo)* 1995;35:594-7.
3. Chi JH, Lawton MT. Posterior interhemispheric approach: Surgical technique, application to vascular lesions, and benefits of gravity retraction. *Neurosurgery* 2006;59 1 Suppl 1:ONS41-9.
4. Shevach I, Cohen M, Rappaport ZH. Patient positioning for the operative approach to midline intracerebral lesions: Technical note. *Neurosurgery* 1992;31:154-5.
5. Hasegawa H, Inoue T, Sato K, Tamura A, Saito I. Mobilization of the sphenoparietal sinus: A simple technique to preserve prominent frontobasal bridging veins during surgical clipping of anterior communicating artery aneurysms: Technical case report. *Neurosurgery* 2013;732 Suppl Operative:OnsE124-7.
6. Kyoshima K, Oikawa S, Kobayashi S. Preservation of large bridging veins of the cranial base: Technical note. *Neurosurgery* 2001;48:447-9.
7. Mino Y, Hirashima Y, Hamada H, Masuoka T, Yamatani K, Takeda S, *et al.* Effect of arachnoid plasty using fibrin glue membrane after clipping of ruptured aneurysm on the occurrence of complications and outcome in the elderly patients. *Acta Neurochir (Wien)* 2006;148:627-31.
8. Mori K, Ohishi H, Yamamoto M, Yamamoto T, Nakao Y, Esaki T, *et al.* Preliminary experiences with near-infrared fluorescence image-guided meningioma removal after embolization with indocyanine green and Eudragit in ethanol solution: Green embolization technique. *Innov Neurosurg* 2013;1:109-13.
9. Sugita K, Kobayashi S, Takemae T, Matsuo K, Yokoo A. Direct retraction method in aneurysm surgery. Technical note. *J Neurosurg* 1980;53:417-9.