

# Endoscopic Treatment of Hydrocephalus with Minimal Resources: Resource Utilization and Indigenous Innovation in Developing Countries like India

## Abstract

**Context:** Neuroendoscopic surgeries need specialized equipments, unavailable in neurosurgical departments of majority of public healthcare institutions of India. **Aims:** Neuroendoscopic treatment of hydrocephalus in the setting of minimal resources using utilization of available resources, inter-departmental co-ordination and indigenous innovations. **Methods:** Study was carried out at a public sector institute of India with scarce resources. Senior author (DKJ) used indigenously designed stainless steel working sheath along with equipments of 'awake endoscopic intubation system' of department of neuroanesthesia and 18 cm, 4 mm, 0° rigid telescope for neuroendoscopic surgeries for various intraventricular pathologies. **Results:** Thirty-four neuroendoscopic surgeries in 32 patients were done over last 3 years. There were 18 males and 14 females with average age of 23 years. It included hydrocephalus due to tubercular meningitis ( $n = 19$ ), neurocysticercosis (NCC) ( $n = 4$ ), intra-ventricular ( $n = 2$ ) and para-ventricular ( $n = 2$ ) space occupying lesions, aqueduct stenosis with ( $n = 2$ ) or without ( $n = 1$ ) shunt malfunction and one case each of pyogenic meningitis and right cerebellar infarction. Endoscopic third ventriculostomy (ETV) ( $n = 28$ ), septostomy ( $n = 6$ ), removals of cystic lesions ( $n = 3$ ) and biopsies of intraventricular lesions ( $n = 2$ ) were done in a total of 34 neuroendoscopic surgeries. Overall there were four failures of ETVs, which were managed by ventriculo-peritoneal shunts. Two mortalities in the study group were unrelated to the surgical procedures. **Conclusion:** Indigenous innovations and interdisciplinary co-ordination are the way ahead to tackle resource scarcity in public sector healthcare institutions of India in the scenario of plenty of neuroendoscopic trainings opportunities for young neurosurgeons and paucity of equipments required.

**Keywords:** Endoscopic third ventriculostomy, hydrocephalus, neurocysticercosis, neuroendoscopy

## Introduction

Neuroendoscopy is an established method for the treatment of hydrocephalus and intraventricular lesions. Advancements in techniques and technologies in the field of neuroendoscopy have made it safer and expanded its applications in neurosurgery including intraventricular endoscopic surgeries.<sup>[1-4]</sup> However, financial implications are a concern and the reason for its unavailability in most of the public sector hospitals and institutions in the developing countries like India. As per recent reports, only 17% of public sector hospitals in India have facilities for advanced neurosurgery.<sup>[5,6]</sup> Strangely, approximately 80%–85% of population are dependent on free health-care facilities due to high cost of treatments at private sector hospitals.<sup>[7-10]</sup> Therefore, there is an obvious mismatch between the facilities

available and the number of patients. The need of the hour is low-cost innovations and judicious utilization of available resources for advanced surgeries, which can benefit underdeveloped and developing nations. Senior author, after gaining years of experience of neuroendoscopic surgeries at advanced facility centers,<sup>[11-17]</sup> presents his experience of endoscopic treatment of hydrocephalus in 32 patients at a resource-starved public sector institute of India using indigenous innovations and utilizing available resources judiciously.

## Materials and Methods

The public sector institute, where the study was done, has newly developed neurosurgery department. No facilities pertaining to neuroendoscopic surgery or microneurosurgery are available. However, endoscopic awake intubation system with

Deepak Kumar Jha,  
Mukul Jain<sup>1</sup>,  
Ishita Pant<sup>2</sup>,  
Rima Kumari<sup>3</sup>,  
Renu Goyal<sup>4</sup>,  
Arvind Arya<sup>1</sup>,  
Suman Kushwaha<sup>5</sup>

Departments of Neurosurgery,  
<sup>1</sup>Neuroanesthesia,  
<sup>2</sup>Neuropathology,  
<sup>3</sup>Neuroradiology, <sup>4</sup>Microbiology  
and <sup>5</sup>Neurology, Institute of  
Human Behavior and Allied  
Sciences, New Delhi, India

### Address for correspondence:

Dr. Deepak Kumar Jha,  
Department of Neurosurgery,  
All India Institute of  
Medical Sciences, Jodhpur,  
Rajasthan- 342005, India.  
E-mail: jhadeepak2@rediffmail.  
com

### Access this article online

Website: [www.asianjns.org](http://www.asianjns.org)

DOI: 10.4103/ajns.AJNS\_211\_16

### Quick Response Code:



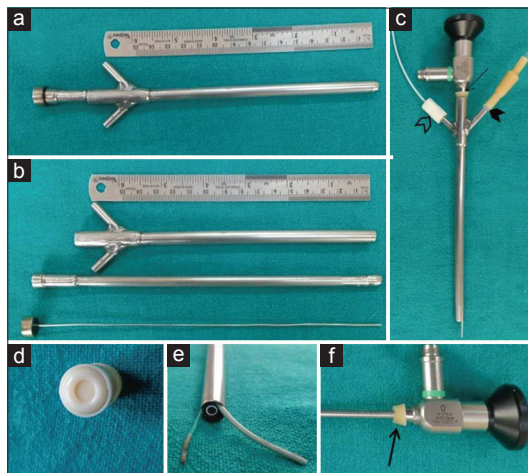
**How to cite this article:** Jha DK, Jain M, Pant I, Kumari R, Goyal R, Arya A, *et al.* Endoscopic treatment of hydrocephalus with minimal resources: Resource utilization and indigenous innovation in developing countries like India. *Asian J Neurosurg* 2018;13:607-13.

This is an open access journal, and articles are distributed under the terms of the Creative Commons Attribution-NonCommercial-ShareAlike 4.0 License, which allows others to remix, tweak, and build upon the work non-commercially, as long as appropriate credit is given and the new creations are licensed under the identical terms.

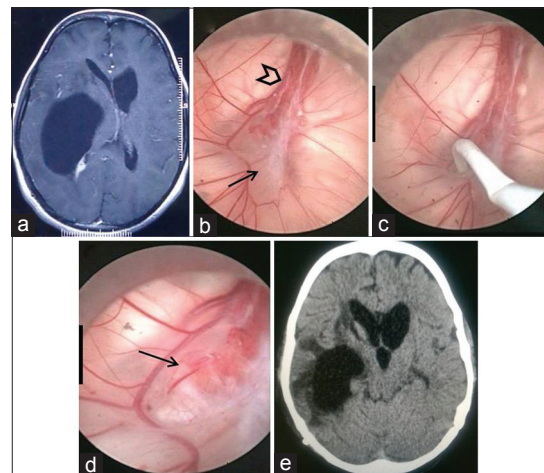
For reprints contact: [reprints@medknow.com](mailto:reprints@medknow.com)

2.7 mm flexible telescope (Broncho-Fiberscope, Karl Storz) with single chip camera, light source, and monitors was procured by neuroanesthesia department for cervical spine and craniovertebral surgeries in the year 2012. Author used 18 cm, 4 mm, 0° rigid telescope and indigenously made stainless steel working sheath for cranial endoscopic surgeries [Figure 1]. Stainless steel working sheath of 18 cm length with outer and inner diameters of 7 mm and 6.5 mm, respectively, was used [Figure 1a-c]. There were two side ports/working channels, 2 cm each inclined at about 45° to the surgeon's end of the long axis of the working sheath [Figure 1-c]. These side working channels were used for angiographic and Fogarty catheters and Ringer's lactate irrigation. Cost of the working sheath including welding charges was approximately 100–150 Indian national rupees. "Needle adapter" of intravenous drip set and "intermittent injection Luer Lock Cap (LLC) with rubber diaphragm" of central venous lines fit snugly to the side working ports [Figure 1c and d]. A 5 mm soft rubber gasket over the surgeon's end of the telescope rod snugly fits into the main or straight channel making it watertight [Figure 1f]. A hole made in the center of the LLC, meant for injections, was used for insertion of the angiographic and Fogarty catheters through the side working channels to make the connection watertight [Figure 1c]. Cut lengths of 5-F angiographic catheters were used for endoscopic perforation of various membranes such as third ventricular floor, septum pellucidum, or postinfective membranous gliotic adhesions while 3-F Fogarty balloon was used for dilatation of these openings [Figure 2]. Mild suction by 5–10 ml syringes was used through the angiographic catheter to remove cysts, tubercles, or tumor tissues for biopsy. For larger cysts, telescope and partially sucked

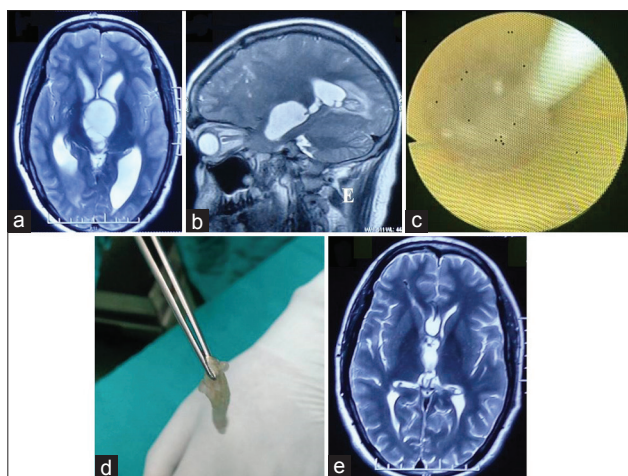
cyst wall into the angiographic catheter were gradually pulled out together to facilitate their delivery through the working sheath [Figure 3c]. The sites of incisions were selected based on the side and site of ventricular entry. For endoscopic third ventriculostomy (ETV), precoronal burr holes of 12–15 mm diameter were made. Working sheath was held by the assistant and the surgeon (DKJ) or fixed by a three-arm endoscope holder designed and made by the author himself. Basic endoscopic techniques were used as described in our earlier reports except using indigenously designed working sheath.<sup>[11-17]</sup> Third ventricular floors were bluntly perforated with the help of the tip of the 5-F angiographic catheter over the dorsum sellae to avoid basilar artery injury. Thick floors in postmeningitic cases were cautiously perforated over the posterior surface of the dorsum sellae, and ooze from the margins was controlled by inflating balloon of Fogarty. Continuous irrigation with Ringer's lactate solution at 37°C was done to maintain a clear view.<sup>[17]</sup> Warm Ringer's lactate solution was used for irrigation whenever bleeding was encountered. Dangerous increases in intracranial pressure (ICP) were avoided by maintaining inflow at permissible pressure (about 10 ml/min) with sufficient outflow of irrigating fluid.<sup>[18]</sup> Whenever adhesions were found difficult to perforate or the third ventricular floor anatomy was distorted, further attempts were aborted and ventriculoperitoneal (VP) shunts were done in the same sitting. Postoperatively, in patients of third ventriculostomy and septostomies, cerebrospinal fluid (CSF) drainage by lumbar punctures was done on postoperative days 3 and 5 to maintain CSF flow and drain intraventricular contamination of minimal blood, cystic contents, or tumor tissues released during surgery.<sup>[11,13,14,17]</sup> Patients were subjected to VP



**Figure 1:** (a) Stainless steel working sheath used for neuroendoscopic surgeries. (b) Stainless steel working sheath with two side channels, trocar and stylet. (c) Working sheath with the telescope with soft rubber gasket (arrow), 5-F angiographic catheter through Luer Lock Cap (hollow arrowhead), and intravenous drip set "needle adapter" (black arrowhead) in the side channels. (d) Intermittent injection Luer Lock Cap with rubber diaphragm. (e) Ventricular end of the working sheath showing tip of the telescope, 5-F angiographic and 3-F Fogarty catheters. (f) Rigid telescope with soft rubber gasket (arrow)



**Figure 2:** (a) Contrast-enhanced T1-weighted axial magnetic resonance image of the brain shows entrapped temporal horn, dilated right temporal horn with effaced right lateral ventricle with midline shift. (b) Endoscopic view of membranous adhesion (arrow) posterior to the choroid plexus (arrowhead) of temporal horn. (c) Endoscopic image of membranous adhesion being perforated using angiographic catheter. (d) Endoscopic image of torn membranous adhesion (arrow). (e) Postoperative axial noncontrast computed tomography image of the brain shows reduction in size of temporal horn, midline shift, and visible surface cisterns



**Figure 3:** (a) T2-weighted axial magnetic resonance image of the brain shows multiple thin-walled cystic lesions in the third ventricle with dilated lateral ventricles and periventricular lucency. (b) T2-weighted paramedian sagittal magnetic resonance image of the brain shows cystic lesions between temporal horn and atrium of lateral ventricle with dilated temporal horn. (c) Endoscopic image of partially sucked cystic lesion in the 5-F angiographic catheter within the working sheath. (d) Cystic lesion held in the forceps delivered through the working sheath. (e) Postoperative T2-weighted axial magnetic resonance image shows normal sized ventricles

shunt surgery, if ETV or septostomy failed, based on postoperative clinico-radiological evaluations. In patients of intraventricular cysts or tumors, definitive surgeries, if required, were contemplated depending on the results of the histopathological examinations.

Patient selection was done stringently, and only those patients were admitted for neuroendoscopic treatments, who could not get admissions in at least two well-equipped public sector hospitals, were unable to afford the cost of the private sector hospitals, and were showing progressive neurological deterioration. Patients and relatives were explained about the available facilities, treatments planned, and risks associated with it.

Patients were followed up at 6 weeks, 3, 6, and 12 months after surgery and then at yearly intervals. Repeat computed tomography (CT) and/or magnetic resonance imaging (MRI) studies were done at 3–6 months and then at yearly intervals or earlier if required.

## Results

Thirty-four neuroendoscopic procedures in 32 patients of hydrocephalus, due to various etiologies treated by neuroendoscopic methods in the past 3 years, formed the study group. There were 18 males and 14 females with average age of 23 years (range 1 year to 65 years), which included 14 children (<18 years of age). Patient characteristics including their diagnoses and surgical treatments are summarized in Tables 1 and 2. Most common diagnosis of the patients operated by intraventricular neuroendoscopic surgeries was obstructive hydrocephalus due to tubercular meningitis (TBMH) ( $n = 19$ ), followed

by hydrocephalus due to neurocysticercosis (NCC) ( $n = 4$ ) and tumors of intraventricular ( $n = 2$ ) or periventricular locations ( $n = 2$ ). There were three follow-up cases (cases 1, 16, and 17) of TBMH who had completed their antitubercular chemotherapies, presented due to adhesive occlusions of the foramen of Monro (cases 16 and 17), and entrapped temporal horn (case 1) [Figure 2]. Simple perforation of the membranous adhesions led to their recoveries [Figure 2]. Five cases (cases 1, 3, 9, 16, and 26) of shunt malfunction were earlier operated by VP shunts at other centers for NCC (case 4), TBMH (cases 1 and 17), and aqueduct stenosis (AS) (cases 10 and 27). All these patients had clinical and radiological signs of raised ICP and showed progressive neurological deterioration [Table 1]. MRI and CT were done whenever required depending on the clinical conditions of the patients including contrast studies.

Overall, there were 2 failures of ETVs, both in patients of TBMH (cases 20 and 21), whereas ETV could not be done in a patient (case 6) of TBMH due to distorted anatomy of the third ventricular floor. There were 2 mortalities, one in a patient of TBMH (cases 9) and another in a case of ischemic right cerebellar infarction with hydrocephalus (case 19). Both of these patients were in poor clinical conditions. ETV was effective in 16 (81%) out of 19 patients of TBMH, whereas remaining three patients were follow-up cases of TBMH with adhesive obstructions of the foramen of Monro ( $n = 2$ ) and entrapment of temporal horn ( $n = 1$ ). VP shunts were done in three patients (cases 6, 20 and 21) in whom ETV could not be done or failed. In all patients of intracranial tumor-related hydrocephalus ( $n = 4$ ), definitive surgeries were undertaken 5 days–2 weeks after neuroendoscopic surgeries, once patients improved clinically and stabilized hemodynamically. Neuroendoscopy was partially effective in one case of NCC (case 4). ETV was done twice in addition to septostomy during second surgery along with removal of multiple third ventricular and temporal horn cysts [Figure 3]. Although ETV failed in this patient, multiple shunt systems were avoided due to septostomy and removal of third ventricular and temporal horn cysts, which could have caused shunt malfunction. Two patients (cases 9 and 19) died on the 7<sup>th</sup> and 10<sup>th</sup> postoperative days, respectively, but there was no procedure-related complication or mortality. Average follow-up of the patients was 13.5 months (range 5 months–3 years).

Durations of surgery and ease of performing endoscopic procedures were similar to any of the available working sheaths, except inability to use cautery (due to unavailability) and rigid instruments (due to design of the telescope and the working sheath) which would have made removals of selected solid intraventricular lesions possible.

## Discussion

Health-care infrastructure in India is insufficient to take care of the population at large.<sup>[5–10]</sup> Recent studies have

**Table 1: Patient characteristics along with treatments and results**

Case number	Age	Sex	Diagnosis	Clinical status	Surgical procedure	Result and further treatment
1	13	Male	FUC TBMH with VP shunt with entrapped right temporal horn	Left hemiparesis, behavior abnormality, slurring speech	Endoscopic cystoventriculostomy	Improved
2	15	Female	TBMH	Grade* III	ETV	Improved
3	28	Male	TBMH	Grade* III	ETV	Improved
4	22	Male	FUC NCC hydrocephalus with shunt malfunction	Headache, vomiting, altered sensorium	ETV with removal of third ventricular multiple cysts and left foraminal dilatation	Improved, reoperated after 2 years
	24	Male	FUC NCC hydrocephalus with failed ETV	Difficulty in walking, memory disturbances	Removal of third ventricular multiple cysts, septostomy, and ETV	Improved, reoperated after 1 year
	25	Male	FUC NCC hydrocephalus with entrapped left temporal horn	Headache, altered sensorium	Endoscopic removal of temporal (left) horn NCC	Improved, reoperated for VP shunt after 3 days
5	20	Female	Lateral ventricular neurocytoma with foraminal obstruction	Headache, vomiting	Endoscopic septostomy with biopsy of intraventricular tumor	Improved
6	28	Female	TBMH	Grade* IV	ETV	ETV could not be done due to distorted floor. VP shunt done
7	8	Female	Adult-onset idiopathic aqueduct stenosis	Headache, vomiting, visual disturbances	ETV	Improved
8	26	Female	Lateral ventricular neurocytoma with foraminal obstruction	Headache, vomiting, altered sensorium	Endoscopic septostomy with biopsy of tumor	Improved
9	16	Female	TBMH	Grade IV	ETV	Died on 10 <sup>th</sup> postoperative day
10	30	Male	Shunt malfunction in idiopathic aqueduct stenosis	Difficulty in walking, memory disturbances	ETV	Improved
11	45	Male	Multiple intraparenchymal and posterior third ventricular NCC with hydrocephalus	Headache, vomiting	ETV	Improved
12	6	Male	Medulloblastoma (vermian) with hydrocephalus	Difficulty in walking, visual loss, headache, vomiting	ETV	Improved, definitive surgery done
13	16	Female	TBMH	Grade* III	ETV	Improved
14	19	Male	TBMH	Grade* III	ETV	Improved
15	7	Male	TBMH	Grade* III	ETV	Improved
16	30	Female	FUC of TBMH with right foraminal stenosis	Headache, vomiting	Endoscopic septostomy	Improved
17	34	Female	FUC of TBMH with right foraminal stenosis with shunt malfunction	Headache, vomiting	Endoscopic septostomy	Improved
18	7	Female	TBMH	Grade* III	ETV	Improved
19	41	Male	Left cerebellar Infarct with hydrocephalus		ETV	Died on 7 <sup>th</sup> postoperative day
20	16	Male	TBMH	Grade* IV	ETV	Failed, VP shunt done after 2 weeks
21	30	Male	TBMH	Grade* IV	ETV	Failed, VP shunt done after 2 weeks
22	32	Male	TBMH	Grade* III	ETV	Improved
23	65	Male	TBMH	Grade* III	ETV	Improved
24	15	Male	TBMH	Grade* III	ETV	Improved

Contd...

**Table 1: Contd...**

Case number	Age	Sex	Diagnosis	Clinical status	Surgical procedure	Result and further treatment
25	20	Male	NCC hydrocephalus	Headache, vomiting, difficulty in walking	ETV	Improved
26	35	Female	Postpyogenic meningitis hydrocephalus	Headache, vomiting	ETV	Improved
27	1	Female	Shunt malfunction in congenital aqueduct stenosis	Vomiting, enlargement of head size	ETV	Improved
28	14	Female	NCC hydrocephalus	Headache, vomiting	ETV	Improved
29	15	Male	TBMH	Grade* III	ETV	Improved
30	10	Male	Brain stem SOL with hydrocephalus	Difficulty in swallowing and walking, headache, walking	ETV	Improved
31	22	Female	TBMH	Grade* III	ETV	Improved
32	43	Male	TBMH	Grade* III	ETV	Improved

\*Grade: Palur *et al.* grading system of TBMH. SOL – Space-occupying lesions; VP – Ventriculoperitoneal; FUC – Follow-up case; TBMH – Tubercular meningitis hydrocephalus; NCC – Neurocysticercosis; ETV – Endoscopic third ventriculostomy

**Table 2: Patients’ distribution as per their diagnoses**

Diagnosis	Number of patients (n=32)
TBMH	19
LCIH	1
NCC	4
Postpyogenic meningitis	1
Aqueduct stenosis	3
Tumor	4

TBMH – Tubercular meningitis hydrocephalus; LCIH – Left cerebellar infarct with hydrocephalus, NCC – Neurocysticercosis

shown that majority of our population (80%–85%) depend on free health-care facilities provided by the public sector hospitals.<sup>[8-10]</sup> There are some excellent state of the art centers, which match best centers of the world regarding facilities, but these are far and few. Private sector health-care facilities have grown to a great extent, but only about 15% of population can afford the cost of the treatments at these centers.<sup>[10]</sup> There are reports which reveal that <20% of population are covered under any health-care insurance scheme.<sup>[10,19]</sup> Over the past two decades, advancements in techniques and technologies in neurosurgery have changed the outlook of treatments and results of neurological diseases, but unfortunately, these are quite expensive and available at only few public sector hospitals or institutes.<sup>[5,6]</sup> If we see the neurosurgical services in particular, approximately ninety government medical colleges have functional neurosurgical departments. Out of these ninety, only about 15 government medical colleges/institutes have facilities for advanced neurosurgical procedures.<sup>[5]</sup> Neuroendoscopic surgeries for more than 80% of population, therefore, are being done at 15 centers only. There are sufficient studies to suggest that neuroendoscopy is an effective, less invasive, and safer treatment modality for some of the intraventricular

lesions and superior to VP shunts for selected cases of hydrocephalus.<sup>[17,20-22]</sup> Authors feel that obstructive hydrocephalus due to tumor, adult-onset AS, NCC, shunt malfunction, and selected cases of TBMH should be treated by ETV or septostomy due to overall 40% lifetime complication rates of VP shunts. Innovations in the field of technologies and equipment are failing the test of financial challenges, which is being faced by most of the developing countries due to poor budgetary allocation, deficiency in health-care infrastructure, and human resource.<sup>[8-10,19,23,24]</sup> Need of the hour is maximal utilization of the available resources at public sector hospitals/institutes and low-cost innovations which may be made available at maximum centers. Tertiary care public sector hospitals having advanced neurosurgical facilities are overloaded with the patients and cannot match the demand due to limitations in infrastructure and human resource. Large number of patients who fail to get admissions for their treatments at these centers are left untreated or inadequately treated at poorly equipped public sector hospitals because of inability to afford cost of well-equipped private sector hospitals.

Intraventricular neuroendoscopy needs a working sheath which is either handheld by the surgeon and the assistant or is fixed by an endoscope holder. Working sheath is either single channel or multiple channel tube of diameter around 6.5 mm. We used a 7 mm outer diameter working sheath for neuroendoscopic surgeries, which could accommodate telescope of 4 mm diameter, 5-F angiographic, and 3-F Fogarty catheters. For ETVs, Fogarty catheter alone was sufficient most of the time, and whenever third ventricular floor could not be perforated bluntly by Fogarty tip, tip of cut-length of 5-F angiographic catheter was used for perforation of the floor. Dilatation of the stoma was done with the help of Fogarty balloon. For biopsy of

intraventricular lesions or removal of cystic lesions, angiographic catheter was used for suction of the tumor tissue or cyst wall.

There are many conferences and workshops organized every year, and neuroendoscopic surgical training is given to the young neurosurgeons in these meetings. There are fellowship positions available at various centers which train neuroendoscopic surgeries to young neurosurgeons. Overall, there are plenty of opportunities for learning neuroendoscopic surgeries, and most of the young neurosurgeons are trained in basic neuroendoscopic techniques.<sup>[5]</sup> However, authors feel that unavailability of equipment at public sector hospitals is an important limitation. Endoscopic surgeries in other disciplines such as general surgery, gynecology, urology, otolaryngology, and gastrointestinal surgery are routine nowadays, and most of the public sector hospitals have equipment for endoscopic surgeries in the aforementioned disciplines. Fortunately, light source, camera, and monitors are no different than what is used for neuroendoscopy. Angiographic catheters and Fogarty catheters too are used in other disciplines. Eighteen centimeter long telescope (4 mm Ø) is usually available in the otolaryngology department for endonasal diagnostic or surgical procedures. There is a need to utilize these available resources judiciously at public sector hospitals, and if cost-effective working sheath can be made available, neuroendoscopic surgeries may be offered at most of the public sector hospitals. Currently, we are creating an army of neurosurgeons trained in neuroendoscopy without ammunitions, i.e., equipment. We utilized equipment of “awake intubation system” of the department of neuroanesthesia in addition to indigenously designed working sheath and a rigid telescope provided by an otolaryngologist. Senior author uses same telescope for endoscope-assisted surgeries of the brain and spine for various other conditions also. Major disadvantage of using side working channels for instruments is inability to use rigid instruments, which are more convenient and sturdy, but these can be used with currently available telescopes with angled shaft which usually is available with straight main working channel.<sup>[21]</sup> Advancements such as ultrasonic aspirators,<sup>[25]</sup> laser,<sup>[26]</sup> neuronavigation,<sup>[27]</sup> cautery,<sup>[28]</sup> rigid or flexible scissors, and forceps<sup>[21]</sup> expand the armamentarium of the surgical procedures which can be done endoscopically in addition to enhancing safety, but there is plenty of simple procedures such as ETVs, septostomies, removals of cysts, and biopsy of solid lesions, which can safely be contemplated with the help of minimum equipment and instruments as done in our study. Uniform availability of advanced equipment is desirable, but in view of the current status of public health-care system and budgetary allocation by the central and state governments, it does not seem feasible in the near future.<sup>[9,19]</sup>

Continuous irrigation of Ringer’s lactate solution keeps the intraventricular endoscopic vision clear by removing the

minimal blood and also creates space to work as ventricles remain dilated.<sup>[17]</sup> Slightly raised intraventricular pressure also helps in hemostasis. These can be accomplished only when working sheath and all its channels are watertight. Soft rubber gasket at surgeon’s end of the telescope and use of side working channels by angiographic or Fogarty catheters through the hole in the rubber diaphragm of the LLC make the working channel watertight, which facilitates neuroendoscopic procedures.

Results of surgeries in our study were consistent with our previous reports and available literature.<sup>[1-4,11,13,14,17]</sup> Hydrocephalus caused by NCC is associated with a greater likelihood of shunt failure.<sup>[29]</sup> Endoscopic treatment in such cases helps in avoiding shunt revisions and prevents the effects of recurring hydrocephalus.<sup>[29]</sup> Mortality and failures of ETV in poor clinical grade TBMH patients are reported and occur due to other factors such as basal arteritis, ischemia, and infarction of the brain, which may not be evident on CT.<sup>[30,31]</sup> Similarly, mortality in embolic cerebellar infarction has been reported in the range of 7%–32%.<sup>[32,33]</sup> Removals of vascular solid lesions are not ideal for neuroendoscopic surgeries and should not be attempted too.<sup>[17,21]</sup> Selection of cases is an important factor when resources are scarce. Basic neurosurgical principles were followed, and neuroendoscopic techniques were no different than what we have mentioned in our earlier reports.<sup>[11-17]</sup> Management of complications or definitive surgery by microneurosurgical or endoscope-assisted surgical techniques should be undertaken whenever required. Four patients in our study were subjected to definitive surgeries for their intraventricular and paraventricular space-occupying lesions. The purpose of the current report is not to propose the design of the working sheath as the working sheath used in the study is the basic and simple design required for neuroendoscopy, incorporating principles of minimal invasion. It is important to highlight that sustained cost-effective innovation by the neurosurgeons may help majority of neurosurgical patients, because “easy-to-operate lesions” are much more common than “difficult-to-operate lesions,” which genuinely need high-end equipment and facilities.

## Conclusion

Neuroscientists should find ways to utilize the available resources at public sector health-care institutions to their maximum. There is a growing need for cost-effective innovations without compromising surgical principles and safety of the patients and interdisciplinary coordination for maximal utilization of available facilities in public sector health-care institutions. Larger number of public health-care institutions should carry out advanced neurosurgical services by aforementioned ways till health-care infrastructure improves to the desired level.

## Financial support and sponsorship

Nil.

## Conflicts of interest

There are no conflicts of interest.

## References

- Cinalli G, Sainte-Rose C, Chumas P, Zerah M, Brunelle F, Lot G, *et al.* Failure of third ventriculostomy in the treatment of aqueductal stenosis in children. *J Neurosurg* 1999;90:448-54.
- Grant JA, McLone DG. Third ventriculostomy: A review. *Surg Neurol* 1997;47:210-2.
- Jones RF, Kwok BC, Steining WA, Vonau M. The current status of endoscopic third ventriculostomy in the management of non-communicating hydrocephalus. *Minim Invasive Neurosurg* 1994;37:28-36.
- Jones RF, Teo C, Steining WA, Kwok BC. Neuroendoscopic third ventriculostomy. In: Manwaring KH, Crone KR, editors. *Neuroendoscopy*. Vol. 1. Larchmont: Mary Ann Liebert Publishers; 1992. p. 63-77.
- Ganapathy K. Neurosurgery in India: An overview. *World Neurosurg* 2013;79:621-8.
- Nadkarni TD, Goel A, Pandya SK. Neurosurgery in India. *J Postgrad Med* 2002;48:332-5.
- Rural Health Statistics in India 2012. Statistics Division, Ministry of Health and Family Welfare, Government of India. Available from: <http://www.mohfw.nic.in/WriteReadData/1892s/492794502RHS%202012.pdf>. [Last cited on 2016 May 13].
- Rao GM, Choudhary M. Health Care Financing Reforms in India. Available from: [http://www.nipfp.org.in/media/medialibrary/2013/04/wp\\_2012\\_100.pdf](http://www.nipfp.org.in/media/medialibrary/2013/04/wp_2012_100.pdf). [Last cited on 2016 May 13].
- Reddy KS, Patel V, Jha P, Paul VK, Kumar AK, Dandona L. Towards Achievement of Universal Health Care in India by 2020: A Call to Action. Published Online; 11 January, 2011. Available from: [http://www.thelancet.com/pdfs/journals/lancet/PIIS0140-6736\(10\)61960-5.pdf](http://www.thelancet.com/pdfs/journals/lancet/PIIS0140-6736(10)61960-5.pdf). [Last cited on 2016 May 13].
- Gudwani A, Mitra P, Puri A, Vaidya M. India Healthcare: Inspiring Possibilities, Challenging Journey. Prepared for Confederation of Indian Industry (CII); December, 2012. Available from: [http://www.mckinsey.com/~media/mckinsey%20offices/india/pdfs/india\\_healthcare\\_inspiring\\_possibilities\\_and\\_challenging\\_journey\\_executive\\_summary.ashx](http://www.mckinsey.com/~media/mckinsey%20offices/india/pdfs/india_healthcare_inspiring_possibilities_and_challenging_journey_executive_summary.ashx). [Last cited on 2016 May 13].
- Jha DK, Mishra V, Choudhary A, Khatri P, Tiwari R, Sural A, *et al.* Factors affecting the outcome of neuroendoscopy in patients with tuberculous meningitis hydrocephalus: A preliminary study. *Surg Neurol* 2007;68:35-41.
- Jha D, Khatri P, Choudhary A, Sethi R, Kumar S. Endoscopic third ventriculostomy (ETV) in prepontine-suprasellar tuberculoma with tuberculous meningitis hydrocephalus (TBMH): A case report. *Pediatr Neurosurg* 2007;43:42-6.
- Husain M, Jha DK, Rastogi M, Husain N, Gupta RK. Neuro-endoscopic management of intraventricular neurocysticercosis (NCC). *Acta Neurochir (Wien)* 2007;149:341-6.
- Husain M, Jha DK, Rastogi M, Husain N, Gupta RK. Role of neuroendoscopy in the management of patients with tuberculous meningitis hydrocephalus. *Neurosurg Rev* 2005;28:278-83.
- Husain M, Jha DK, Rastogi M. Angiographic catheter: Unique tool for neuroendoscopic surgery. *Surg Neurol* 2005;64:546-9.
- Husain M, Jha D, Thaman D, Husain N, Gupta RK. Ventriculostomy in a tumor involving the third ventricular floor. *Neurosurg Rev* 2004;27:70-2.
- Husain M, Jha D, Vatsal DK, Thaman D, Gupta A, Husain N, *et al.* Neuro-endoscopic surgery – experience and outcome analysis of 102 consecutive procedures in a busy neurosurgical centre of India. *Acta Neurochir (Wien)* 2003;145:369-75.
- Handler MH, Abbott R, Lee M. A near-fatal complication of endoscopic third ventriculostomy: Case report. *Neurosurgery* 1994;35:525-7.
- Devadasan N, Nair A, Nandraj S, Seshadri T, Bhojani U, Prashanth NS. Towards Universal Health Coverage: An Operational Manual for States in India. Bangalore: IPH UHC Team, Institute of Public Health; 2012.
- Gaab MR, Schroeder HW. Endoscopic approach to lesions of the foramen of Monro. *Zentralbl Neurochir Suppl* 1995;56:42.
- Gaab MR, Schroeder HW. Neuroendoscopic approach to intraventricular lesions. *J Neurosurg* 1998;88:496-505.
- Hopf NJ, Grunert P, Fries G, Resch KD, Perneczky A. Endoscopic third ventriculostomy: Outcome analysis of 100 consecutive procedures. *Neurosurgery* 1999;44:795-804.
- El Khamlichi A. African neurosurgery: Current situation, priorities, and needs. *Neurosurgery* 2001;48:1344-7.
- Peabody J, Rahman O, Gertler P, Mann J, Farley DO, Luck J, *et al.* Policy and Health: Implications for Development in Asia. New York: Cambridge University Press; 1999.
- Oka K, Go Y, Yamamoto M, Kumate S, Tomonaga M. Experience with an ultrasonic aspirator in neuroendoscopy. *Minim Invasive Neurosurg* 1999;42:32-4.
- Vandertop WP, Verdaasdonk RM, van Swol CF. Laser-assisted neuroendoscopy using a neodymium-yttrium aluminum garnet or diode contact laser with pretreated fiber tips. *J Neurosurg* 1998;88:82-92.
- Martínez-Moreno M, Widhalm G, Mert A, Kiesel B, Bukaty A, Furtner J, *et al.* A novel protocol of continuous navigation guidance for endoscopic third ventriculostomy. *Neurosurgery* 2014;10 Suppl 4:514-23.
- Hellwig D, Haag R, Bartel V, Riegel T, Eggers F, Becker R, *et al.* Application of new electrosurgical devices and probes in endoscopic neurosurgery. *Neurol Res* 1999;21:67-72.
- Kelley R, Duong DH, Locke GE. Characteristics of ventricular shunt malfunctions among patients with neurocysticercosis. *Neurosurgery* 2002;50:757-61.
- Misra UK, Kalita J, Roy AK, Mandal SK, Srivastava M. Role of clinical, radiological, and neurophysiological changes in predicting the outcome of tuberculous meningitis: A multivariable analysis. *J Neurol Neurosurg Psychiatry* 2000;68:300-3.
- Palur R, Rajshekhar V, Chandy MJ, Joseph T, Abraham J. Shunt surgery for hydrocephalus in tuberculous meningitis: A long-term follow-up study. *J Neurosurg* 1991;74:64-9.
- Jauss M, Krieger D, Hornig C, Schramm J, Busse O. Surgical and medical management of patients with massive cerebellar infarctions: Results of the German-Austrian Cerebellar Infarction Study. *J Neurol* 1999;246:257-64.
- Venti M. Cerebellar infarcts and hemorrhages. *Front Neurol Neurosci* 2012;30:171-5.