

Management of Postoperative Discitis: A Review of 31 Patients

Abstract

Background: The aim of the study was to retrospectively evaluate the outcome of medical management of postoperative discitis (POD). **Materials and Methods:** A total of 31 patients treated for POD were included in the study. Clinical, radiological, and laboratory data of all patients were collected and evaluated. All patients were treated initially with bed rest and antibiotic therapy after radiological diagnosis. Surgical management was undertaken after failure of 4 weeks of conservative management. All cases were followed clinically with laboratory and radiological investigations. **Results:** Five cases failed to respond to medical management and were treated surgically with debridement and transpedicular fixation. All patients showed clinical recovery till the last follow-up. **Conclusion:** Early diagnosis and proper management are the keys to successful outcome of postoperative spondylodiscitis. Surgical debridement and fusion are required when conservative treatment fails.

Keywords: Discitis, spinal infections, spine surgery, vertebral osteomyelitis

Introduction

Discitis is defined as the inflammation of vertebral plates due to infective cause. Postoperative discitis (POD) can occur after lumbar discectomy. It comprises superficial and deep infections and was first described as a clinical entity by Turnbull in 1953.^[1] It may be localized to disc space or disseminate under the fascia and include discitis, epidural abscess, and spondylitis. Infection of the disc space may often present with severe back pain, muscle spasm, and fever. The symptom may be viewed as a consequence of an insufficient operation or recurring disc herniation. There are no hematological or biochemical findings that are clearly diagnostic of this condition. Radiological findings may show evidence of infection along with reduction in disc space and end space blurring/resorption.

Staphylococcus is the most common etiological agent of pyogenic discitis; followed by aerobic Gram-negative bacilli. Other rare cases were fungal: *Clostridium perfringens*, *Haemophilus* species, and *Aspergillus fumigatus*.

Prompt diagnosis, identification of the causal agent, and specific antibiotic treatment are the key to the successful outcome. Surgical treatment, if required should be taken at earliest to reduce

morbidity. We evaluated the outcome of conservative treatment of POD.

Materials and Methods

We conducted a retrospective, cross-sectional, observational study, in which 31 patients of POD who attended our center from October 2010 to July 2015 were included, out of 854 patients in whom discectomy was performed. Consent of patients and their relatives were taken along with Institutional Approval for publication of their data. All attempts are made to keep the identity of patients undisclosed. Symptoms at presentation included severe back pain after 2–3 weeks of lumbar disc surgery sometimes associated with pyrexia. All patients had positive straight leg raising test, tenderness of the back, and restricted movements on examination. In all cases, the diagnosis was confirmed by magnetic resonance imaging (MRI).

Empirical antibiotic treatment (vancomycin/cefepime/linezolid + amikacin + metronidazole) was started immediately, and the patient was put on complete bed rest. All patients were followed by serial blood investigations, including complete blood count, erythrocyte sedimentation rate (ESR), and C-reactive protein (CRP).

The conservative treatment was evaluated by clinical and laboratory parameters at 4 weeks,

Deepak Kumar Singh,
Neha Singh¹,
Praveen Kumar Das²,
Deepak Malviya²

Departments of Neurosurgery and ²Anesthesiology,
Dr. Ram Manohar Lohia
Institute of Medical Sciences,
¹Departement of Radiodiagnosis
and Imaging, King George's
Medical University, Lucknow,
Uttar Pradesh, India

Address for correspondence:

Dr. Deepak Kumar Singh,
Department of Neurosurgery,
Dr. Ram Manohar Lohia
Institute of Medical Sciences,
Lucknow - 226 010,
Uttar Pradesh, India.
E-mail: gkp.deepak@gmail.com

Access this article online

Website: www.asianjns.org

DOI: 10.4103/ajns.AJNS_233_16

Quick Response Code:



How to cite this article: Singh DK, Singh N, Das PK, Malviya D. Management of postoperative discitis: A review of 31 patients. Asian J Neurosurg 2018;13:703-6.

This is an open access journal, and articles are distributed under the terms of the Creative Commons Attribution-NonCommercial-ShareAlike 4.0 License, which allows others to remix, tweak, and build upon the work non-commercially, as long as appropriate credit is given and the new creations are licensed under the identical terms.

For reprints contact: reprints@medknow.com

and patients with improved symptoms and laboratory investigations continued to be managed conservatively. Surgical treatment was taken up in nonresponders in terms of debridement and posterior fixation.

All patients were followed up at 1 and 3 months and 1 year. Patient characteristics, comorbidities, and laboratory investigations were summarized in Tables 1 and 2.

Results

Sites of involvement

All patients have single-disc involvement that corresponds with the level of surgery. L4/5 level was involved in 20 patients whereas L5/S1 level was involved in 11 patients.

Comorbid disease

Seven patients were morbidly obese (body mass index >35) whereas three patients were uncontrolled diabetic. Surgery was undertaken only after normalizing blood sugar level in all three patients.

Clinical presentation

Severe back pain the initial presentation in all 31 patients. Five patients presented with fever higher than 100°F.

Microbiology findings

Biopsy was taken in only five patients who did not respond to medical management. All biopsies were taken during open surgery. *Staphylococcus aureus* was identified as causative organism in only two patients. The urinary culture was positive for candida in one patient. Blood culture was negative in all 31 patients.

Medical management

Antibiotic therapy was given intravenously (IV) in all case. Pain is treated with analgesics, and patients learn to

move as little as possible, but a brace can be prescribed to enforce this. The activity of parts of the body not affected, such as arm exercises is done to prevent generalized weakness. The prolonged treatment course and the considerable pain and immobility can lead to situational depression that should be treated if present.

The duration of IV antibiotic therapy was 6 weeks in responders, additional 3 weeks of IV antibiotic treatment was given in patients taken up for surgical debridement and fixation. A combination of three antibiotics was initially used in all patients. The most common antibiotics used were vancomycin/cefepime/linezolid along with amikacin and metronidazole. Antibiotic treatment was tailored in two culture positive patients after surgical debridement. Antifungal treatment (fluconazole 150 mg PO for 3 weeks) was added in one urine culture positive patient. Six weeks of oral antibiotic treatment (linezolid 600 mg OD + ciprofloxacin 500 mg BID) were given in all patients at the time of discharge.

Operative management

Surgical treatment was undertaken in five patients (16.1%) who did not respond to medical management. Open surgical debridement and transpedicular fixation were done in all five patients [Figure 1].

Patient outcomes

All 31 patients were symptom-free at 6 months follow-up. Radiological fusion was achieved in 27 patients till the last follow-up.

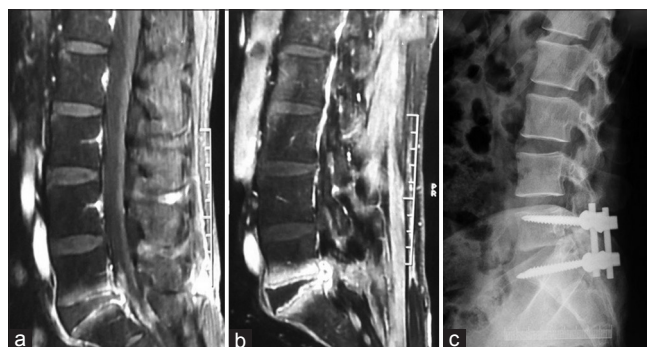


Figure 1: Gadolinium-enhanced T1-weighted fat suppressed the sagittal image of a follow-up case of L5-S1 discectomy showing (a) reduced L5-S1 intervertebral disc space with end plate irregularity and postcontrast enhancement. Mild enhancement also noted in overlying anterior and posterior epidural space. (b) After 6 weeks of intravenous antibiotic administration, follow-up scan demonstrated increase in the end plate and epidural contrast enhancement and marginal irregularity. Involvement of paraspinal soft tissue also noted. Decompression and L5-S1 transpedicular (c) fixation was done after 6 weeks of failed conservative treatment

Table 1: Patient characteristics

Patient characteristics	Number of Patients
Sex	
Male	22
Female	9
Level of Primary Surgery	
L4/5	20 (2 Microscopic+18 Open)
L5/S1	11 (3 Microscopic+8 Open)
Co-morbidity	
Obesity	7
Diabetes mellitus	3

Table 2: Laboratory investigations

ESR (normal range 2-25mm/h)	Number of patients	CRP (normal range 0-10ng/l)	Number of patients	TLC (normal range 4000-10000)	Number of patients
<25	1	<10	0	<10000	2
25-100	26	10-100	30	10000-18000	27
>100	4	>100	1	>18000	2

Discussion

Infections following spine surgery can be prevented to a great extent using universal precautions. These general preventive measures include the adoption of aseptic techniques, optimization of patients before surgery, proper use of preoperative antibiotics, and good postoperative follow-up.^[2,3] All aseptic precautions were taken at our center, and we discourage the change and movement of persons in the operating room. Blood transfusion is discouraged unless very necessary, only one patient out of these 31 was transfused with two units of packed red blood cells. We routinely prescribe IV antibiotics for 24 h along with preoperative IV bolus at the time of incision. We prescribe 3 days of oral antibiotics in routine manner and keep a high index of suspicion in every case.

Discitis result in significant increase in morbidity. A high index of suspicion is necessary in every patient presenting with back pain after spinal surgery. The incidence of discitis varies from 0.21% to 3.6% as per existing literature,^[4] however, in the present study, it was little higher side (3.6%). It is controversial whether discitis can be caused by an aseptic or infectious process as positive cultures maybe obtained only in 42%–73% of patients.^[5,6] The majority of surgeons are of the opinion that it results from direct inoculation of an offending pathogen into the avascular disc space. Injury to the end plate, hematoma collection, and necrotic tissue caused by surgery provide early culture conditions for bacterial growth.^[7]

Devices such as an operating microscope or headlamp can create a source of bacterial shedding onto the surgical field although increased contamination from these devices has not been shown to directly increase the infection risk.^[8,9] There is also limited evidence that minimally invasive surgery may decrease the risk of the risk of POD.^[10] Our series supports that as there are only five cases (16.1%) of discitis resulting of microdiscectomy [Table 1].

The study by Koutsoumbelis *et al.*^[11] identified four procedure-related risk factors: (1) longer duration of surgery; (2) intraoperative blood loss/need for transfusion; (3) incidental durotomy; and (4) >10 people in the operation theater (OT), specifically cautioning against unnecessary nurses. The previous studies have also identified increased operative time, multilevel surgery, revision surgery, and an increased number of people in the OT as important predisposing factors for postoperative spinal infections.^[12] The period between surgeries and onset of symptoms was typically 14–24 days. Clinical presentation in all our cases was similar to the existing literature. The typical symptoms in our cases were severe back pain, spasm, and fever. Typically, the pain and muscle spasm were resistant to bed rest and analgesics.

Early diagnosis is crucial in the management of discitis because delayed treatment can lead up to undesired medical and psychosocial effects. The use of a well-defined

methodical approach would help in establishing a conclusive diagnosis. This would be based on a comprehensive history, thorough physical examination, detailed laboratory studies and imaging studies, preferably MRI. Persistent elevated ESR and CRP together with typical findings in MRI suggests discitis. CRP typically declines by around 10 days postoperatively; hence, any patient with unexpected rise in CRP beyond 2 weeks after surgery should be evaluated for POD. Some studies indicate that CRP is the most sensitive indicator of POD.^[13,14]

All 31 patients in our study had increased CRP, 93% had increased white blood cell count, and 97% showed increased ESR that supported the previous studies.

MRI is the most superior diagnostic method.^[15] It constantly highlighted the disc fluid sign (hyperintensities in T2-weighted sequences), irregularities of vertebral end plates, edematous changes in adjacent vertebral bodies, and irregular contrast uptake in inflammatory tissue, paravertebral, and psoas muscles.^[16] Florid inflammatory signs with granulation tissue were identified on MRI in all of our cases as previously reported. Plain radiography may show reduction of the operated disc space and disc arthrosis changes. The follow-up of the disease progression and response to treatment was evaluated by repeated MRI examinations.

A wide range of organisms has been associated with POD, but it primarily remains a monobacterial infection. *Staphylococcus* remains the predominant primary pathogen in various studies.^[17,18] It remains only identified pathogen in our study also. We do not rely on computed tomography-guided aspiration and cultures because of poor yield and possibility of aseptic and chemical meningitis.^[19]

We rely on prophylactic antibiotic therapy after diagnostic confirmation following MRI. Cultures are taken in medically resistant cases that required open debridement and fixation.

Prophylactic antibiotic treatment must include broad spectrum IV antibiotics with known efficacy to *Staphylococcus* and other commonly found microorganisms (*Staphylococcus epidermidis* and β -hemolytic streptococci, *Escherichia coli*, *Pseudomonas aeruginosa*, *Klebsiella pneumoniae*, *Propionibacterium acnes*, and diphtheroids). Vancomycin along with amikacin and metronidazole is the preferred antibiotic treatment for prophylactic use though many authors used cefepime and linezolid with equal success. Duration of parenteral antibiotic administration varies considerably in literature.^[20-22] In a multicenter, observational, prospective study, the mean treatment duration was 14.7 weeks with minimum length ranging from 6 to 12 weeks according to the treatment center. Our protocol was 6 weeks of parenteral IV therapy followed by 6 weeks of oral antibiotic therapy in all medically managed cases. An additional 3 weeks of parenteral IV therapy was given in patients undergoing surgery.

In our series, complete bed rest is advocated in all medically managed cases though some studies prefer external immobilization in Boston corset. There is no evidence claiming superiority of one over other.

We prefer surgical debridement and fixation using transpedicular screws and rods in all medically resistant cases. Although some authors successfully advocate the use of closed suction irrigation device along with the primary debridement in acute cases,^[23,24] we did not use it. Fixation is advocated as instability cannot be assessed properly in these patients because of severe pain and muscle spasm.^[25,26] Studies have shown that instrumentation after radical debridement will not increase the rate of recurrent infection,^[26] rather it immediately stabilizes the affected segment and promotes accelerated healing. All patients had significant pain relief in the immediate postoperative period and became ambulatory second postoperative day.

Conclusion

A high index of suspicion should be kept in any patient presenting with unexplained backache after surgery. Diagnosis can be immediately made based on physical examination and radiological findings. Early diagnosis is the key as appropriate management is the key to the successful outcome.

Acknowledgment

The authors wish to disclose that no funding, either institutional or external was received for this study.

Financial support and sponsorship

Nil.

Conflicts of interest

There are no conflicts of interest.

References

- Turnbull F. Postoperative inflammatory disease of lumbar discs. *J Neurosurg* 1953;10:469-73.
- Sponseller PD, LaPorte DM, Hungerford MW, Eck K, Bridwell KH, Lenke LG. Deep wound infections after neuromuscular scoliosis surgery: A multicenter study of risk factors and treatment outcomes. *Spine (Phila Pa 1976)* 2000;25:2461-6.
- Barker FG 2nd. Efficacy of prophylactic antibiotic therapy in spinal surgery: A meta-analysis. *Neurosurgery* 2002;51:391-400.
- El-Gindi S, Aref S, Salama M, Andrew J. Infection of intervertebral discs after operation. *J Bone Joint Surg Br* 1976;58:114-6.
- Sharma SK, Jones JO, Zeballos PP, Irwin SA, Martin TW. The prevention of discitis during discography. *Spine J* 2009;9:936-43.
- Onik G. Automated percutaneous biopsy in the diagnosis and treatment of infectious discitis. *Neurosurg Clin N Am* 1996;7:145-50.
- Pull ter Gunne AF, Mohamed AS, Skolasky RL, van Laarhoven CJ, Cohen DB. The presentation, incidence, etiology, and treatment of surgical site infections after spinal surgery. *Spine (Phila Pa 1976)* 2010;35:1323-8.
- Weiner BK, Kilgore WB. Bacterial shedding in common spine surgical procedures: Headlamp/loupes and the operative microscope. *Spine (Phila Pa 1976)* 2007;32:918-20.
- Bible JE, O'Neill KR, Crosby CG, Schoenecker JG, McGirt MJ, Devin CJ. Microscope sterility during spine surgery. *Spine (Phila Pa 1976)* 2012;37:623-7.
- Wilson DH, Harbaugh R. Microsurgical and standard removal of the protruded lumbar disc: A comparative study. *Neurosurgery* 1981;8:422-7.
- Koutsoumbelis S, Hughes AP, Girardi FP, Cammisa FP Jr, Finerty EA, Nguyen JT, *et al.* Risk factors for postoperative infection following posterior lumbar instrumented arthrodesis. *J Bone Joint Surg Am* 2011;93:1627-33.
- Chahoud J, Kanafani Z, Kanj SS. Surgical site infections following spine surgery: Eliminating the controversies in the diagnosis. *Front Med (Lausanne)* 2014;1:7.
- Meyer B, Schaller K, Rohde V, Hassler W. The C-reactive protein for detection of early infections after lumbar microdiscectomy. *Acta Neurochir (Wien)* 1995;136:145-50.
- Kang BU, Lee SH, Ahn Y, Choi WC, Choi YG. Surgical site infection in spinal surgery: Detection and management based on serial C-reactive protein measurements. *J Neurosurg Spine* 2010;13:158-64.
- Van Goethem JW, Parizel PM, van den Hauwe L, Van de Kelft E, Verlooy J, De Schepper AM. The value of MRI in the diagnosis of postoperative spondylodiscitis. *Neuroradiology* 2000;42:580-5.
- Frank AM, Trappe AE. The role of magnetic resonance imaging (MRI) in the diagnosis of spondylodiscitis. *Neurosurg Rev* 1990;13:279-83.
- Sapkas GS, Mavrogenis AF, Mastrokalos DS, Papadopoulos E, Papagelopoulos EC, Papagelopoulos PJ. Postoperative spine infection: A retrospective analysis of 21 patients. *Eur J Orthop Surg Traumatol* 2006;16:322-6.
- Hopkinson N, Stevenson J, Benjamin S. A case ascertainment study of septic discitis: Clinical, microbiological and radiological features. *QJM* 2001;94:465-70.
- Fouquet B, Goupille P, Jattiot F, Cotty P, Lapierre F, Valat JP, *et al.* Discitis after lumbar disc surgery. Features of "aseptic" and "septic" forms. *Spine (Phila Pa 1976)* 1992;17:356-8.
- Thibodeau AA. Closed space infection following removal of lumbar intervertebral disc. *J Bone Joint Surg Am* 1968;50:400-10.
- Piotrowski WP, Krombholz MA, Mühl B. Spondylodiscitis after lumbar disk surgery. *Neurosurg Rev* 1994;17:189-93.
- Silber JS, Anderson DG, Vaccaro AR, Anderson PA, McCormick P, NASS. Management of postprocedural discitis. *Spine J* 2002;2:279-87.
- Rohmiller MT, Akbaria BA, Raiszadeh K, Raiszadeh K, Canale S. Closed suction irrigation for the treatment of postoperative wound infections following posterior spinal fusion and instrumentation. *Spine (Phila Pa 1976)* 2010;35:642-6.
- Ido K, Shimizu K, Nakayama Y, Shikata J, Matsushita M, Nakamura T. Suction/irrigation for deep wound infection after spinal instrumentation: A case study. *Eur Spine J* 1996;5:345-9.
- Przybylski GJ, Sharan AD. Single-stage autogenous bone grafting and internal fixation in the surgical management of pyogenic discitis and vertebral osteomyelitis. *J Neurosurg* 2001;94 1 Suppl:1-7.
- Rayes M, Colen CB, Bahgat DA, Higashida T, Guthikonda M, Rengachary S, *et al.* Safety of instrumentation in patients with spinal infection. *J Neurosurg Spine* 2010;12:647-59.