

Malignant Conversion to Glioblastoma in Neurofibromatosis Type I-associated Pleomorphic Xanthoastrocytoma: Unknown Predictors of Favorable Outcome

Abstract

Pleomorphic xanthoastrocytoma (PXA) is a benign glial tumor, the association of which with neurofibromatosis type I (NF-1) has been often reported in the literature. Although malignant conversion to glioblastoma may be seen in 5%–10% of PXA, the same has been reported only once in the presence of NF-1. We report, so far known to be only the second such case all over. A 25-year-old male, a known case of NF-1, underwent frontal craniotomy for a superficially located right frontal lesion, histology of which suggested PXA. Two years later, the lesion recurred and the subsequent surgery revealed malignant conversion to glioblastoma. After adjuvant radiotherapy, the patient now continues to do well and is free of disease after another 3 years of follow-up. We believe that if low levels of neurofibromin are seen in such cases with malignant conversion, subsequently increased neurofibromin levels may be responsible for better overall survival in these patients.

Keywords: Anaplastic, glioblastoma, malignant, neurofibroma, pleomorphic xanthoastrocytoma

Introduction

Neurofibromatosis type I (NF-1) is a genetic disorder with complete penetrance that occurs with frequency 1 in 2000 to 1 in 8000.^[1] Associated intracranial gliomas are common, with optic nerve astrocytoma being most common. Pleomorphic xanthoastrocytoma (PXA), first introduced in 1979, has been rarely reported in NF-1. Although spontaneous regression of PXA in NF-1 is a known entity, malignant conversion to glioblastoma has been described only once.^[2] Neurofibromin acts as a tumor suppressor gene, and low levels are seen in secondary glioblastoma. We present a patient of such rare association who is asymptomatic at 3-year follow-up since malignant conversion. We believe that neurofibromin level may fluctuate, if low levels are seen in malignant conversion, subsequently increased levels may be responsible for better overall survival in these patients. NF-1-associated tumors have a better prognosis than solitary ones; the same may be attributed to the tumor suppressor activity of neurofibromin.

Case Report

A 25-year-old male with multiple swellings all over the body since childhood

presented with history of headache of 1-year duration. On examination, multiple neurofibromas were evident. Imaging revealed a peripherally placed right frontal lesion that was hyperdense on computed tomography (CT); on magnetic resonance imaging (MRI), the lesion was hypointense on T1-weighted (T1W), hyperintense on T2-weighted (T2W), and enhanced homogeneously on gadolinium [Figure 1]. Right frontal craniotomy was performed intraoperatively; a superficially located unencapsulated lesion involving the leptomeninges with a well-defined plane of cleavage was seen. Histopathology suggested PXA with interlacing fascicles of spindle cells and occasional giant cells. On immunohistochemistry, the tumor cells were positive for glial fibrillary acidic protein, Ki-67 proliferation was 2% [Figure 2]. Histology of subcutaneous nodule was suggestive of neurofibroma. Postoperative course was uneventful. Since there were no atypical cells, high cellularity, or necrosis, radiotherapy was not administered. The patient remained asymptomatic for next 2 years and then presented again with complaint of headache for 15 days. Repeat MRI revealed a recurrent lesion with heterogeneous enhancement, necrosis,

Navneet Singla,
Ankur Kapoor¹,
B.D. Radotra²,
Debajyoti
Chatterjee²

Departments of Neurosurgery and ²Histopathology, PGIMER Chandigarh, ¹Stavya Spine Hospital and Research Institute, Ahmedabad, Gujarat, India

Address for correspondence:

Dr. Ankur Kapoor,
Flat No. E-33, GHS-94,
Sector - 20, Panchkula,
Haryana - 134 116, India.
E-mail: dr.ankurkapoor@gmail.com

Access this article online

Website: www.asianjns.org

DOI: 10.4103/ajns.AJNS_274_16

Quick Response Code:



How to cite this article: Singla N, Kapoor A, Radotra BD, Chatterjee D. Malignant conversion to glioblastoma in neurofibromatosis type I-associated pleomorphic xanthoastrocytoma: Unknown predictors of favorable outcome. *Asian J Neurosurg* 2018;13:826-9.

This is an open access journal, and articles are distributed under the terms of the Creative Commons Attribution-NonCommercial-ShareAlike 4.0 License, which allows others to remix, tweak, and build upon the work non-commercially, as long as appropriate credit is given and the new creations are licensed under the identical terms.

For reprints contact: reprints@medknow.com

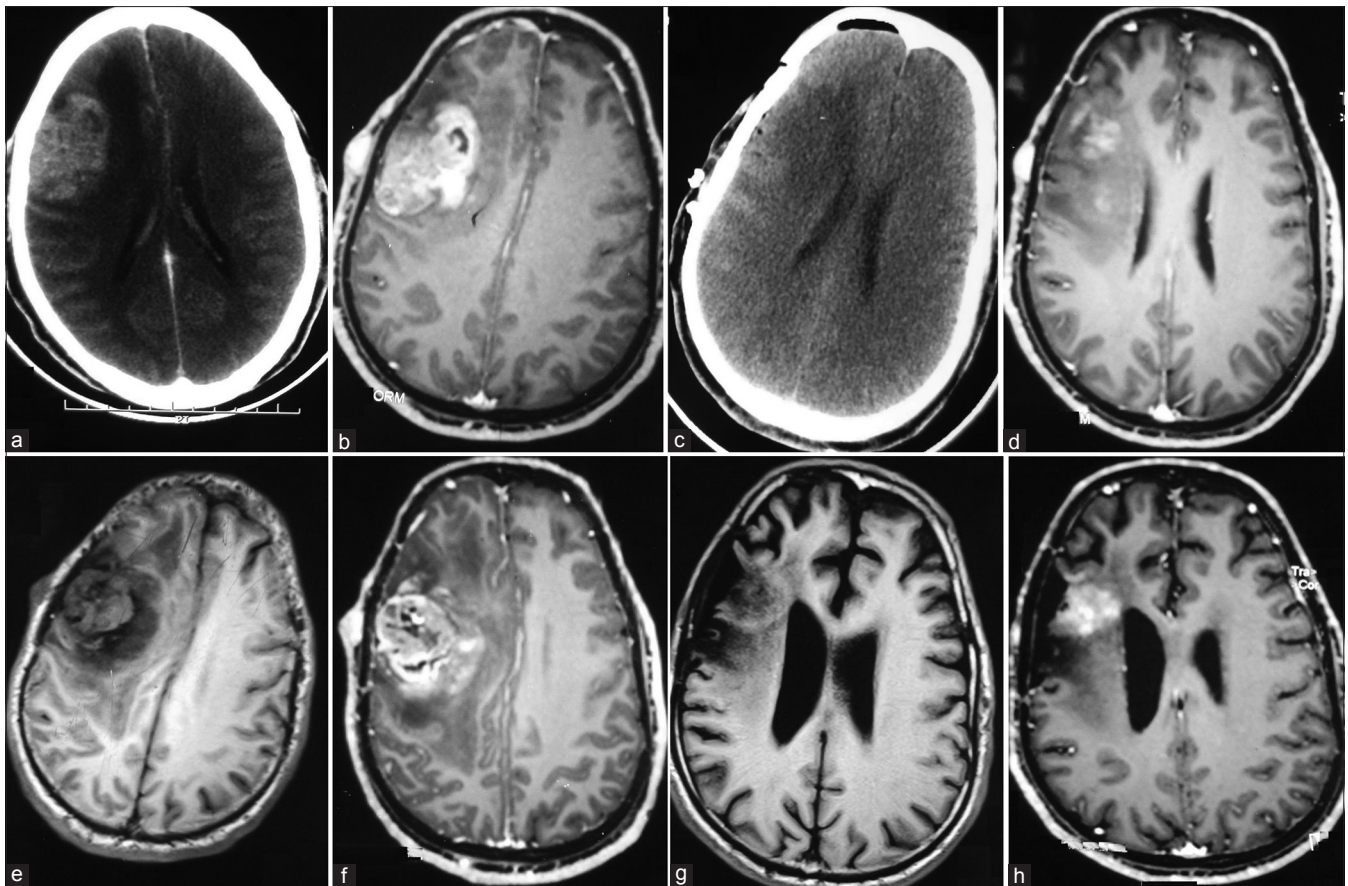


Figure 1: Preoperative axial noncontrast computed tomography head and axial magnetic resonance imaging T1-weighted contrast image showing right frontal peripherally located, well-circumscribed lesion hyperdense on computed tomography and dense contrast enhancing on magnetic resonance (a and b). Postoperative noncontrast computed tomography head (c) showing total excision. At 1-year follow-up axial magnetic resonance imaging (d) showing gliosis. At recurrence, the lesion had focal necrosis and surrounding edema on T1-weighted contrast (e and f). Imaging at 3-year follow-up showing minimal area of enhancement at previous operated site and no evidence of edema (g and h)

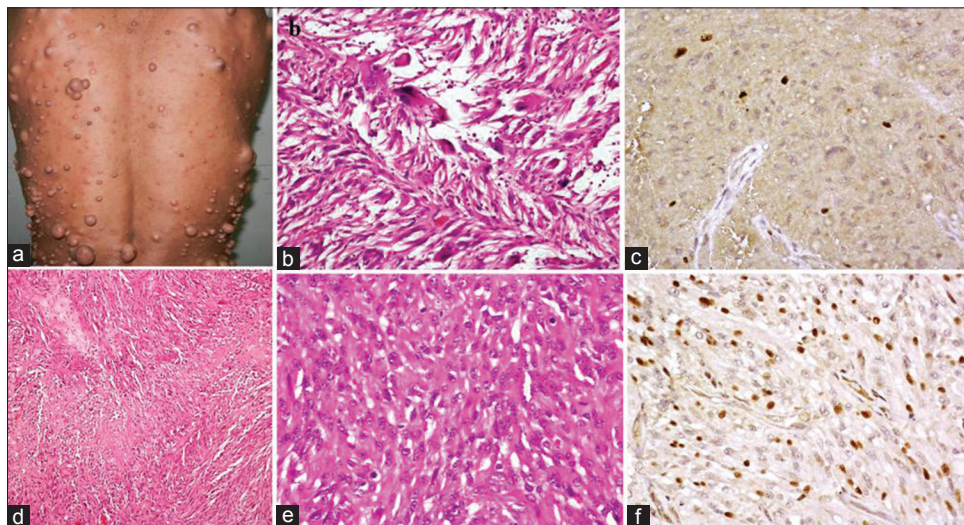


Figure 2: Multiple subcutaneous neurofibromas (a). Photomicrograph of primary lesion showing cellular tumor with oval to spindle-shaped cells admixed with few pleomorphic, multinucleated giant cells (H and E, $\times 200$) (b). Ki-67 immunostain shows a low proliferative index (immunoperoxidase, $\times 400$) (c). At recurrence, the tumor was highly cellular with areas of necrosis (H and E, $\times 100$) (d). Moderate nuclear pleomorphism with frequent mitotic activity (H and E, $\times 200$) can be seen (e). Ki-67 immunostain shows a high proliferative index (immunoperoxidase, $\times 400$) (f)

and edema. Craniotomy this time revealed an infiltrating vascular lesion with evidence of necrosis intraoperatively.

Histology turned out to be glioblastoma with palisading cells, necrosis, and nuclear pleomorphism. Giant cells

were occasionally seen and mitoses were 8–10 per high-power field. Adjuvant focal radiotherapy (60 Gy) was administered. At 3-year follow-up, the patient continues to remain asymptomatic while repeat MR did not show any recurrence.

A proper informed consent was obtained from the patient.

Discussion

NF-1 is a known genetic disorder that is characterized by café-au-lait spots, subcutaneous neurofibromas, lisch nodules of the iris and bone. It is an autosomal dominant disorder with complete penetrance.^[1] Although common associated intracranial tumors are pilocytic astrocytomas of the optic nerve, occasionally PXA has been reported.

PXA, first described in 1979, is a benign tumor of glial origin that commonly affects children and young adults.^[1,3] Although usually seen in superficial temporal and parietal lobes, other sites as cerebellum, thalamus, sella, and spinal cord have been rarely reported.^[2,4] It presents as a cortical or deep hemispheric lesion that is solid or cystic with a mural nodule and has dural attachment.^[4,5] Histologically, it is characterized by spindle-shaped cells with elongated nuclei, intracytoplasmic lipid vacuoles, and multinucleated giant cells. Intracellular eosinophilic granular bodies may be seen occasionally, but mitoses are scarce or absent and so is necrosis.^[5] The cell of origin is believed to be subpial astrocyte with prominent basement membrane, as was seen in our patient.

The association of PXA with NF-1 was first reported in 1993. About 10%–20% of patients with PXA may have malignant conversion to high-grade glioma over a period ranging from 7 months to 15 years.^[4] By virtue of high cellularity, mitoses, and necrosis, the histology of atypical PXA simulates that of glioblastoma. Differentiation between atypical PXA and glioblastoma is apparent by the presence of pericellular reticulin staining and absence of vascular hyperplasia and nuclear palisading in the former. Current consensus favors secondary glioblastoma arising from PXA when necrosis, pseudopalisading and endothelial proliferation, is accompanied by loss of reticulin staining.^[6,7] Radiologically inner table of the skull may seem eroded on plain film, CT shows solid part of tumor hyper or isodense, MRI shows hypo- or iso-intense signal on T1W and hyperintense on T2W, while gadolinium shows variable contrast enhancement. Calcifications have been rarely reported. Our patient had a superficially located frontal lesion that enhanced avidly on contrast.

PXA is a benign tumor, and surgical excision is sufficient with no added benefit from adjuvant radiotherapy or chemotherapy. Overall survival is good and mortality is not affected by radiotherapy while recurrence is rare when radiotherapy is administered following surgery.^[6] Although few believe that, with poor overall survival of 1 year in malignant degeneration in PXA, aggressive

surgical resection may not be warranted if it causes additional deficits,^[3,6] we believe that gross total resection, when achieved, with adjuvant radiotherapy gives optimum result. Prognosis in secondary glioblastoma depends on proliferative potential of tumor cells rather than primary lesion from which it arises. We support hereby, the earlier stated hypothesis that NF-1 acts as a good prognosticator in the patient of PXA regardless of malignant conversion. The malignant conversion in our patient in 2 years' time and then favorable outcome after 3 years is intriguing.

Although spontaneous involution of NF-1-associated tumors is a known entity, the malignant progression is rarely reported.^[8-10] Regression of such tumors is due to neurofibromin gene product, which due to its structural and functional homology to GTPase acts as a tumor suppressor. Malignant lesions in NF-1 have low neurofibromin levels.^[9] We believe that similar low levels of neurofibromin in our patient would have led to malignant conversion. Subsequently, tumor suppressor effect as a result of increase in neurofibromin has now prevented any further neurological deterioration 3 years later. We believe that regular follow-up of such patients is essential due to unpredictable biological behavior.

The limitation of our study is that it is based on single patient.

Financial support and sponsorship

Nil.

Conflicts of interest

There are no conflicts of interest.

References

1. Adeleye AO, Okolo CA, Akang EE, Adesina AM. Cerebral pleomorphic xanthoastrocytoma associated with NF1: An updated review with a rare atypical case from Africa. *Neurosurg Rev* 2012;35:313-9.
2. Yokoo H, Kamiya M, Sasaki A, Hirato J, Nakazato Y, Kurachi H. Neurofibromatosis type 1-associated unusual pleomorphic astrocytoma displaying continual malignant progression. *Pathol Int* 2001;51:570-7.
3. Ohta S, Ryu H, Miura K. Eighteen-year survival of a patient with malignant pleomorphic xanthoastrocytoma associated with von Recklinghausen neurofibromatosis. *Br J Neurosurg* 1999;13:420-2.
4. Saikali S, Le Strat A, Heckly A, Stock N, Scarabin JM, Hamlat A. Multicentric pleomorphic xanthoastrocytoma in a patient with neurofibromatosis type 1. Case report and review of the literature. *J Neurosurg* 2005;102:376-81.
5. Bucciero A, De Caro M, De Stefano V, Tedeschi E, Monticelli A, Siciliano A, *et al.* Pleomorphic xanthoastrocytoma: Clinical, imaging and pathological features of four cases. *Clin Neurol Neurosurg* 1997;99:40-5.
6. Macaulay RJ, Jay V, Hoffman HJ, Becker LE. Increased mitotic activity as a negative prognostic indicator in pleomorphic xanthoastrocytoma. Case report. *J Neurosurg* 1993;79:761-8.
7. Weldon-Linne CM, Victor TA, Groothuis DR, Vick NA.

- Pleomorphic xanthoastrocytoma. Ultrastructural and immunohistochemical study of a case with a rapidly fatal outcome following surgery. *Cancer* 1983;52:2055-63.
8. Parazzini C, Triulzi F, Bianchini E, Agnetti V, Conti M, Zanolini C, *et al.* Spontaneous involution of optic pathway lesions in neurofibromatosis type 1: Serial contrast MR evaluation. *AJNR Am J Neuroradiol* 1995;16:1711-8.
 9. Leisti EL, Pyhtinen J, Poyhonen M. Spontaneous decrease of a pilocytic astrocytoma in neurofibromatosis type 1. *AJNR Am J Neuroradiol* 1996;17:1691-4.
 10. Gottschalk S, Tavakolian R, Buske A, Tinschert S, Lehmann R. Spontaneous remission of chiasmatic/hypothalamic masses in neurofibromatosis type 1: Report of two cases. *Neuroradiology* 1999;41:199-201.