

Effect of Local N-acetyl-cysteine in the Prevention of Epidural Fibrosis in Rat Laminectomy Model

Abstract

Background: Epidural fibrosis is a major contributing factor to the onset of failed back syndrome. Many studies have attempted to prevent this physiological response. Interestingly, N-acetyl-cysteine (NAC) has been effective in some cases in the treatment of pulmonary fibrosis. **Objective:** The objective of this study was to determine whether local NAC is an effective way to prevent epidural fibrosis after laminectomy in rats. **Materials and Methods:** Twenty Wistar rats were used in this study. Animals were divided into two groups: NAC group and a control group. We performed two-level laminectomy (L4–L5) in these rats. Rats in the control group just had laminectomy, and in the other group, L4 and L5 laminectomy followed by local treatment with NAC. Four weeks later, the rats were killed, and the laminectomy level was subjected to histopathological examination to evaluate epidural fibrosis and fibroblast density. **Results:** Histopathological examination showed that after 4 weeks of surgery the NAC group had significantly less epidural fibrosis and fibroblasts compared with control group. **Conclusion:** Our findings indicate that NAC decreased spinal epidural fibrosis after laminectomy in rats.

Keywords: Epidural fibrosis, failed back syndrome, fibroblast, laminectomy, N-acetyl cysteine, rat

Introduction

Intervertebral disc degeneration is a physiological process that develops with normal aging. In symptomatic cases with disc herniation with no response to medical treatment or after exacerbation of symptoms, patients are candidates for surgery.^[1] Laminectomy is a type of surgery where part of the vertebral lamina is removed for decompression of the spinal cord. This surgery can lead to the development of failed back syndrome (FBS), a clinical syndrome in which patients complain of pain in the back and lower extremities after one or more surgeries.^[2]

Epidural fibrosis is the main cause of this syndrome, which in previous studies developed in 5%–25% of laminectomy surgeries.^[3] In fact, progressive epidural fibrosis creates an adherence of the dura mater and nerve roots to intervertebral disc and vertebral body in the anterior part and to the erector muscles of the spinal column in the posterior part. The formation of this scar compresses and limits the movement of nerve roots, which causes FBS.^[4] In these cases, reoperation generally proves to be

ineffective and could cause more surgical complications.^[5] Currently, there is no effective treatment of epidural fibrosis, and prophylaxis is a recommended alternative.^[6]

In the recent years, a number of investigations have been carried out in two ways to decrease the formation of epidural fibrosis. One group used barrier-like free-fat graft, silastic sheeting, polytetrafluoroethylene membrane, gelatin sponge, animal collagen, and omental graft.^[3,7,8] Other groups used various drugs such as steroids, anti-inflammatory agents, and hyaluronan, but we still have no effective prophylactic strategy for preventing epidural fibrosis.^[9–13]

N-acetyl-cysteine (NAC) is a modulator of many genes with inhibitory activity against C-jun N-terminal kinase, P38 map kinase, redox-sensitive activator protein-1, and nuclear factor kappa B transcription factor activity. In addition, this compound, which inhibits apoptosis and increases cell lifetime with activation of extracellular signal-regulated kinase pathways, is effective in the treatment of inflammation, fibrosis, endothelial dysfunction, cartilage erosion, and acetaminophen toxicity.^[14] The

Reza Bahrami,
Ehsan Akbari,
Salih Rasras,
Nematollah
Jazayeri¹,
Mohammad Javad
Khodayar²,
Hossein
Forouzandeh³,
Masoud Zeinali,
Mozhdeh Mohmedi
Kartalaei⁴,
Mohammad
Ardeshiri,
Farshid Baiatinia,
Mohamad
Ghanavatian

Departments of Neurosurgery,
¹Pathology, ²Pharmacology and
Toxicology, School of Pharmacy
and ⁴Cardiology, Golestan
Hospital, Ahvaz Jundishapur
University of Medical Sciences,
Ahvaz, ³Gerash Cellular and
Molecular Research Center,
Gerash University of Medical
Sciences, Gerash, Iran

Address for correspondence:

Dr. Ehsan Akbari,
Department of Neurosurgery,
Jundishapur Ahvaz University
of Medical Sciences, Golestan
Street, Ahvaz, Khuzestan, Iran.
E-mail: Ehsan_akbari60@
yahoo.com

Access this article online

Website: www.asianjns.org

DOI: 10.4103/ajns.AJNS_294_16

Quick Response Code:



How to cite this article: Bahrami R, Akbari E, Rasras S, Jazayeri N, Khodayar MJ, Forouzandeh H, et al. Effect of local N-acetyl-cysteine in the prevention of epidural fibrosis in rat laminectomy model. Asian J Neurosurg 2018;13:664-8.

This is an open access journal, and articles are distributed under the terms of the Creative Commons Attribution-NonCommercial-ShareAlike 4.0 License, which allows others to remix, tweak, and build upon the work non-commercially, as long as appropriate credit is given and the new creations are licensed under the identical terms.

For reprints contact: reprints@medknow.com

effect of high-dose NAC in idiopathic pulmonary fibrosis has been described by many researchers.^[15,16]

Aim

The aim of our study was to examine the effect of NAC on postlaminectomy epidural fibrosis in rats.

Materials and Methods

Animals

Male Wistar rats (220–250 g and 12 months of age) were obtained from the animal house of Ahvaz Jundishapur University of Medical Sciences, Iran. The animals were kept under controlled conditions of $25 \pm 2^\circ\text{C}$ and a 12-h light-dark cycle and had free access to food and water. All experimental protocols were based on the Ahvaz Medical University Ethics Protocols on animal experiments.

Chemicals

All chemicals used in this study were of analytical grade and obtained through commercial sources. NAC was purchased from Roche (Germany).

Study design

In this study, we used twenty Wistar rats. The animals were randomly divided into two groups. Anesthesia was induced with 30 mg/kg ketamine hydrochloride and 5 mg/kg xylazine hydrochloride given intraperitoneally. The rats were given an intramuscular injection of 20 mg/kg cephazoline. The lumbosacral skin was shaved and the surgical field was sterilized with povidone-iodine. A dorsal median skin incision was made with number-15 blade on the spinous process in the lumbosacral area. The paraspinal muscles were dissected away from the two sides of the spinous process and lamina. Microscopic bilateral laminectomy at L4–L5 was performed with a rongeur. Epidural fat and ligamentum flavum were cleaned away and the underlying dura mater was exposed. We did not use bipolar cautery, bone wax, or other hemostatic material, and hemostasis was maintained by irrigation with 0.9% sodium chloride. Close attention was paid not to damage the dura mater and nerve roots. At this time, the procedure was the same in all rats. In the control group after laminectomy, we irrigated the dura mater with 10 ml of 0.9% sodium chloride, and the field was closed in anatomic layers with 4-0 vicryl suture. In the other group, laminectomy was followed by applying a cotton pad soaked with 5 mg/kg NAC in saline to the exposed dura mater. After 5 min, the cotton was removed and the field was irrigated with 10 ml of saline; the wound was then closed like in the control group.

Rats were sacrificed 4 weeks later with an overdose of intraperitoneal sodium thiopental (100 mg/kg). There was no infection of the surgical field in the rats. The lumbar spine including the surgical site was resected *en bloc* and then fixed in 10% formic acid.

Histological examination

Four micron-thick sections of tissue were obtained with a microtome and stained with H and E. All sections were examined by a pathologist who was blinded to the rats' treatment. In the histopathological evaluation, we checked for epidural fibrosis and determined fibroblast density. Data were analyzed with SPSS Version 16, (IBM) for Windows. The differences between two groups (epidural fibrosis and fibroblast density) were evaluated by Mann–Whitney U-test. $P < 0.05$ was considered statistically significant.

Epidural fibrosis grades based on the definition of He *et al.* are as follows:

- Grade 0: The dura mater is free of scar tissue
- Grade 1: Only thin fibrous bands are observed between the scar tissue and dura mater
- Grade 2: Continuous adherence is observed in less than two-thirds of the laminectomy defect [Figures 1 and 2]
- Grade 3: Scar tissue adherence is large, affecting more than two-third of the laminectomy defect or adherence extends to the nerve roots.

Fibroblast density (quantity of fibroblasts) in the scar tissue: The cells in three different areas (two borders and center of the laminectomy defect) were counted and mean was calculated. Fibroblast density was graded as follows:

- Grade 1: Less than 100 fibroblasts per $\times 400$ field
- Grade 2: 100–150 fibroblasts per $\times 400$ field
- Grade 3: More than 150 fibroblasts per $\times 400$ field [Figures 3 and 4].

Statistical analysis

Statistical analysis was carried out using SPSS for Windows. The differences between two groups were evaluated by Mann–Whitney U-test. $P < 0.05$ was deemed statistically significant.

Results

There was no dura mater or nerve root injury and neurological deficit and postoperative infection according

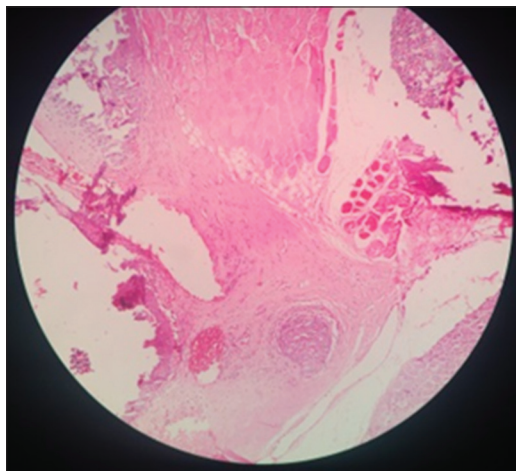


Figure 1: Dura mater free of adherence

to the histological findings. Epidural fibrosis was less prominent in the NAC group compared to control group ($P < 0.05$). In the NAC group, two rats had Grade 1, six rats had Grade 2, and two rats had Grade 3. In the control group, three rats had Grade 2 and seven rats had Grade 3 [Figures 5 and 6]. Fibroblast density was lower in the NAC group compared to control group ($P < 0.05$). In the NAC group, six rats had Grade 1 and four rats had Grade 2. In the control group, one rat had Grade 1, six rats had Grade 2, and 3 rats had Grade 3.

Discussion

Epidural fibrosis is a well-known cause of complications after spinal laminectomy surgery such as for degenerative disc disease. Many studies have investigated the efficacy of other compounds for prevention of epidural fibrosis.^[17] In a similar study, Ozkan *et al.* investigated the effects of 5-fluorouracil (5-FU) and bevacizumab (BV), alone and combined, on epidural fibrosis in rat laminectomy. Twenty-eight rats were divided into four groups; a control group, a BV group, a 5-FU group, and a BV + 5-FU group. L1-2 laminectomies were performed on the rats, and drug

treatment was by topical administration. After 6 weeks, the rats were sacrificed and histological sections prepared from the spines were examined and graded by a pathologist. Their findings indicated that the combination of 5-FU and BV was more effective in reducing epidural fibrosis after laminectomy in rats.^[18]

In another study, Savran *et al.* investigated the prevention of epidural fibrosis in rats by local or systemic administration of citicoline. Their findings demonstrated that postoperative administration of citicoline caused less epidural fibrosis, dural adhesion, fibroblast density, foreign body reaction, and medulla spinalis retraction.^[19]

In the present study, we used topical NAC in a rat laminectomy model and made comparisons with the control group. Our histological findings showed that epidural fibrosis was less prominent in the NAC group compared to control group ($P < 0.05$). In the NAC group, two rats had Grade 1, six rats had Grade 2, and two rats had Grade 3. In the control group, three rats had Grade 2 and seven rats had Grade 3 [Figures 5 and 6]. Fibroblast density was lower in the NAC group compared to control group ($P < 0.05$).

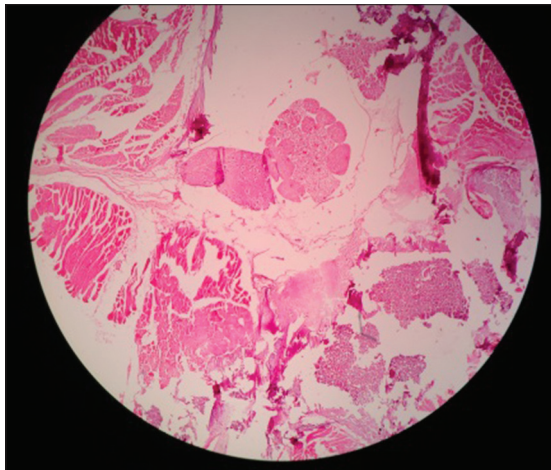


Figure 2: Adhesion between dura mater and fibrosis

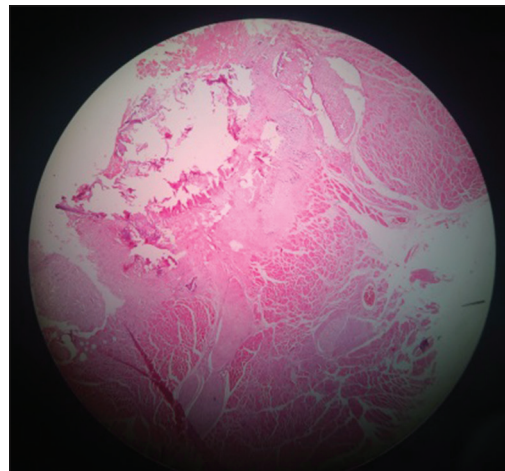


Figure 3: Low fibroblast density

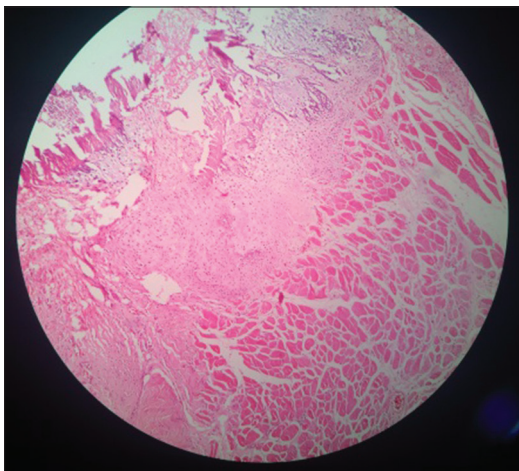


Figure 4: High fibroblast density

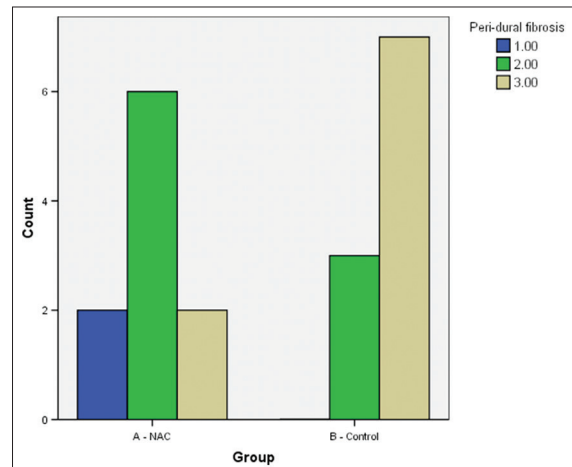


Figure 5: Epidural fibrosis in N-acetyl-cysteine group and control group

In the NAC group, six rats had Grade 1 and four rats had Grade 2. In the control group, one rat had Grade 1, six rats had Grade 2, and three rats had Grade 3 [Figures 7 and 8].

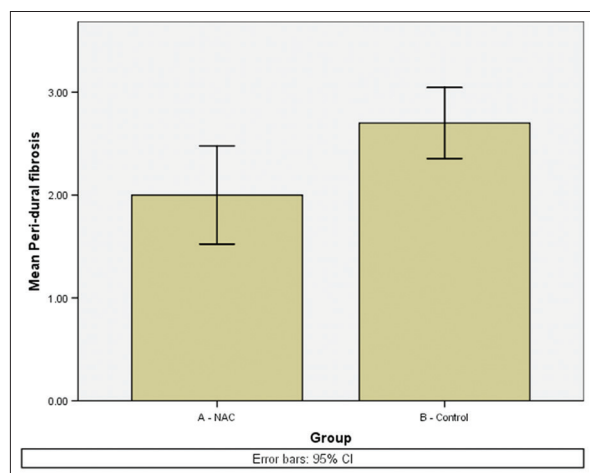


Figure 6: Box plot for epidural fibrosis (significantly lower in N-acetyl-cysteine group)

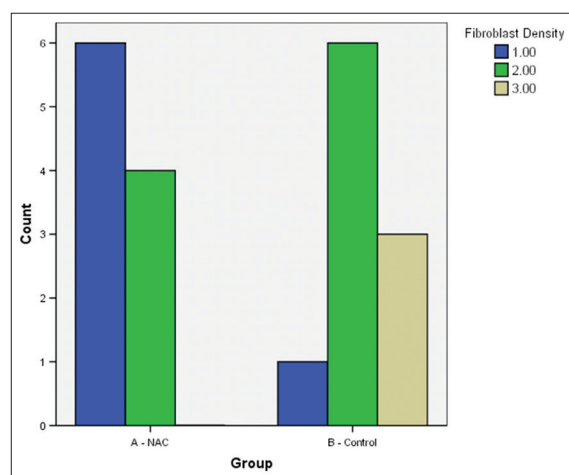


Figure 7: Fibroblast density in N-acetyl-cysteine group and control group

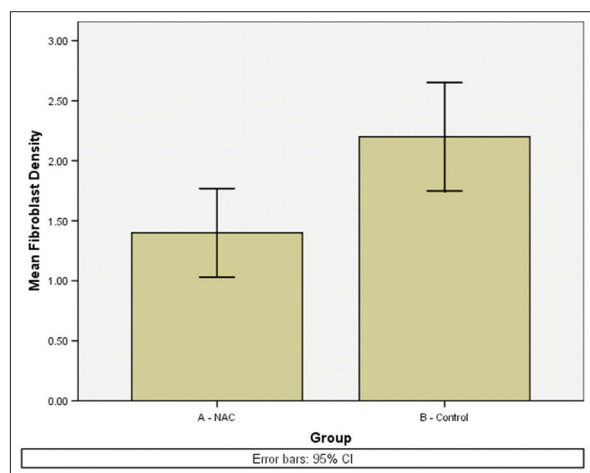


Figure 8: Box plot for fibroblast density (significantly lower in N-acetyl-cysteine group)

Conclusion

This study showed that the use of local NAC can reduce epidural fibrosis and fibroblast density in rat laminectomy, but we need further experimental studies to support these findings.

Acknowledgment

This article is part of resident research project of The degree of specialization neurosurgery confirmed by Deputy of Research of Ahvaz Jundishapur University of Medical Sciences and conducted by financial support of this university; now, hereby, we would like to express our gratitude and appreciation to this deputy and also our special thanks goes to members of the Golestan Hospital Clinical Research Development Unit.

Financial support and sponsorship

This study was financially supported by Ahvaz Jundishapur University of Medical Sciences.

Conflicts of interest

There are no conflicts of interest.

References

- Rasner MK, Campbell VA. Treatment of thoracic disk herniation. In: Winn HR, editor. Youmans Neurological Surgery. 6th ed. Philadelphia: Elsevier Saunders; 2011. p. 2919-22.
- Samy Abdou M, Hardy RW Jr. Epidural fibrosis and the failed back surgery syndrome: History and physical findings. *Neurol Res* 1999;21 Suppl 1:S5-8.
- Alkalay RN, Kim DH, Urry DW, Xu J, Parker TM, Glazer PA. Prevention of postlaminectomy epidural fibrosis using bioelastic materials. *Spine (Phila Pa 1976)* 2003;28:1659-65.
- LaRocca H, Macnab I. The laminectomy membrane. Studies in its evolution, characteristics, effects and prophylaxis in dogs. *J Bone Joint Surg Br* 1974;56B:545-50.
- Cruccu G, Aziz TZ, Garcia-Larrea L, Hansson P, Jensen TS, Lefaucheur JP, *et al.* EFNS guidelines on neurostimulation therapy for neuropathic pain. *Eur J Neurol* 2007;14:952-70.
- Ceviz A, Arslan A, Ak HE, Inalöz S. The effect of urokinase in preventing the formation of epidural fibrosis and/or leptomeningeal arachnoiditis. *Surg Neurol* 1997;47:124-7.
- Rodgers KE, Robertson JT, Espinoza T, Oppelt W, Cortese S, diZerega GS, *et al.* Reduction of epidural fibrosis in lumbar surgery with Oxiplex adhesion barriers of carboxymethylcellulose and polyethylene oxide. *Spine J* 2003;3:277-83.
- Petrie JL, Ross JS. Use of ADCON-L to inhibit postoperative peridural fibrosis and related symptoms following lumbar disc surgery: A preliminary report. *Eur Spine J* 1996;5 Suppl 1:S10-7.
- Farrokhi MR, Vasei M, Fareghbal S, Farrokhi N. The effect of methylene blue on peridural fibrosis formation after laminectomy in rats: An experimental novel study. *Spine J* 2011;11:147-52.
- Kasimcan MO, Bakar B, Aktas S, Alhan A, Yilmaz M. Effectiveness of the biophysical barriers on the peridural fibrosis of a postlaminectomy rat model: An experimental research. *Injury* 2011;42:778-81.
- Kemaloglu S, Ozkan U, Yilmaz F, Nas K, Gur A, Acemoglu H, *et al.* Prevention of spinal epidural fibrosis by recombinant tissue plasminogen activator in rats. *Spinal Cord* 2003;41:427-31.

12. Adezyon DE. Comparison of the effects of an adhesion barrier and chitin on experimental epidural fibrosis. *Turk Neurosurg* 2010;20:457-63.
13. Pessaux P, Panaro F, Casnedi S, Zeca I, Marzano E, Bachellier P, *et al.* Targeted molecular therapies (cetuximab and bevacizumab) do not induce additional hepatotoxicity: Preliminary results of a case-control study. *Eur J Surg Oncol* 2010;36:575-82.
14. Zafarullah M, Li WQ, Sylvester J, Ahmad M. Molecular mechanisms of N-acetylcysteine actions. *Cell Mol Life Sci* 2003;60:6-20.
15. BJORAKER JA, RYU JH, EDWIN MK, MYERS JL, TAZELAAR HD, SCHROEDER DR, *et al.* Prognostic significance of histopathologic subsets in idiopathic pulmonary fibrosis. *Am J Respir Crit Care Med* 1998;157:199-203.
16. Flaherty KR, Travis WD, Colby TV, Toews GB, Kazerooni EA, Gross BH, *et al.* Histopathologic variability in usual and nonspecific interstitial pneumonias. *Am J Respir Crit Care Med* 2001;164:1722-7.
17. Douglas WW, Ryu JH, Swensen SJ, Offord KP, Schroeder DR, Caron GM, *et al.* Colchicine versus prednisone in the treatment of idiopathic pulmonary fibrosis. A randomized prospective study. Members of the Lung Study Group. *Am J Respir Crit Care Med* 1998;158:220-5.
18. Ozkan U, Osun A, Samancioglu A, Ercan S, Firat U, Kemaloglu S. The effect of bevacizumab and 5-Fluorouracil combination on epidural fibrosis in a rat laminectomy model. *Eur Rev Med Pharmacol Sci* 2014;18:95-100.
19. Savran M, Bekar A, Cansev M, Tolunay S, Ulus IH, Taskapilioglu MO. Prevention of epidural fibrosis in rats by local or systemic administration of citicoline. *Turk Neurosurg* 2012;22:634-40.