

Foramen Magnum Chordoid Meningioma in a 22-Year-old Female

Abstract

Chordoid meningioma is a rare variety of meningioma (0.5%–1%) with high rate of recurrence. They are grouped in WHO Grade II tumors. They are mainly distributed in the supratentorial location. There has been a single report of foramen magnum chordoid meningioma in a 3-year, 6-month-old child. Our patient, a 22-year-old female, admitted with progressive spastic quadriparesis with bowel and bladder involvement. She was operated with tumor resection done; postoperatively, patient showed dramatic improvement in the motor power as well as bowel and bladder function. Histopathology was suggestive of chordoid meningioma. She received 54 Gy of radiotherapy. She is doing well with no neurological deficits and no recurrence at 2-year follow-up.

Keywords: Chordoid meningioma, foramen magnum, WHO grade II tumours

Introduction

Meningiomas are common intracranial tumors and constitute between 13% and 20% of all primary intracranial tumors.^[1] They are the most common tumors of the foramen magnum (FM) region, most of them arise from the ventral and lateral margins of FM.^[2-6] The term chordoid meningioma was given by Kepes *et al.* in 1988 to describe a meningeal neoplasm that has chordoma-like appearance on histopathology.^[7] It was found to be associated with Castleman syndrome which is characterized by delayed sexual and somatic development, hepatosplenomegaly, iron refractory microcytic hypochromic anemia, plasmacytosis, and dysgammaglobulinemia.

Chordoid meningioma is a rare subtype which is associated with a high likelihood of recurrence.^[8,9] It represents only 0.5%–1% of all meningiomas^[8,9] and is grouped in WHO Grade II tumors.^[10] They are mainly distributed in the supratentorial region. Infratentorial chordoid meningioma is rare. There has been a single report of FM chordoid meningioma in a 3-year, 6-month-old child.^[11]

We report a case of FM chordoid meningioma in a 22-year-old female with reference to neuroimaging, surgical approach, histological appearance, and her neurological improvement after

total surgical resection of the tumor, demonstrated by postoperative magnetic resonance imaging (MRI). To the best of our knowledge, this is the first such case in this age group.

Presentation

A 22-year-old female presented with a history of neck pain with progressive spastic quadriparesis for 1 year. She had recent worsening of her limb weakness along with bowel and bladder involvement and respiratory compromise. Preoperatively, her neurological examination revealed poor respiratory reserve, no lower cranial nerve palsy, spastic quadriplegia, and she was catheterized for urinary retention. MRI done was suggestive of large ill-defined extra-axial altered signal intensity lesion in the premedullary region compressing and displacing medulla and cervicomedullary junction with subtle signal alteration [Figure 1a and b]. All other routine investigations were normal.

Surgery

The lesion was approached from a posterolateral aspect by a right-sided suboccipital craniectomy and C1, C2 hemilaminectomy in lateral position [Figure 1c]. The tumor was decompressed preserving the neural and vascular structures. Postoperatively, she was gradually weaned off the ventilator and had to undergo a tracheostomy. She made

**Abhishek Kumar,
S. Bhaskar,
Minakshi Bhardwaj¹,
L. N. Gupta**

*Departments of Neurosurgery
and ¹Pathology, PGIMER,
Ram Manohar Lohia Hospital,
New Delhi, India*

Address for correspondence:

*Dr. Abhishek Kumar,
Department of Neurosurgery,
PGIMER, Ram Manohar
Lohia Hospital, Baba
Kharak Singh Marg,
New Delhi - 110 001, India.
E-mail: abkneuro@gmail.com*

Access this article online

Website: www.asianjns.org

DOI: 10.4103/ajns.AJNS_296_16

Quick Response Code:



How to cite this article: Kumar A, Bhaskar S, Bhardwaj M, Gupta LN. Foramen magnum chordoid meningioma in a 22-year-old female. Asian J Neurosurg 2018;13:834-7.

This is an open access journal, and articles are distributed under the terms of the Creative Commons Attribution-NonCommercial-ShareAlike 4.0 License, which allows others to remix, tweak, and build upon the work non-commercially, as long as appropriate credit is given and the new creations are licensed under the identical terms.

For reprints contact: reprints@medknow.com

an uneventful recovery and was discharged after 3 weeks. At that time, her limb power had improved to 4/5, tracheostomy was decannulated, and bladder function had recovered. At 2-year follow-up, she has no neurological deficits except for brisk reflexes in all four of her limbs and minimal posterior column dysfunction.

Histopathology examination showed cords of eosinophilic vacuolated cells in abundant myxoid matrix [Figure 1d]. Cells were immunopositive for epithelial membrane antigen (EMA) and vimentin [Figure 1e and f]. However, they were negative for glial fibrillary acidic protein (GFAP) and S100. Based on these findings, a diagnosis of chordoid meningioma was rendered.

Postoperative MRI was suggestive of an area of dural enhancement in the ventral FM region along with signal changes in the cervicomedullary junction in the spinal cord [Figure 2a and b]. Patient was planned for postoperative radiotherapy (RT) and received 54 Gy of RT. MRI done 2 years after completion of RT does not reveal any abnormal enhancement in the dura or signal changes in the spinal cord [Figure 2c and d]. At present, she is doing well with no neurological deficits and no recurrence.

Discussion

Among all the meningiomas, only 1.8%–3.2% arise at the FM level.^[12] They are the most commonly observed FM tumors, representing 70% of all benign tumors.^[2-6,12] Most of the time, these are strictly intradural. They can be intra- and extradural, and a few may be entirely extradural.^[2-6,13-17]

They can be divided into craniocervical if they arise above the FM and reach inferiorly and cervicocranial if they arise in the cervical region and reach superiorly. Craniocervical

meningiomas are generally ventral to the brainstem while cervicocranial is posterior and lateral to it.^[17-19] Patients most commonly are in the fourth through sixth decades of life, but these tumors have been reported in patients of almost every age. Although FM chordoid meningioma has been reported in a 3.5-year-old child, this tumor rarely occurs in children. The most common histologic type is meningothelial, followed by psammomatous and fibrous type of meningioma.

Our case presented with the typical characteristics of the FM lesion and showed dramatic improvement in the power after surgery.

In a review of Kepes *et al.*,^[7] a relationship with Castleman syndrome was found, the features of which are delayed somatic and sexual development, hepatosplenomegaly, iron refractory hypochromic microcytic anemia, and bone marrow plasmacytosis with dysgammaglobulinemia.

This association was not found in the majority of other studies.^[8,20-23] In our case also, no systemic symptoms were present.

In a study of 42 cases of chordoid meningioma by Couce *et al.*, the majority (88%) were large and supratentorial.^[8] No manifestation of systemic disease was there. None of the patients had a lesion at FM.

Tena-Suck *et al.* in their report of ten cases of chordoid meningioma found that 80% of the tumors were in supratentorial region.^[24] The age range was from 30 to 67 years old (mean, 34.2 years). The duration of symptoms varied from 3.5 months to 5 years (mean, 14.1 months). No systemic symptoms were noted and none of the patient had lesion at FM.

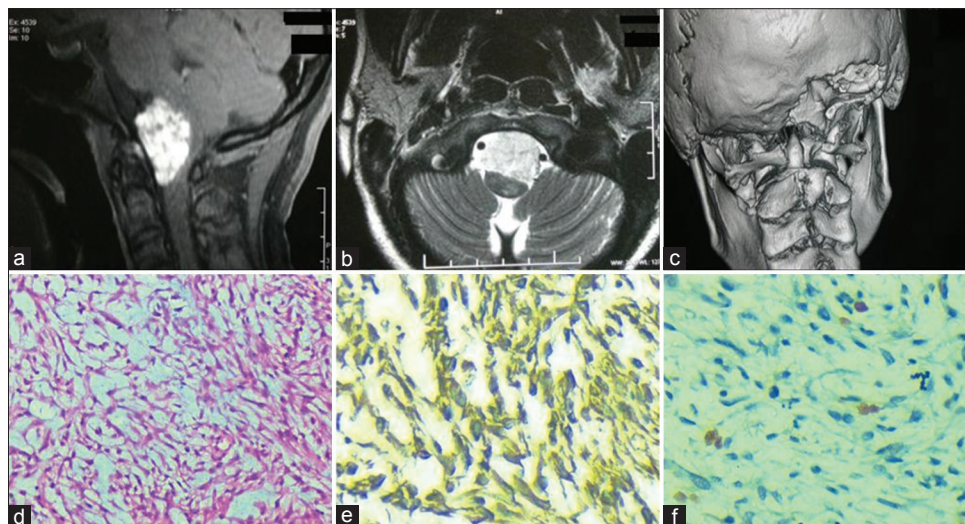


Figure 1: (a) Sagittal contrast-enhanced magnetic resonance imaging showing extra-axial enhancing mass lesion in the ventral aspect of the brainstem causing compression. (b) Axial T2-weighted image showing ventral lesion causing compression of medulla. (c) Postoperative three-dimensional reconstruction computed tomography scan showing the extent of craniectomy and right C1, C2 hemilaminectomy. (d) Tumor tissue composed of cords of eosinophilic vacuolated cells in abundant mucoid matrix (H and E, ×200). (e) Cytoplasmic and membranous positivity of vimentin (×400). (f) MiB labeling index: 4%–5% hot spot area (black arrow) (×400)

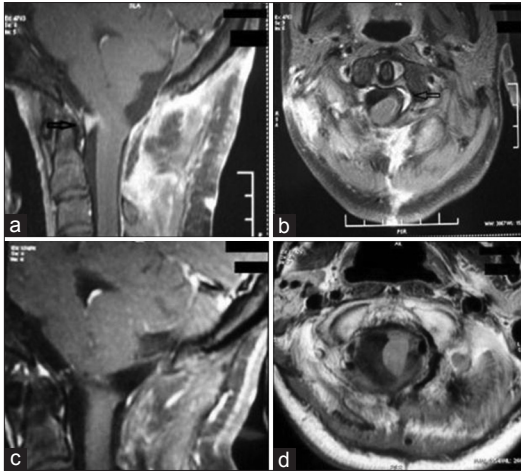


Figure 2: (a) Postoperative sagittal contrast-enhanced magnetic resonance imaging suggestive of enhancement ventral to brainstem (black arrow). (b) Postoperative axial contrast-enhanced magnetic resonance imaging suggestive of enhancement in the left side of brainstem. (c and d): 2-year postsurgery and postradiotherapy scan (sagittal and axial) showing no residual lesion or enhancement

The age range was from 12 to 67 years old (mean, 34.2 years) in the series of Epari *et al.*^[9] with majority of the lesions in supratentorial region.

Yang *et al.* in their recent series of sixty cases of chordoid meningioma have reported 33 tumors in infratentorial region (31 skull base and 2 intraventricular) and 2 in cervical region. As the exact breakup of these infratentorial lesions has not been mentioned and none of the lesions are mentioned in FM location, we assume that no lesion was present in this region.^[25]

In a case report of a 3-year, 6-month-old child with FM tumor, postoperative RT was not given as there was complete resection of the tumor;^[11] however, our patient received 54 Gy of RT.

Differential diagnosis of tumor with chordoid/myxoid features includes chordoma, chordoid glioma, myxoid chondrosarcoma, myxopapillary ependymoma, and mucinous metastatic carcinoma. A panel of immunohistochemical markers is required to differentiate between these tumors. Chordomas are EMA/cytokeratin (CK)/S-100 positive. Chordoid gliomas are GFAP positive; chondrosarcomas stain positively with S-100 while chordoid meningioma is EMA positive. Myxopapillary ependymomas are exclusively located in conus medullaris, cauda equina, and filum terminale and are GFAP positive; metastatic carcinoma shows reactivity with CK.^[26]

The recurrence rate for Grade II and chordoid meningioma has been reported to be 41.7%^[27] and 37.5%^[28] respectively. In a study by Violaris *et al.*, the majority (55.2%) of recurrences for Grade II meningioma was observed within 2 years from surgery and 94.7% within 5 years from surgery.^[27]

Patient is on close follow-up for the past 2 years and carrying out her routine life activities. There is no recurrence till now.

Informed and signed consent for enrollment and publication of patient's data was obtained from the patient.

Institutional approval and ethical clearance were obtained from the patient.

Financial support and sponsorship

Nil.

Conflicts of interest

There are no conflicts of interest.

References

- Lantos PL, Vandenberg SR, Kleihues P. Tumors of the nervous system. In: Graham DI, Lantos PL, editors. Greenfield's Neuropathology. 6th ed. London: Arnold; 1997. p. 583-879.
- George B. Meningiomas of the foramen magnum. In: Schmidek HH, editor. Meningiomas and Their Surgical Management. Philadelphia: Saunders; 1991. p. 459-70.
- George B, Dematons C, Cophignon J. Lateral approach to the anterior portion of the foramen magnum. Application to surgical removal of 14 benign tumors: Technical note. Surg Neurol 1988;29:484-90.
- George B, Lot G. Anterolateral and posterolateral approaches to the foramen magnum: Technical description and experience from 97 cases. Skull Base Surg 1995;5:9-19.
- George B, Lot G. Foramen magnum meningiomas. A review from personal experience of 37 cases and from a cooperative study of 106 cases. Neurosurg Q 1995;5:149-67.
- George B, Lot G. Surgical approaches to the foramen magnum. In: Robertson JT, Coakham HB, Robertson JH, editors. Cranial Base Surgery. New York: Churchill Livingstone; 2000. p. 259-79.
- Kepes JJ, Chen WY, Connors MH, Vogel FS. "Chordoid" meningeal tumors in young individuals with peritumoral lymphoplasmacellular infiltrates causing systemic manifestations of the castlemans syndrome. A report of seven cases. Cancer 1988;62:391-406.
- Couce ME, Aker FV, Scheithauer BW. Chordoid meningioma: A clinicopathologic study of 42 cases. Am J Surg Pathol 2000;24:899-905.
- Epari S, Sharma MC, Sarkar C, Garg A, Gupta A, Mehta VS. Chordoid meningioma, an uncommon variant of meningioma: A clinicopathologic study of 12 cases. J Neurooncol 2006;78:263-9.
- Kleihues P, Louis DN, Scheithauer BW, Rorke LB, Reifenberger G, Burger PC, *et al.* The WHO classification of tumors of the nervous system. J Neuropathol Exp Neurol 2002;61:215-25.
- Marhx-Bracho A, Rueda-Franco F, Ibarra-de la Torre A, Garcia-González O, Bornstein-Quevedo L, de León-Bogorge B. Chordoid meningioma of the foramen magnum in a child: A case report and review of the literature. Childs Nerv Syst 2008;24:623-7.
- Arnaudovic KI, Al-Mefty O, Husain M. Ventral foramen magnum meningiomas. J Neurosurg 2000;92 1 Suppl:71-80.
- Cohen L. Tumors in the region of the foramen magnum. In: Vinken PJ, Bruyn GW, editors. Handbook of Clinical Neurology. Amsterdam: North-Holland; 1975. p. 719-29.
- Ibrahim AW, Satti MB, Ibrahim EM. Extrapial meningioma. Case report. J Neurosurg 1986;64:328-30.

15. Ingraham FD. Intraspinal tumors in infancy and childhood. *Am J Surg* 1938;39:342-76.
16. Tsuji N, Nishiura I, Koyama T. Extradural multiple spinal meningioma. Literature review a case report. *Neurochirurgia (Stuttg)* 1986;29:124-7.
17. Stein BM, Leeds NE, Taveras JM, Pool JL. Meningiomas of the foramen magnum. *J Neurosurg* 1963;20:740-51.
18. George B, Lot G, Boissonnet H. Meningioma of the foramen magnum: A series of 40 cases. *Surg Neurol* 1997;47:371-9.
19. George B, Lot G, Velut S, Gelbert F, Mourier KL. Tumors of the foramen magnum. *Neurochirurgie* 1993;39:1-89.
20. Kobata H, Kondo A, Iwasaki K, Kusaka H, Ito H, Sawada S. Chordoid meningioma in a child. Case report. *J Neurosurg* 1998;88:319-23.
21. Inagawa H, Ishizawa K, Shimada S, Shimada T, Nishikawa R, Matsutani M, *et al.* Cytologic features of chordoid meningioma. A case report. *Acta Cytol* 2004;48:397-401.
22. Mullassery D, O'Brien DF, Williams D, Crooks D, Mallucci C, Pizer B, *et al.* Malignant disseminated chordoid meningioma in a 12-year-old child: A role for early cranial and spinal radiation treatment after subtotal resection. *Childs Nerv Syst* 2006;22:1344-50.
23. Salinero E, Beltran L, Costa JR. Intraoperative cytologic diagnosis of chordoid meningioma. A case report. *Acta Cytol* 2004;48:259-63.
24. Tena-Suck ML, Collado-Ortiz MA, Salinas-Lara C, García-López R, Gelista N, Rembao-Bojorquez D. Chordoid meningioma: A report of ten cases. *J Neurooncol* 2010;99:41-8.
25. Yang Y, Li D, Cao XY, Hao SY, Wang L, Wu Z, *et al.* Clinical features, treatment, and prognostic factors of chordoid meningioma: Radiological and pathological features in 60 cases of chordoid meningioma. *World Neurosurg* 2016;93:198-207.
26. Siraj F, Ansari MK, Sharma KC, Singh A. Chordoid meningioma: A diagnostic dilemma. *J Cancer Res Ther* 2015;11:663.
27. Violaris K, Katsarides V, Sakellariou P. The recurrence rate in meningiomas: Analysis of tumor location, histological grading, and extent of resection. *Open J Mod Neurosurg* 2012;2:6-10.
28. Jee TK, Jo KI, Seol HJ, Kong DS, Lee JI, Shin HJ. Clinical features and treatment outcome of chordoid meningiomas in a single institute. *J Korean Neurosurg Soc* 2014;56:194-9.