

Rupture of Persistent Primitive Trigeminal Artery-basilar Artery Aneurysm Managed with Stent-assisted Coiling

Abstract

Persistent primitive trigeminal artery (PPTA), a fetal carotid-basilar anastomosis, is the most common embryological vascular remnant persisting into adult age. However, reported cases associated with cerebral aneurysms are rare. A 33-year-old female presented with an extremely rare PPTA-basilar artery (PPTA-BA) aneurysm manifesting as subarachnoid hemorrhage. Computed tomography revealed subarachnoid bleeding in the prepontine cistern, and cerebral angiography disclosed a PPTA-BA aneurysm. The aneurysm was managed with stent-assisted coiling technique to achieve complete obliteration. The patient was discharged without neurological deficits 2 weeks later. At 6 months follow-up, the patient is doing well and has returned to her previous daily activities. PPTA-BA aneurysms usually present with cranial nerve palsy and sometimes with carotid-cavernous fistulae if they rupture. Their deep seating favors interventional management as a first option and this case illustrates the efficacy and safety of endovascular treatment. This case adds to the evidence that endovascular techniques are a safe and effective tool in managing aneurysms of the primitive trigeminal artery. Even in cases where the anastomosis itself is not preserved, the patient can be managed satisfactorily, provided that the patency of the basilar and the carotid artery are kept, like in our patient.

Keywords: Aneurysm, basilar artery, persistent primitive trigeminal artery, stent-assisted coiling, subarachnoid hemorrhage

Introduction

Persistent primitive trigeminal artery (PPTA), a fetal carotid-basilar anastomosis, is the most common embryological vascular remnant persisting until the adult age. However, reported cases associated with cerebral aneurysms (CAs) are rare. To our knowledge, only five previous cases of ruptured aneurysms as a cause of subarachnoid hemorrhage (SAH) have been described. Two of them were operated,^[1,2] and the other three were embolized.^[3-5]

In this case report, we describe a patient presenting with a ruptured CA of PPTA-basilar artery (PPTA-BA). The aneurysm was successfully managed by embolization, and the patient eventually recovered from cognitive impairment caused by the hemorrhage. At 6 months follow-up, the patient is doing well and has returned to her previous daily activities.

Due to their rarity, PPTA aneurysms might be unnoticed if not systematically searched

for and their variations and clinical implications are important to be considered when they are found.^[2,6-9] The coexistence of unilateral or even bilateral^[10,11] PPTA and CA has already been reported. However, the PPTA has often been an incidental finding,^[12,13] and cases of SAH due to ruptured aneurysms and a successful treatment have only recently been reported. Some of them were operated,^[1,2] and the proportion of cases managed endovascularly have been increasing.^[3,5,14]

Case Report

A right-handed 33-year-old female without any previous relevant medical history presented with sudden headache and loss of consciousness while performing household tasks with no Valsalva maneuvers.

On her arrival, she was still drowsy, and neuroradiological workup (brain computed tomography and magnetic resonance imaging) disclosed a Fisher III diffuse SAH. An emergent diagnostic digital subtraction angiography confirmed the presence of a laterobasilar artery

**Marco Zenteno,
Angel Lee,
Luis Rafael
Moscote-Salazar¹**

*Department of Neurological Endovascular Therapy, Comprehensive Stroke Center, Hospital Angeles del Pedregal, Instituto Nacional de Neurología y Neurocirugía, Mexico City, Mexico,
¹Department of Neurosurgery, University of Cartagena, Cartagena de Indias, Colombia*

Address for correspondence:

*Dr. Marco Zenteno,
Department of Neurological Endovascular Therapy, Comprehensive Stroke Center, Hospital Angeles del Pedregal, Instituto Nacional de Neurología y Neurocirugía, Mexico City, Mexico.
E-mail: mazente@me.com*

Access this article online

Website: www.asianjns.org

DOI: 10.4103/ajns.AJNS_53_16

Quick Response Code:



How to cite this article: Zenteno M, Lee A, Moscote-Salazar LR. Rupture of persistent primitive trigeminal artery-basilar artery aneurysm managed with stent-assisted coiling. Asian J Neurosurg 2018;13:817-21.

This is an open access journal, and articles are distributed under the terms of the Creative Commons Attribution-NonCommercial-ShareAlike 4.0 License, which allows others to remix, tweak, and build upon the work non-commercially, as long as appropriate credit is given and the new creations are licensed under the identical terms.

For reprints contact: reprints@medknow.com

aneurysm arising at the middle third of the vessel at the site of connection with a primitive trigeminal artery (PTA). According to the classification designed by Kai *et al.*,^[14] this would be a PPTA-BA aneurysm that is to say an aneurysm arising at the junction of the BA with the PPTA. Somnolence was attributed to acute hydrocephalus, and a transient ventriculostomy was placed, with partial recovery of consciousness. Due to the complexity of the lesion and reluctance from relatives to open neurosurgical management, an endovascular approach was decided.

A stent-assisted coiling strategy was decided, and a stent placement in the basilar trunk for aneurysm closure was uneventful. In addition, permanent occlusion of the anastomosis was also performed. A week later, chronic hydrocephalus developed, a ventriculoperitoneal shunt was placed, and the patient was discharged another 7 days later. After 6 months of follow-up, she is totally asymptomatic and has returned to her everyday activities.

Endovascular procedure

Under general anesthesia, after a catheter was placed in the right carotid artery (both vertebral arteries were narrow and were very spastic after the placement of a 6 F guiding catheter), a diagnostic angiogram showed a saccular laterobasilar aneurysm [Figure 1a and b]. It arose precisely at the site of junction of the basilar trunk with the PPTA.

After intravenous antiplatelet treatment with tirofiban elsewhere described,^[15] a self-expanding 3.0 mm × 20 mm Neuroform3 Stent (Boston Scientific/Stryker, Fremont, California, USA) was placed in the basilar trunk as a scaffold for stent-assisted coiling. An Excelsior SL-10 Microcatheter (Boston Scientific/Stryker, Fremont, California, USA) was placed into the sac through the stent mesh and allowed coiling with 3 GDC coils (3 mm × 8 cm GDC-360 and 2 mm × 6 cm Ultra-soft) (Boston Scientific/Stryker, Fremont, California, USA).

Postoperative course

Before her discharge, a follow-up angiogram [Figure 2a and b] confirmed the results of the postprocedural control.

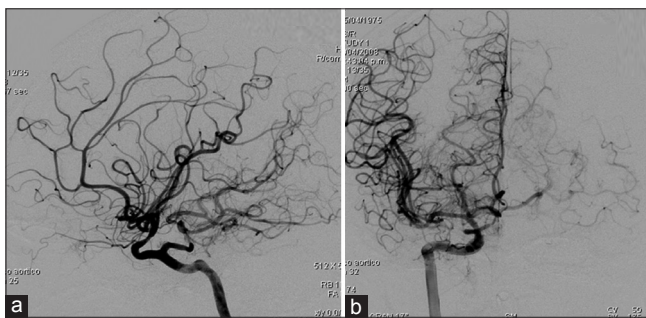


Figure 1: (a and b) Cerebral angiogram showing a saccular laterobasilar aneurysm, it arose precisely at the site of junction of the basilar trunk with the persistent primitive trigeminal artery

She gradually recovered her neurological functions and was discharged 2 weeks after the initial episode. A double antiplatelet regimen was instated with clopidogrel and aspirin at usual doses (75 and 100 mg qd, respectively). For the next 3 years, she has regularly attended her medical controls, and the 6-month and 2-year angiograms both corroborate the occlusion of the aneurysm, the patency of the basilar trunk, and the absence of intimal hyperplasia.^[16]

Discussion

The primitive trigeminal intersegmental artery is the most frequent of the persistent fetal anastomoses^[17] between the carotid and vertebrobasilar circulations.^[18-20] The trigeminal, otic, hypoglossal, and proatlantal are named for their relationship with the trigeminal ganglion, otic vesicle, hypoglossal nerve, and dorsal aorta, respectively.^[21] The connection to the carotid artery is usually just proximal to the cavernous sinus or just proximal to the meningo-hypophyseal trunk and to the BA between the superior cerebellar and anterior inferior cerebellar arteries.^[21] The PPTA runs through the cavernous sinus, posteromedial to the ophthalmic branch of the trigeminal nerve, or lateral to the dorsum sellae, crossing it, and binds to the basilar trunk.^[21] The occurrence of PPTA has been seen in 0.06%–0.6% of the cases.^[22-29] Table 1 lists the cases of PPTA and variant aneurysms, with clinical remarks.

In a recent paper, Weon *et al.* analyzed magnetic resonance angiograms of 7329 patients and found a prevalence of 24 patients with PPTA. Nine aneurysms in seven patients were found in this subgroup, yielding an incidence of 29% of aneurysms in patients with PPTA,^[28] which suggests that aneurysms are much more common than previously reported by Cloft *et al.*,^[38] who described an incidence of 3%. This might suggest that these vascular lesions are present more often than causal in PPTA.^[28] The PPTA has also been seen concomitantly with such diverse nonvascular disorders as pituitary adenoma,^[25] hemifacial spasm, cranial nerve paresis,^[39] and trigeminal neuralgia;^[40] its occurrence in vascular abnormalities such as Moyamoya disease,^[24] arteriovenous malformations,^[41]

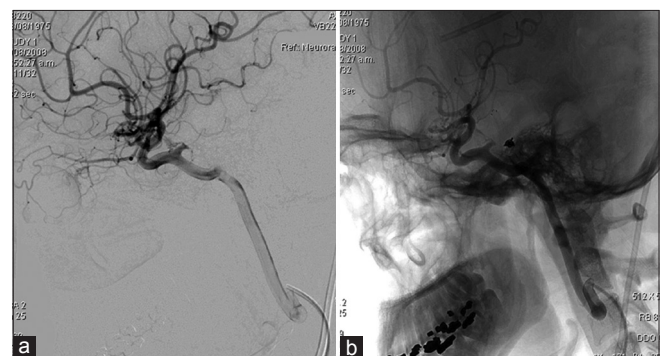


Figure 2: (a and b) Cerebral angiogram showing both the occlusion of the aneurysm and the patency of the basilar trunk

Table 1: Cases of persistent trigeminal artery variant aneurysm

Case number	Author (reference)	Year	Age (years)	Sex	Side	AN side	AN type	Remarks
1	Matsuda <i>et al.</i> ^[31]	1979	32	Female	Right	P-com, ICA-PTAV	Undocumented	Hemorrhage, AVM, multiple AN
2	Watanabe <i>et al.</i> ^[32]	1988	67	Female	Right	ICA-PTAV	Fusiform	Hemorrhage, multiple AN
3	Nioka <i>et al.</i> ^[33]	1993	52	Female	Left	ICA-PTAV	Saccular	Hemorrhage, multiple AN
4	Hayashi <i>et al.</i> ^[34]	1994	47	Female	Right	ICA-PTAV	Saccular	Hemorrhage
5	Hanabusa <i>et al.</i> ^[5]	2000	71	Female	Left	PTAV	Saccular	Hemorrhage, two segments of the left PTAV
6	Nishio <i>et al.</i> ^[35]	2001	69	Female	Right	ICA-PTAV	Saccular	Diplopia
7	Shin <i>et al.</i> ^[36]	2005	40	Male	Right	ICA-PTAV	AN dilatation	Hemorrhage, CCF
8	Yang <i>et al.</i> ^[37]	2010	48	Male	Right	PTAV	Fusiform	Hemorrhage, hypoplastic AICA, VA
9	Yamamoto <i>et al.</i> ^[30]	2011	82	Female	Bilateral	MCAm PTAV	Saccular and fusiform	Hemorrhage, multiple AN
10	Aguiar <i>et al.</i> ^[3]	2011	53	Female	-	BA-PTAV	Saccular	Hemorrhage
11	Current case	2013	33	Female	-	BA-PTAV	Saccular	Hemorrhage, somnolence

Actualized from.^[30] P-com – Posterior communicating artery; ICA – Internal carotid artery; PTAV – Persistent trigeminal artery variant; BA – Basilar artery; MCA – Middle cerebral artery; AVM – Cerebral arteriovenous malformation; AN – Aneurysm; CCF – Carotid cavernous fistula; AICA – Anterior inferior cerebellar artery; VA – Vertebral artery

carotid-cavernous fistula,^[42] or alterations of the internal carotid artery (ICA)^[4] has also been reported. As we have said, the association of PPTA with intracranial aneurysms has recently be found to be relatively high, up to 29% of the patients with PTA.^[28] When rupturing, either they cause a carotid-cavernous fistula,^[28,43] or they bleed into the subarachnoid space.^[1-3,14] Ruptured aneurysms with SAH have been operated^[1,18] or embolized.^[3,5,14] Our case is the fourth after those mentioned to have been successfully managed endovascularly. Moreover, Ladner *et al.* have reported a successful embolization of an aneurysm of the PTA causing a trigeminal neuralgia.^[44]

Most aneurysms associated with the PTA are located at the bifurcation of the carotid artery and the PTA,^[14,19] whereas aneurysms arising at the PPTA trunk rare and those from PTA-BA junction are even less frequent. In a series of 39 cases described by Kwon *et al.*,^[24,45] the aneurysm was located at the bifurcation of the cavernous segment of the ICA and PTA in 17 cases, at the trunk of the PTA in ten, and at the junction of the ICA with the BA in five. In the remaining seven cases, the location of aneurysms was not described in detail.

The rupture of a CA associated with a PPTA, symptoms are either due to compression of the outer wall of the cavernous sinus with deficit of the III, IV, V, or VI cranial nerves. On the other side, the clinical presentation may be a typical acute SAH.

We presented a rare case of SAH associated with basilar aneurysms and PTA. The endovascular management of basilar aneurysms associated with persistent trigeminal artery can be managed successfully by endovascular methods. However, most of them were diagnosed because of compressive symptoms of the oculomotor nerves, due to their compression in the outer wall of the cavernous sinus. Including this presented case, only four cases of

ruptured aneurysms have been reported. Two of them were uneventfully managed with open surgery,^[1,2] and the third was embolized.^[3,14] Our case is particular in that we have shown that endovascular technique is not only effective in occluding the aneurysm but is also safe in case of occlusion of the carotid-basilar anastomosis, in the rarest location of the lesion.^[45]

Conclusion

This case adds to the evidence that endovascular techniques are a safe and effective tool in managing aneurysms of the PTA. Even in cases where the anastomosis itself is not preserved, the patient can be managed satisfactorily, provided that the patency of the basilar and the carotid artery is kept, like in our patient.

Financial support and sponsorship

Nil.

Conflicts of interest

There are no conflicts of interest.

References

- Menkü A, Akdemir H, Tucer B, Kurtsoy A. Ruptured aneurysm associated with persistent primitive trigeminal artery: Report of a case with three dimensional CT angiographic evaluation. *Turk Neurosurg* 2004;14:21-4.
- Wolpert SM. The trigeminal artery and associated aneurysms. *Neurology* 1966;16:610-4.
- Aguiar GB, Conti ML, Veiga JC, Jory M, Souza RB. Basilar artery aneurysm at a persistent trigeminal artery junction. A case report and literature review. *Interv Neuroradiol* 2011;17:343-6.
- Chambers AA, Lukin R. Trigeminal artery connection to the posterior inferior cerebellar arteries. *Neuroradiology* 1975;9:121-3.
- Hanabusa K, Murao K, Morikawa A, Taki W, Waga S. Endovascular treatment for a ruptured persistent trigeminal artery

- variant aneurysm on the distal portion – Case report. *Neurol Med Chir (Tokyo)* 2000;40:637-40.
6. Ali S, Radaideh MM, Shaibani A, Russell EJ, Walker MT. Persistent trigeminal artery terminating in the posterior inferior cerebellar artery: Case report. *Neurosurgery* 2008;62:E746-8.
 7. Fields WS. The significance of persistent trigeminal artery. *Carotid-Basilar anastomosis. Radiology* 1968;91:1095-101.
 8. Padget D. The Development of the Cranial Arteries in the Human Embryo. *Contribution to Embryology. Carnegie Institution, Vol. 32, 1948. p. 205-62.*
 9. Yilmaz E, Ilgit E, Taner D. Primitive persistent carotid-basilar and carotid-vertebral anastomoses: A report of seven cases and a review of the literature. *Clin Anat* 1995;8:36-43.
 10. Ali S, Walker MT. Bilateral persistent trigeminal arteries associated with bilateral carotid aneurysms. *J Vasc Interv Radiol* 2007;18:692-4.
 11. Alleyne CH Jr., Krisht A, Yoo FK, Silverstein A, Colohan AR. Bilateral persistent trigeminal arteries associated with cerebral aneurysms and aortic arch vessel anomaly. *South Med J* 1997;90:434-8.
 12. Maeshima S, Tereda T, Masuo O, Nakai K, Itakura T, Komai N. Multiple cerebral aneurysms with persistent primitive trigeminal artery. *J Clin Neurosci* 1999;6:52-4.
 13. de Oliveira MA, Grotta CC, Assis MS. Persistent trigeminal artery associated with aneurysm of the middle cerebral artery. Case report and review of the literature. *Arq Neuropsiquiatr* 1997;55:834-40.
 14. Kai Y, Ohmori Y, Watanabe M, Morioka M, Hirano T, Kawano T, *et al.* Coil embolization of an aneurysm located at the trunk of the persistent primitive trigeminal artery. *Neurol Med Chir (Tokyo)* 2011;51:361-4.
 15. Aziz-Sultan A, Heros RC. Sole stenting. *J Neurosurg* 2008;108:1101-3.
 16. Zenteno M, Gómez CR, Santos-Franco J, Vinuela F, Aburto-Murrieta Y, Lee A. Ten-year follow-up of giant basilar aneurysm treated by sole stenting technique: A case report. *J Med Case Rep* 2010;4:64.
 17. Luh GY, Dean BL, Tomsick TA, Wallace RC. The persistent fetal carotid-vertebrobasilar anastomoses. *AJR Am J Roentgenol* 1999;172:1427-32.
 18. Eluvathingal Muttikkal TJ, Varghese SP, Chavan VN. Persistent trigeminal artery and associated vascular variations. *Australas Radiol* 2007;51:B31-3.
 19. Jackson IJ, Garza-Mercado R. Persistent carotidbasilar artery anastomosis: Occasionally a possible cause of tic douloureux. *Angiology* 1960;11:103-7.
 20. Takase T, Tanabe H, Kondo A, Nonoguchi N, Tane K. Surgically treated aneurysm of the trunk of the persistent primitive trigeminal artery – Case report. *Neurol Med Chir (Tokyo)* 2004;44:420-3.
 21. Tubbs RS, Verma K, Riech S, Mortazavi MM, Shoja MM, Loukas M, *et al.* Persistent fetal intracranial arteries: A comprehensive review of anatomical and clinical significance. *J Neurosurg* 2011;114:1127-34.
 22. Azab W, Delashaw J, Mohammed M. Persistent primitive trigeminal artery: A review. *Turk Neurosurg* 2012;22:399-406.
 23. George AE, Lin JP, Morantz RA. Intracranial aneurysm on a persistent primitive trigeminal artery. Case report. *J Neurosurg* 1971;35:601-4.
 24. Kwak R, Kadoya S. Moyamoya disease associated with persistent primitive trigeminal artery. Report of two cases. *J Neurosurg* 1983;59:166-71.
 25. Lee KS, Kelly DL Jr. Intracranial persistent trigeminal artery associated with a pituitary adenoma. Case report. *J Neurosurg* 1989;70:271-3.
 26. Matsushita A, Yanaka K, Hyodo A, Nose T. Persistent primitive otic artery with IC-cavernous aneurysm. *J Clin Neurosci* 2003;10:113-5.
 27. Ricolfi F, Decq P, Brugieres P, Blustajn J, Melon E, Gaston A. Ruptured fusiform aneurysm of the superior third of the basilar artery associated with the absence of the midbasilar artery. Case report. *J Neurosurg* 1996;85:961-5.
 28. Weon YC, Choi SH, Hwang JC, Shin SH, Kwon WJ, Kang BS. Classification of persistent primitive trigeminal artery (PPTA): A reconsideration based on MRA. *Acta Radiol* 2011;52:1043-51.
 29. Zhang CW, Xie XD, Yang ZG, Wang CH, You C, Mao BY, *et al.* Giant cavernous aneurysm associated with a persistent trigeminal artery and persistent otic artery. *Korean J Radiol* 2009;10:519-22.
 30. Yamamoto T, Hasegawa Y, Ohmori Y, Kawano T, Kai Y, Morioka M, *et al.* Ruptured cerebral aneurysm associated with a persistent primitive trigeminal artery variant. *Surg Neurol Int* 2011;2:126.
 31. Matsuda I, Handa J, Handa H, Yonekawa Y. Carotid-superior cerebellar anastomosis: A variant of persistent trigeminal artery associated with cerebral aneurysms and angiomatous malformation – Case report. *Nihon Geka Hokan* 1979;48:535-41.
 32. Watanabe T, Aoki A, Chan SC. Two cases of persistent trigeminal artery variant. *No Shinkei Geka* 1988;16:95-100.
 33. Nioka H, Nakazawa T, Matsuda M, Handa J. Cerebral aneurysms associated with persistent primitive trigeminal artery. *Jpn J Stroke* 1993;15:216-24.
 34. Hayashi M, Taira T, Terasaka N, Tanikawa T, Takakura K. Intracavernous internal carotid artery aneurysm associated with persistent trigeminal artery variant: Case report. *No Shinkei Geka* 1994;22:67-70.
 35. Nishio A, Nishijima Y, Komiyama M, Hara M. Primitive trigeminal artery variant aneurysm treated with Guglielmi detachable coils – Case report. *Neurol Med Chir (Tokyo)* 2001;41:446-9.
 36. Shin YS, Kim SY, Kim BM, Park SI. Ruptured aneurysm of the anomalous cerebellar artery originating from internal carotid artery presenting with carotid cavernous fistula: A case report. *AJNR Am J Neuroradiol* 2005;26:1849-51.
 37. Yang Z, Liu J, Zhao W, Xu Y, Hong B, Huang Q, *et al.* A fusiform aneurysm of a persistent trigeminal artery variant: Case report and literature review. *Surg Radiol Anat* 2010;32:401-3.
 38. Cloft HJ, Razack N, Kallmes DF. Prevalence of cerebral aneurysms in patients with persistent primitive trigeminal artery. *J Neurosurg* 1999;90:865-7.
 39. Nakamagoe K, Mamada N, Shiigai M, Shimizu K, Koganezawa T, Tamaoka A. Recurrent isolated abducens nerve paresis associated with persistent trigeminal artery variant. *Intern Med* 2012;51:2213-6.
 40. Conforti R, Parlato RS, De Paulis D, Cirillo M, Marrone V, Cirillo S, *et al.* Trigeminal neuralgia and persistent trigeminal artery. *Neurol Sci* 2012;33:1455-8.
 41. Mohanty CB, Devi BI, Somanna S, Bhat DI, Dawn R. Corpus callosum arteriovenous malformation with persistent trigeminal artery. *Br J Neurosurg* 2011;25:736-40.
 42. Guglielmi G, Viñuela F, Dion J, Duckwiler G, Cantore G, Delfini R. Persistent primitive trigeminal artery-cavernous sinus fistulas: Report of two cases. *Neurosurgery* 1990;27:805-8.
 43. Enomoto T, Sato A, Maki Y. Carotid-cavernous sinus fistula caused by rupture of a primitive trigeminal artery aneurysm.

Case report. J Neurosurg 1977;46:373-6.

44. Ladner TR, Ehtesham M, Davis BJ, Khan IS, Ghiassi M, Ghiassi M, *et al.* Resolution of trigeminal neuralgia by coil embolization of a persistent primitive trigeminal artery aneurysm. BMJ Case Rep 2013;2013. pii: Bcr2013010703.
45. Kwon K, Kim K, Jeon P, Byun H, Kim J, Hong S. Endovascular treatment for a persistent trigeminal artery aneurysm presenting as isolated sixth nerve palsy. Neurointervention 2007;2:113-6.