

## CASE REPORT

# A rare case of melorheostosis with intra-articular extension causing medial patellar impingement

Nilesh N Haran, Ameya S Kawthalkar<sup>1</sup>

Department of Radiodiagnosis, Tata Memorial Hospital, Mumbai, Maharashtra, <sup>1</sup>Department of Radiodiagnosis, Sir JJ Hospital and Grant Medical College, Mumbai, Maharashtra, India

**Correspondence:** Dr. Nilesh N Haran, Department of Radiodiagnosis, Tata Memorial Hospital Dr. E Borges Road, Parel, Mumbai, Maharashtra - 400 012 India. E-mail: nilesh.haran@gmail.com

## Abstract

Melorheostosis is an uncommon mesenchymal dysplasia manifesting as regions of sclerosing bone with a characteristic flowing candle wax appearance. We describe here a rare presentation of melorheostosis with the intra-articular extension of the disease in the knee joint and causing medial patellar impingement.

**Key words:** Computed tomography; magnetic resonance imaging; medial patellar impingement; melorheostosis; radiography

## Introduction

Melorheostosis also known as Leri's disease was first reported by Leri and Joanny in 1922.<sup>[1]</sup> It is a rare disorder and is non-hereditary, histologically presenting as benign sclerosing mesenchymal dysplasia. It has no familial predisposition and is diagnosed in late adolescence or early adulthood usually around 20 years of age. It involves the appendicular skeleton more commonly. The disorder has a very typical imaging finding of irregular and wavy hyperostosis on radiographs referred to as 'floating candle wax' appearance. We present a case of melorheostosis with intra-articular extension in the knee causing medial patellar impingement, which to our knowledge is the first such reported instance in medical literature.

## Case Report

A 30-year-old man presented with complaint of left-sided medial knee pain since 2 months. On physical examination

no deformity was seen. Laboratory investigations revealed serum calcium, phosphate, and alkaline phosphatase to be within normal limits. The orthopaedician referred the patient for imaging suspecting medial patellar impingement based on clinical examination findings. The patient underwent radiographs of the left knee which showed periosteal cortical thickening along the medial aspect of the left femur giving characteristic floating candle wax appearance as in melorheostosis. A small focus of soft tissue calcification was seen on the AP radiograph medial to the patella [Figure 1]. Magnetic resonance imaging (MRI) showed flowing ossification with low signal intensity on all the sequences along the medial femoral cortex and also within the medial aspect of the patella. In continuity with the femoral ossification, few low signal intensity deposits were seen in the medial aspect of femoro-patellar joint space indicating intra-articular extension of the

This is an open access journal, and articles are distributed under the terms of the Creative Commons Attribution-NonCommercial-ShareAlike 4.0 License, which allows others to remix, tweak, and build upon the work non-commercially, as long as appropriate credit is given and the new creations are licensed under the identical terms.

**For reprints contact:** WKHLRPMedknow\_reprints@wolterskluwer.com

**Cite this article as:** Haran NN, Kawthalkar AS. A rare case of melorheostosis with intra-articular extension causing medial patellar impingement. *Indian J Radiol Imaging* 2020;30:504-6.

**Received:** 21-Mar-2020

**Revised:** 14-May-2020

**Accepted:** 01-Sep-2020

**Published:** 13-Jan-2021

### Access this article online

#### Quick Response Code:



**Website:**  
www.ijri.org

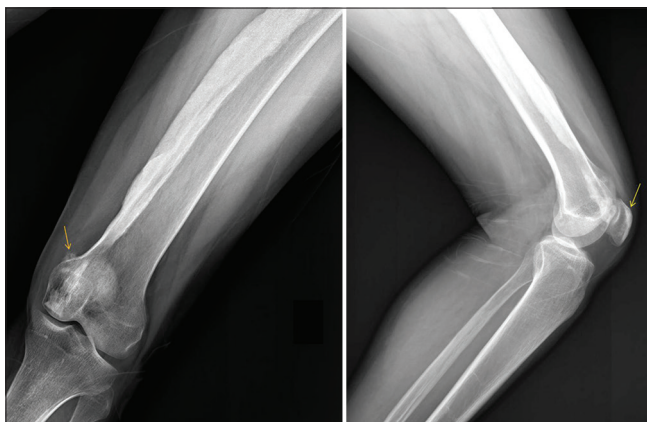
**DOI:**  
10.4103/ijri.IJRI\_189\_20

melorheostosis along the medial patellar retinaculum. Edema was seen surrounding these medial para-patellar intra-articular deposits in the fat pad and along medial patellar retinaculum. This was suggestive of possible impingement between the medial patella and the medial para-patellar soft tissue deposit; and it was corresponding with the site of the patient's pain [Figure 2]. Computed tomography (CT) was done to confirm the intra-articular calcification [Figure 3].

As imaging is classical, histopathological confirmation was not required. In our case the patient was treated conservatively with analgesia and physiotherapy and currently is on follow-up.

## Discussion

Melorheostosis is derived from two Greek words, "melos" which means limb and "rhein" which means flow.<sup>[2]</sup> It is a rare mesenchymal sclerosing dysplasia with disruption of intramembranous and enchondral ossification. It has no sex predilection. It is usually asymptomatic and diagnosed as an incidental finding on radiographs obtained for different purpose, so it has a variable age of presentation ranging from 2 to 64 years; however, majority present at 20–30 years of age.<sup>[3]</sup> Clinically symptomatic patients presents with painful limb swelling or restricted range of movements. Genetic basis of the disease is mutation in LEMD3 gene which encodes nuclear membrane protein.<sup>[4]</sup> The disease follows sclerotomal distribution i.e., only one side of body is involved or affects one bone (monostotic), or multiple bones (polyostotic) on same side of body, i.e., hands and leg on same side. The latter was the case in our study with medial aspect of left femur and patella affected.<sup>[5]</sup> Soft tissue abnormalities usually associated with it consist of osseous, chondroid, vascular and cartilaginous tissue. There are various known associations of the disease



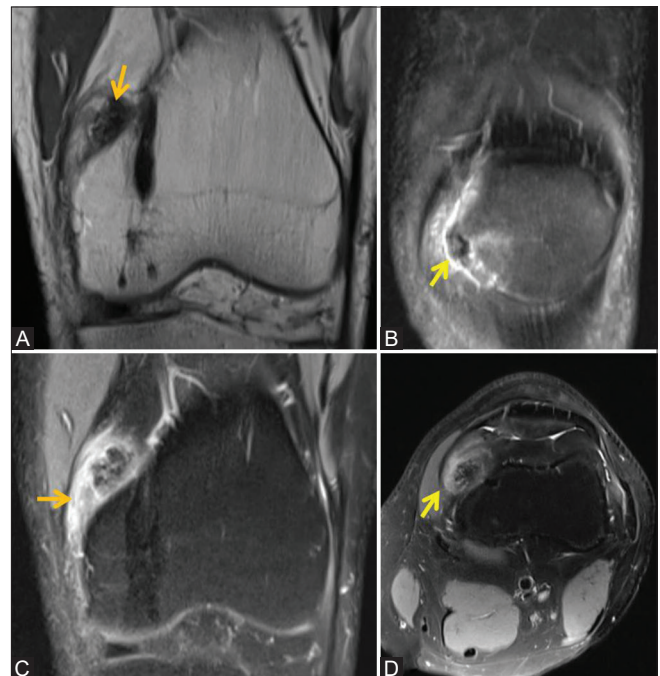
**Figure 1:** AP and lateral radiographs of left knee and femur show flowing "candle wax" like ossification along medial cortex of femur. A small focus of soft tissue calcification is seen on the AP radiograph medially adjacent to the patella (orange arrow). The lateral radiograph shows few foci of sclerosis within the patella (yellow arrow)

i.e., neurofibromatosis, tuberous sclerosis, scleroderma, rheumatoid arthritis and hypophosphatemic rickets.<sup>[6-9]</sup>

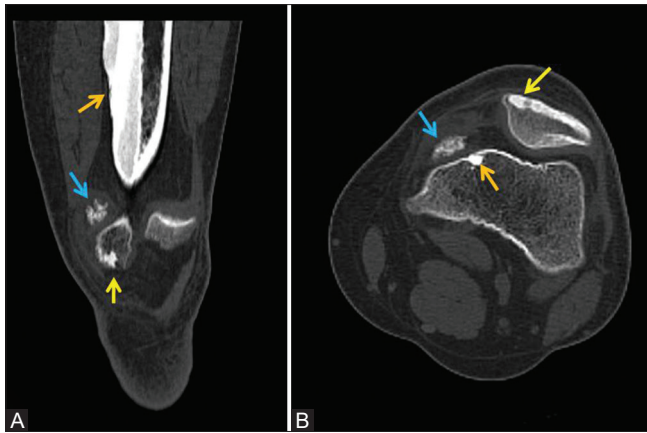
Five patterns of melorheostosis are described on imaging – classical, osteoma like, myositis ossificans like, osteopathia striata like and mixed type. Radiographs show asymmetric, linear, irregular bands of increased sclerosis described as molten wax dripping down from one side of candle, involving the outer bony cortex. A distinct demarcation between the affected bone and normal bone is always present. Diaphyseal involvement is mostly seen. Radiographs provide the characteristic appearance of disorder; however, CT and MRI are more useful in assessment of mineralized and non-mineralized soft tissue masses associated with this condition, and in possible complications like impingement as in our case. Bone scan is helpful in distinguishing the focus of melorheostosis from other lesions. On bone scan there is focal increased uptake due to increased osteoblastic activity.

Histology shows presence of chondroid islands surrounded by mature lamellar and woven bone as well adjacent zones of fibrocartilage. Biochemistry reveals normal serum calcium, phosphate and alkaline phosphate levels thus discriminating it from other metabolic disorders.<sup>[10]</sup>

On imaging, differential diagnosis of melorheostosis involves myositis ossificans, chronic osteomyelitis,



**Figure 2 (A-D):** (A) Coronal PD image of the knee shows linear hypointense ossification along medial femoral cortex. A focus of low intensity is seen in the medial soft tissues (orange arrow) with adjacent low signal intensity in the para-patellar fat pad. (B) Coronal PD fat sat images of the knee show focal ossification along the medial patellar cortex with adjacent para-patellar edema. (C and D) Coronal and Axial PD fat sat image shows edema along the medial patellar retinaculum and in the medial para-patellar fat pad



**Figure 3 (A and B):** Coronal (A) and Axial (B) CT showing ossification along medial femoral cortex (orange arrow), small calcified lesion along medial patellar retinaculum with adjacent fat stranding and edema (blue arrow) and ossific foci along medial aspect of patella (yellow arrow)

parosteal and periosteal osteosarcoma, osteoid osteoma and Caffey's disease. Intra-articular extension of melorheostosis can mimic osteochondromatosis, as in our case. Our findings for this patient are similar to the ones encountered by Wadhwa *et al.*<sup>[11]</sup> in whose case the patient had chronic and generalized knee pain and stiffness clinically, with chronic synovitis on MRI without signs of edema or impingement. However in our case the patient had features of medial patellar impingement clinically and on imaging as a result of the intra-articular deposit with extensive soft tissue edema.

Treatment of melorheostosis depends on age, extent, anatomic location, and associated soft tissue changes. The condition as such is not fatal and treatment is only symptomatic. Recurrence after operative excision can be seen. Primarily treatment is done to relieve pain and provide full range of motion. Conservative measures include analgesia, physiotherapy, casting, nerve blocks etc.

## Conclusion

Melorheostosis is a rare, benign, incidentally diagnosed disorder until patient is symptomatic. Intra-articular extension is very rare presentation of this disease which is usually symptomatic, and may result in intra-articular impingements. Knowledge of the characteristic imaging findings and its pattern of involvement can prevent unwanted biopsies and morbidity to patient, and lead the path to appropriate management.

## Declaration of patient consent

The authors certify that they have obtained all appropriate patient consent forms. In the form the patient(s) has/have given his/her/their consent for his/her/their images and other clinical information to be reported in the journal. The patients understand that their names and initials will not be published and due efforts will be made to conceal their identity, but anonymity cannot be guaranteed.

## Financial support and sponsorship

Nil.

## Conflicts of interest

There are no conflicts of interest.

## References

1. Leri A, Joanny J. Une affection non decrite des os hyperostose "encoulee" surtout la longueur d'un membre ou "melorheostose". Bull Memoires Soc Med Hopitaux Paris 1922;46:1141-5.
2. Resnick D. Diagnosis of Bone and Joint Disorders. 3<sup>rd</sup> ed. Philadelphia, PA: WB Saunders; 1995.p. 4410-3.
3. Hellemans J, Preobrazhenska O, Willaert A, Debeer P, Verdonk PC, Costa T, *et al.* Loss-of-function mutations in LEMD3 result in osteopoikilosis, Buschke-Ollendorff syndrome and melorheostosis. Nat Genet 2004;36:1213-8.
4. Kalbermatten NT, Vock P, Rüfenacht D, Anderson SE. Progressive melorheostosis in the peripheral and axial skeleton with associated vascular malformations: Imaging findings over three decades. Skeletal Radiol 2001;30:48-52.
5. Suresh S, Muthukumar T, Saifuddin A. Classical and unusual imaging appearances of melorheostosis. Clin Radiol 2010;65:593-600.
6. Yoon J, Al Shafai L, Nahal A, Turcotte RE, Martin MH. Melorheostosis of the sacrum causing acute-onset neurological symptoms. Skeletal Radiol 2011;40:1369-73.
7. Zeiller SC, Vaccaro AR, Wimberley DW, Albert TJ, Harrop JS, Hilibrand AS. Severe myelopathy resulting from melorheostosis of the cervicothoracic spine. A case report. J Bone Joint Surg Am 2005;87:2759-62.
8. Saxena A, Neelakantan A, Jampana R, Sangra M. Melorheostosis causing lumbar radiculopathy: A case report and a review of the literature. Spine J 2013;13:e27-9.
9. McCarthy M, Mehdian H, Fairbairn KJ, Stevens A. Melorheostosis of the tenth and eleventh thoracic vertebrae crossing the facet joint: A rare cause of back pain. Skeletal Radiol 2004;33:283-6.
10. Choi IH, Kim JI, Yoo WJ, Chung CY, Cho TJ. Ilizarov treatment for equinoplanovalgus foot deformity caused by melorheostosis. Clin Orthop Relat Res 2003;414:238-41.
11. Wadhwa V, Chhabra A, Samet JD. Melorheostosis mimicking synovial osteochondromatosis. Ann Saudi Med 2014;34:547-50.