

Dilemma of diagnosing thoracic sarcoidosis in tuberculosis endemic regions: An imaging-based approach. Part 1

Ashu S Bhalla, A Das, P Naranje, A Goyal, R Guleria¹, Gopi C Khilnani¹

Departments of Radiodiagnosis, ¹Pulmonary Medicine and Sleep Disorders, All India Institute of Medical Sciences, New Delhi, India

Correspondence: Dr. Ashu S Bhalla, Department of Radiodiagnosis, All India Institute of Medical Sciences, New Delhi - 110 029, India.
E-mail: ashubhalla1@yahoo.com

Abstract

Sarcoidosis is a multi-systemic disorder of unknown etiology, although commonly believed to be immune-mediated. Histologically, it is characterized by noncaseating granuloma which contrasts against the caseating granuloma seen in tuberculosis (TB), an infectious disease that closely mimics sarcoidosis, both clinically as well as radiologically. In TB-endemic regions, the overlapping clinico-radiological manifestations create significant diagnostic dilemma, especially since the management options are markedly different in the two entities. Part 1 of this review aims to summarize the clinical, laboratory, and imaging features of sarcoidosis, encompassing both typical and atypical manifestations, in an attempt to distinguish between the two disease entities.

Key words: Cough; interstitial; lung diseases; lymphadenopathy; sarcoidosis; tuberculosis

Introduction

Sarcoidosis is a multi-systemic chronic granulomatous disease of unknown etiology. It is hypothesized to be an immune-mediated inflammatory response to an unidentified environmental trigger.^[1] Histopathologically, the entity is characterized by non-caseating granuloma with variable collagen deposition in the periphery. Tuberculosis (TB), on the other hand, is an infectious disease caused by *Mycobacterium tuberculosis* (MTB) and is characterized by caseating granulomas on histology.

The global incidence of sarcoidosis varies widely, likely due to the variability in exposure to environmental triggers and

genetic predispositions, as well as lack of a uniform screening program. The data from western literature reported an annual incidence of 5–40 cases/100,000 population in north European countries,^[2] and an estimated prevalence of less than 1–40 cases/100,000 population in the United States.^[3] In India, the reporting of sarcoidosis has been, by far, sketchy; mainly hampered by its close resemblance to the commoner granulomatous disease-TB. Amongst the available data, 10–12 cases of sarcoidosis per 1,000 new registrations were reported from a respiratory unit in Kolkata, while 61.2/100,000 cases were reported from a center in Delhi.^[4,5] However, in the absence of any large scale epidemiological study, the true prevalence of the disease

This is an open access article distributed under the terms of the Creative Commons Attribution-NonCommercial-ShareAlike 3.0 License, which allows others to remix, tweak, and build upon the work non-commercially, as long as the author is credited and the new creations are licensed under the identical terms.

For reprints contact: reprints@medknow.com

Cite this article as: Bhalla AS, Das A, Naranje P, Goyal A, Guleria R, Khilnani GC. Dilemma of diagnosing thoracic sarcoidosis in tuberculosis endemic regions: An imaging-based approach. Part 1. Indian J Radiol Imaging 2017;27:369-79.

Access this article online

Quick Response Code:



Website:
www.ijri.org

DOI:
10.4103/ijri.IJRI_200_17

in Indian population remains unclear. On the other hand, the global incidence of TB is estimated to be 10.4 million according to the World Health Organization (WHO) Global Tuberculosis Report 2016. Out of the 30 high TB burden countries enlisted by the report, India has been identified as having the highest number of new cases of active disease in 2015 with an estimated incidence of 2.8 million. India, along with China and Indonesia alone accounted for 45% of the global TB burden.^[6]

The diagnostic guidelines developed in western literature for clinicoradiological diagnosis of sarcoidosis cannot be duplicated for use in TB-endemic areas. This is because many a times, TB may present with similar clinicoradiological manifestations as sarcoidosis. Also, uncommon manifestations of TB may be commoner than typical presentation of sarcoidosis. In a TB-endemic country like India, the implications of such a problem is profound, especially because of different treatment regimens for the two disease entities. While sarcoidosis responds well to corticosteroids, the administration of the latter without concomitant anti-TB drugs may lead to worsening in TB. To add to this dilemma, the two diseases can co-exist occasionally. This article thus attempts to delineate the clinical and imaging features to distinguish between the two entities. Part 1 of this review deals with the clinical and laboratory parameters as well as the typical and atypical radiological features of thoracic sarcoidosis, highlighting discriminating features from TB. Part 2 involves reprisal of the current role of different imaging modalities followed by imaging recommendations for a suspected case of thoracic sarcoidosis/TB. The authors conclude by proposing an imaging algorithm for evaluating such patients in TB endemic regions.

Clinical Features

The constitutional symptoms such as fever, malaise, fatigue, weight loss, and night sweats are non-specific and common to both the diseases; however, fatigue is an important symptom of sarcoidosis^[7] while chronic fever, significant weight loss and night sweats are more marked in TB.

Similarly, respiratory symptoms may overlap between the two entities, but while sarcoid patients tend to have dry cough and dyspnoea, patients with pulmonary TB usually present with cough and expectoration. Hemoptysis, although, not exclusive to TB is more frequently encountered than in sarcoidosis.^[8-10] Both the disease entities can have diverse extrathoracic manifestations (musculoskeletal, neurological involvement, and abdominal manifestations), the detailed discussion of which is beyond the scope of this article. Common to both sarcoidosis and TB are peripheral lymphadenopathy and anterior uveitis. However, several clinical entities have been classically described in sarcoidosis including dermatological manifestations such as *erythema*

nodosum and *lupus pernio*, Bell's palsy, parotid enlargement, arthralgia especially ankle pain and named syndromes such as Lofgren syndrome (erythema nodosum, fever, and arthralgia) and Heerfordt syndrome (fever, uveitis, and parotitis parotiditis).^[8]

Table 1 enumerates the clinical features which may aid in distinguishing amongst the two entities.

Laboratory Investigations

While in TB, the gold standard of diagnosis is microbiological confirmation, histopathological congruency forms the basis of diagnosis in sarcoidosis. Although, in certain cases where the clinicoradiological manifestations are typical of sarcoidosis such as Lofgren syndrome, Heerfordt syndrome, the need for biopsy may be obviated. Short of histopathological confirmation, certain laboratory investigations may provide supportive evidence. A detailed description of these cannot be undertaken here and, hence a brief summary follows.

Tuberculin skin test (TST) a positive TST as a marker of tubercular infection has a specificity of >85%. On the other hand, tuberculin sensitivity is depressed in sarcoidosis, even in high TB prevalence areas. The patients with sarcoidosis are more likely to have a negative TST as compared to healthy general population.^[11] As compared to tuberculin test, interferon-gamma release assays (IGRAs) using blood QuantiFERON-TB-Gold In Tube assay have a higher sensitivity and specificity for detecting mycobacterium TB (MTB) infection.

Serum angiotensin converting enzyme (ACE) is frequently used for the diagnosis of sarcoidosis and its elevation is seen in 60% to 80% patients, but is not specific as it may also be elevated in patients with TB as well as other diseases.^[12] The sensitivity, specificity, positive, and negative predictive values for serum ACE in patients with sarcoidosis reported are 58.1%, 83.8%, 83.8%, and 58.1%, respectively.^[13] Serum ACE estimation has also been advocated as a measure of disease activity. Sarcoidosis however, remains the most common cause of elevated serum ACE level and values in excess of two times the

Table 1: Differences in predominant clinical features between sarcoidosis and tuberculosis (TB)

Predominant feature	Sarcoidosis	TB
Constitutional	Fatigue, myalgia Fever (less common)	Fever, weight loss
Respiratory	Dry cough Dyspnea	Productive cough, hemoptysis
Extra-thoracic	Parotid enlargement, Bell's palsy, arrhythmias, lupus pernio, and erythema nodosum	Cervical adenopathy, cutaneous sinus, joint pain and swelling, neck stiffness

upper limit of normal are rarely encountered in other disease entities.^[12] A variable range of elevation has been reported in TB (especially miliary TB), sometimes overlapping with that of sarcoidosis.^[13-15]

Hypercalcemia is reported in about 2–10% of patients with sarcoidosis and hypercalciuria is even more frequent, being attributed to disturbance in normal vitamin D metabolism by activated macrophages and granulomas.^[8] This is very uncommon in TB, but has been infrequently reported in miliary TB.^[16] The neutrophil/lymphocyte ratio (NLR) is a recently suggested marker that can be calculated easily from a routine complete blood count. Table 2 summarizes the differentiating laboratory parameters.

Imaging Manifestations

Both thoracic sarcoidosis and TB may involve mediastinal lymph nodes (LN), pulmonary parenchyma as well as pleura.

Lymphadenopathy

Enlarged mediastinal LN is the most commonly encountered imaging finding in patients of sarcoidosis. The most common pattern, seen in about 95% of patients, is enlarged bilaterally symmetric hilar and right paratracheal LN [Figure 1]. Other groups of mediastinal LN that may be involved include left paratracheal, subcarinal, aortopulmonary window, and prevascular locations. This pattern of mediastinal LN is suggestive, but not specific for sarcoidosis and may be seen in infections and malignancy.

Atypical patterns of involvement are usually seen in elderly patients and may include unilateral hilar LN or mediastinal LN without hilar involvement, as well as involvement of unusual locations like internal mammary, retrocrural, and peridiaphragmatic location.

On the other hand, mediastinal LN is seen in about 43% of adults with TB and is a more common manifestation in pediatric age-group.^[18] The bilateral involvement is less common than that of sarcoidosis. Most commonly involved groups include right paratracheal, hilar, and subcarinal [Figure 2].

The enlarged LN in sarcoidosis tend to be well-defined, homogenous, and discrete with no evidence of coalescence [Figure 1]. While in TB, the LN characteristically display “rim sign” consisting of hypodense core surrounded by peripheral rim of enhancement [Figure 2]. In addition, they may also reveal heterogeneous enhancement along with conglomeration and obscuration of perinodal fat in active disease, in contrast to homogeneous, discrete LN in sarcoidosis [Figure 2]^[18] Recently, a new sign “cluster of black pearl” sign has been described on thin section contrast-enhanced multidetector CT which has been found to have 83% sensitivity, 98% specificity and

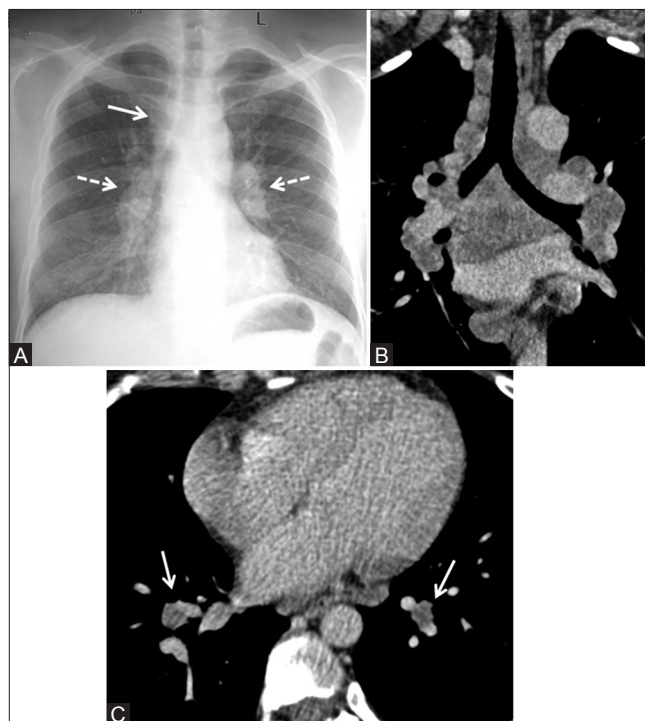


Figure 1 (A-C): Sarcoidosis: typical mediastinal lymphadenopathy. (A) Chest X-ray (CXR) showing bilaterally symmetrical hilar (dashed arrows) and right paratracheal lymphadenopathy (solid arrow) without parenchymal abnormality. (B) Coronal reformatted image of contrast-enhanced computed tomography (CECT) chest showing well-defined, discrete, homogenous, non-coalescent lymph nodes in right paratracheal and bilateral hilar lymph nodes along with subcarinal and left paratracheal regions. (C) Axial CECT image at lower level showing involvement of bronchopulmonary group of lymph nodes bilaterally characteristically seen in sarcoidosis (white arrows)

Table 2: Differentiating points in laboratory investigations between sarcoidosis and tuberculosis (TB)

Laboratory investigations	Sarcoidosis	TB
Biopsy	Non-necrotizing lymphocyte poor (“naked”) granulomas	Lymphocyte dense necrotizing granulomas
Acid-fast bacilli (AFB) positive and/or culture-positive	May be rarely seen in coexistent cases	Diagnostic
Tuberculin skin test (TST)	Usually negative	Positive, specificity of >85%
IGRA using QuantiFERON-TB-Gold In Tube assay (QFT) in blood ^[11]	Positive in upto 34%	Higher sensitivity and specificity for MTB detection.
Serum angiotensin-converting enzyme (ACE)	More than twice elevation in 60% to 80% cases	Variable
Hypercalcemia	Fairly characteristic	Not seen
Urine analysis-Hypercalciuria	Fairly characteristic	Not seen
Neutrophil/lymphocyte ratio in blood ^[17]	<2.55	≥2.55

91% positive predictive value for diagnosis of sarcoid lymphadenopathy^[19].

The calcification may occur within the LN which may be seen in 5–50% of cases of sarcoidosis^[20] and the development of calcification correlates positively with the duration of disease.^[1] The pattern of calcification can range from punctuate, pop-corn or egg-shell like. The egg-shell pattern

of calcification has been reported in about 5% cases of sarcoidosis^[21] though it is more commonly seen in silicosis and coal worker's pneumoconiosis. Even then, amongst granulomatous diseases, this feature is helpful because tubercular LN have not been reported to show this pattern of calcification; rather they show homogenous calcification on healing.

Tubercular LN, on the other hand, show homogenous calcification representative of inactive disease. Other causes of mediastinal lymphadenopathy including lymphoma, Castleman's disease have not been discussed as they are beyond the scope of this article. Table 3 below summarizes the differentiating features in the pattern of involvement of mediastinal lymphadenopathy in the two diseases.

Parenchymal changes

Parenchymal changes aid in the differentiation of sarcoidosis and TB as overlapping features are fewer in this domain. The features of parenchymal imaging findings include:

Nodules and masses

The most common pattern of parenchymal involvement in sarcoidosis is small nodules in perilymphatic distribution seen in 75–90% cases.^[23] These nodules measure about 2–4 mm and are well-defined and round in shape. The involvement is usually bilaterally symmetrical, predominantly in upper and mid zones. The distribution follows the bronchovascular and subpleural interstitium, interlobar fissures, and sometimes along interlobular septae [Figure 3]. These micronodules may, over time coalesce, to form macronodules [Figure 3].^[23] The perilymphatic distribution of nodules leading to irregular nodular septal thickening may also be seen in lymphangitis carcinomatosa which forms an important imaging differential; however, the latter involves prominent and extensive interstitial thickening which is absent in sarcoidosis.^[23]

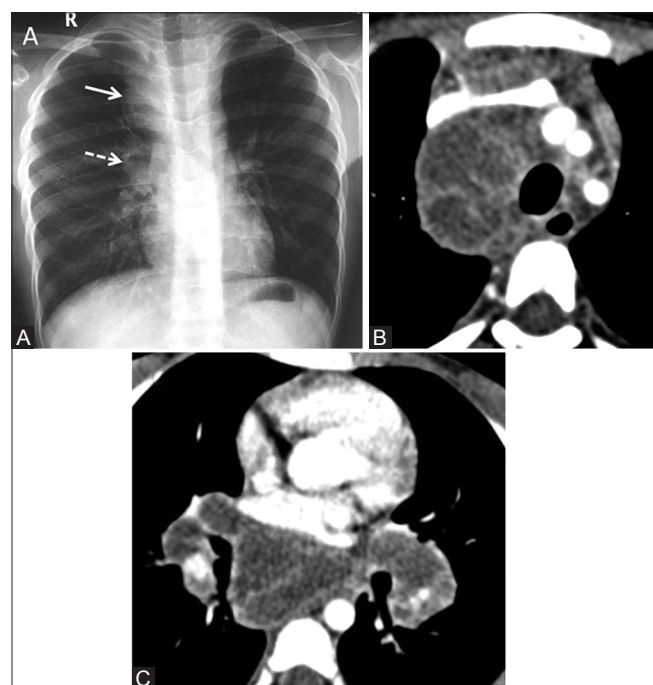


Figure 2 (A-C): Tuberculosis: Typical mediastinal lymphadenopathy. (A) Chest X-ray (CXR) showing right paratracheal (solid arrow) and unilateral right hilar lymphadenopathy (dashed arrow) without parenchymal abnormality. (B and C) Axial images of CECT chest (mediastinal window in another patient) show necrotic conglomerate lymph nodes in right paratracheal, bilateral hilar and subcarinal region with obscuration of perinodal fat showing "rim enhancement." Note asymmetrical involvement of bilateral hilar lymph nodes

Table 3: Differentiating features in pattern of mediastinal lymphadenopathy in sarcoidosis and TB

Features	Sarcoidosis	Tuberculosis
Distribution		
Nodal Sites	Hilar Right paratracheal APW*	Right paratracheal Hilar Subcarinal/Mediastinal LN†
Unilateral/Bilateral involvement	Usually bilateral, symmetrical Unilateral <8% More common on right side	Usually unilateral Bilateral ~31%, asymmetrical
Morphology		
Margin	Sharp and discrete	Conglomerate Obscured perinodal fat
Enhancement pattern	Homogeneous "Cluster of black pearls"	Rim enhancement Heterogeneous
Calcification	Focal Bilateral hilar lymph node calcification	Complete Unilateral hilar lymph node calcification
Diffusion weighted MR	ADC‡ value in lymphoma group significantly lower than in sarcoidosis. Cut-off ADC - $1.266 \times 10^{-3} \text{ mm}^2/\text{s}$, sensitivity (100%), specificity (81%). No discriminatory pattern between sarcoid and tuberculous LN ^[22]	

*APW: Aortopulmonary window, †LN: Lymphadenopathy, ‡ADC: Apparent diffusion coefficient

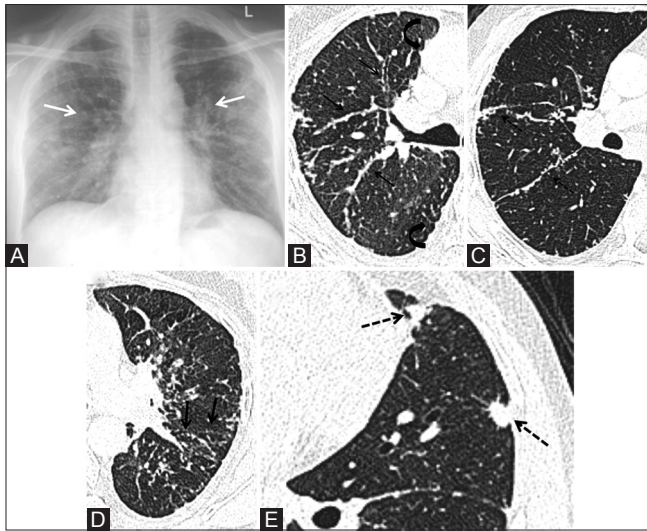


Figure 3 (A-E): Sarcoidosis: Parenchymal nodules. (A) Chest X-ray (CXR) showing bilateral perihilar interstitial nodules, predominantly in upper and mid zones (white arrows). (B, C) Magnified axial high resolution computed tomography (HRCT) images (lung window) in another patient shows typical perilymphatic distribution of micronodules. Discrete rounded well-defined micronodules seen along right bronchovascular bundle (thin arrow), subpleural interstitium (curved arrow), and interlobar fissure (dashed arrows). (D) Magnified axial HRCT image (at lower level) shows sharply defined micronodules along left interlobular septa (thick arrows) (E) sarcoid macronodules. Magnified axial HRCT image (lung window) showing macronodules with irregular margins and multiple peripheral micronodules in left upper lobe representative of coalescent granulomas (dashed arrows). Note discrete perilymphatic nodules along left interlobar fissure

Larger nodules and masses occur in about 15–25% of patients of active sarcoidosis and represent coalescence of interstitial granulomas^[23] These lesions usually tend to be multiple and bilateral [Figure 4]. Sometimes, multiple well-defined macronodules (measuring more than 5 mm in diameter) may be seen distributed randomly in bilateral lung parenchyma mimicking metastases.^[24]

A number of signs have been described in parenchymal opacities seen in sarcoidosis. The most commonly cited of them is the “galaxy sign” which is used to describe the appearance of nodules and patchy consolidation with multiple satellite nodules at the periphery [Figure 5A].^[25] Another sign described on high-resolution chest CT (HRCT) is “sarcoid cluster” sign which consists of multiple clusters of micronodules in perilymphatic distribution, especially in subpleural location of upper and mid-zones of lung [Figure 5B].^[26] Recently; however, perilymphatic micronodules, galaxy, and cluster sign have also been described in adult TB representing lymphatic dissemination of disease [Figure 6].^[27]

Consolidation and ground glass opacity

The consolidation is more frequent in TB^[18] [Figure 7] but may be seen in 10–20% cases of sarcoidosis [Figure 4].^[23] The distribution of parenchymal consolidation amongst the two entities is; however, distinct as highlighted in Table 4. Sarcoidosis presenting as confluent patches of consolidation

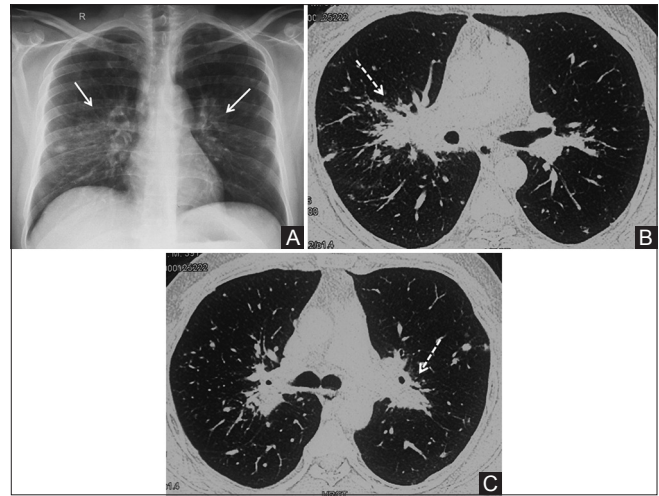


Figure 4 (A-C): Sarcoidosis: Parenchymal masses (A) Chest X-ray (CXR) shows bilateral parahilar ill-defined consolidation (right more than left) (white arrow). Multiple separate well-defined discrete nodules seen in bilateral upper and mid zone. (B and C) Axial CT image (lung window) shows bilateral confluent parahilar masses extending to upper lobes (dashed arrows). Multiple discrete perilymphatic and random nodules seen in bilateral lung parenchyma

with or without air-bronchogram with an ill-defined margin representing the coalescent nodules is known as “alveolar or acinar pattern” of sarcoidosis [Figure 8A] and represents an acute manifestation of the disease with the radiographic abnormalities invariably showing resolution with or without steroid treatment. Other possible differential diagnosis of this appearance includes pneumonia, TB, and cryptogenic organizing pneumonia.

The pattern described on HRCT consists of central rounded area of ground glass attenuation surrounded by peripheral rim of dense consolidation. Sarcoidosis is included in the list of entities which can show this sig^[28] apart from infectious and noninfectious diseases such as cryptogenic organizing pneumonitis, mucormycosis, granulomatous polyangiitis (GPA) and has recently been described in TB. Marlow TJ *et al.* also described “fairy ring sign” in alveolar sarcoidosis akin to “reverse halo sign” consisting of central areas of normally aerated lung with peripheral consolidation^[29]

Ground glass opacity has been recognized as an unusual manifestation of pulmonary sarcoidosis and both patchy peribronchovascular distribution and diffuse forms have been described [Figure 8B and C]. The pattern is rarely seen in isolation and is usually accompanied by other parenchymal changes.^[23]

Atypical manifestations of sarcoidosis include diffuse miliary distribution of nodules [Figure 8D].^[30] predominantly lower zone distribution of parenchymal lesions^[31] [Figure 8E and F] and asymmetrical unilateral involvement [Figure 8G]. Table 4 enlists the differentiating parenchymal changes of the two entities.

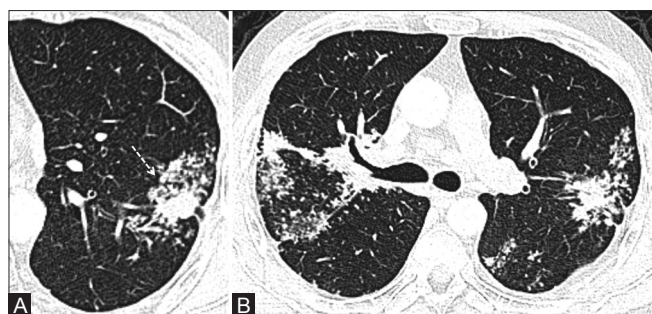


Figure 5 (A and B): Sarcoidosis: Galaxy sign and cluster sign. (C) Magnified axial high resolution computed tomography (HRCT) image (lung window) shows macronodule with irregular margins (dashed arrow) due to presence of multiple small micronodules at the periphery representing coalescent lesion referred to as “sarcoid galaxy sign” (B) Axial HRCT image (lung window) in the same patient (at different level) shows multiple clusters of micronodules in perilymphatic distribution bilaterally suggestive of “sarcoid cluster” sign

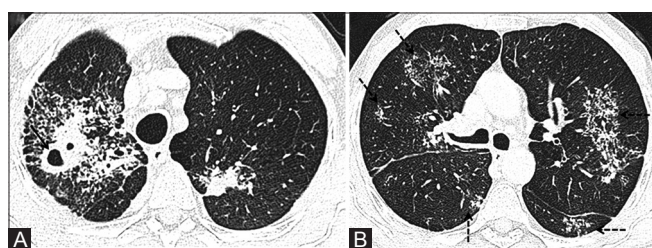


Figure 6 (A and B): Tuberculosis with perilymphatic nodules and cluster sign. 36-year old man with fever, cough and progressive weight loss for 5 months. GeneXpert MTB from bronchoalveolar lavage (BAL) fluid was positive. (A) Axial high resolution computed tomography (HRCT) image shows thick-walled cavity with adjacent consolidation in right upper lobe (black arrow). Multiple adjacent coalescent ill-defined air-space nodules are noted. Smaller area of consolidation also noted in left upper lobe. (B) Axial HRCT image (at lower level) shows multiple clusters of discrete micronodules bilaterally along with nodular thickening of right major fissure suggestive of lymphatic spread (dashed arrows)

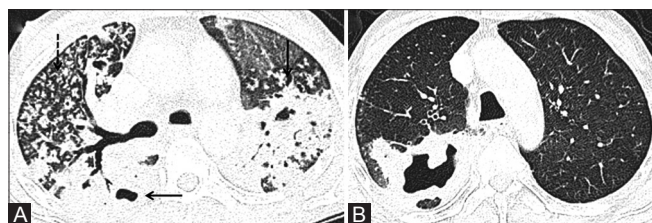


Figure 7 (A and B): Tuberculosis (TB): Parenchymal consolidation (A) Axial high resolution computed tomography (HRCT) image (lung window) in a patient of active TB shows bilateral asymmetrical consolidation involving upper lobes and superior segment of right lower lobe with internal cavitation (solid arrows). Multiple scattered centrilobular nodules seen in remaining lung parenchyma in right upper lobe (dashed arrow). (B) Axial HRCT image (lung window) in a different patient shows thick walled cavity with adjacent consolidation in right upper lobe

Fibrotic changes

Fibrotic changes in sarcoidosis can have variable appearance as detailed in Table 5 [Figure 9]. With progressive disease, fibrotic cysts including honeycomb-like cysts, bullae, and paracicatricialempysematous changes may develop, mainly in parahilar locations following the large airways^[23] while honeycombing is usually appreciated in subpleural

location of upper and mid-lung zones [Figure 10]. Abehsera M *et al.* recognized three CT patterns of pulmonary fibrosis-bronchial distortion (central), peripheral honeycombing, and diffuse linear opacities; of these linear and distorted patterns were associated with active nodules suggesting possible benefit from steroid treatment in this subgroup of stage 4 sarcoidosis.^[32]

The confluent masses consisting of fibrous tissue in peribronchovascular distribution may form, usually in perihilar locations.^[23] These lesions also tend to be bilateral, involving upper and mid zones [Figure 9]. The morphology of these lesions closely resembles progressive massive fibrosis seen in conditions like silicosis, TB, talcosis, and berylliosis^[23] Healed TB may also present with upper lobe predominant fibro-parenchymal changes; however, unlike sarcoidosis, they tend to be asymmetrical [Figure 11].

Honeycombing like changes are infrequently seen in TB and when associated with bilateral and symmetrical parahilar fibrotic masses are more suggestive of sarcoidosis.

Cavitation

The parenchymal lesions in sarcoidosis may rarely undergo cavitation. It is seen in less than 3% cases of parenchymal nodules and masses, about 10% of patients with advanced disease and extensive parenchymal fibrosis may show cavitation [Figure 7].^[33] Cavitory changes, on the other hand are frequently encountered in TB, both in active stage (post-primary TB) as well as healed lesion.

Mycetoma

Cavitory lesions in advanced sarcoidosis provide a favorable environment for saprophytic colonization by fungi, especially of *Aspergillus* species. Seen in about 1–3% cases of pulmonary sarcoidosis, mycetoma formation is seen more often in advanced stages of disease.^[34] Cavities in both the diseases may get secondarily infected, showing thick irregular walls with internal air-fluid levels. New-onset pleural thickening adjacent to the cavitory lesion may be seen prior to the appearance of fungal ball.^[35] Since cavitation is more common in TB, its attendant complications are also more frequently encountered in the latter.

Airway involvement

The airway involvement in sarcoidosis/TB may be categorized as small or large airway predominant disease.

Large airway predominant disease

Large airway involvement is more often seen in fibrotic stage of sarcoidosis and portends poor prognosis. The manifestations can range from bronchial stenosis, narrowing, or distortion due to parenchymal fibrosis. Extrinsic compression from mediastinal and hilar lymphadenopathy can also lead to symptomatic narrowing of bronchi [Figure 12A]. Bronchial stenosis can result from

Table 4: Distinguishing imaging features in parenchymal changes of sarcoidosis and tuberculosis (TB)

Sr. no	Parenchymal changes	Sarcoidosis	Tuberculosis
1	Parenchymal nodules		
	Perilymphatic	More common	Less common
	Centrilobular	Rare/infrequent	More common
	Random (miliary)	Rare	Common
	Large nodules	Common	Common
2	Consolidation	Less common	More common
		Upper and mid-zones	Apicoposterior segment of UL, superior segment of LL
		Peribronchovascular distribution	Usually unilateral, asymmetric if bilateral
		Usually bilateral and symmetrical	
3	Parahilar mass-like lesions	More common	Less common
		Bilateral and symmetrical	Asymmetrical when bilateral
4	Fibrotic changes	Central (bronchial) distortion	Central (bronchial) distortion common
		Peripheral honeycombing	Peripheral honeycombing rare
		Diffuse reticular opacities	Irregular and thick septal thickening
4	Cavitary changes	Rare	Frequent
			Thick walled with surrounding consolidation in active disease

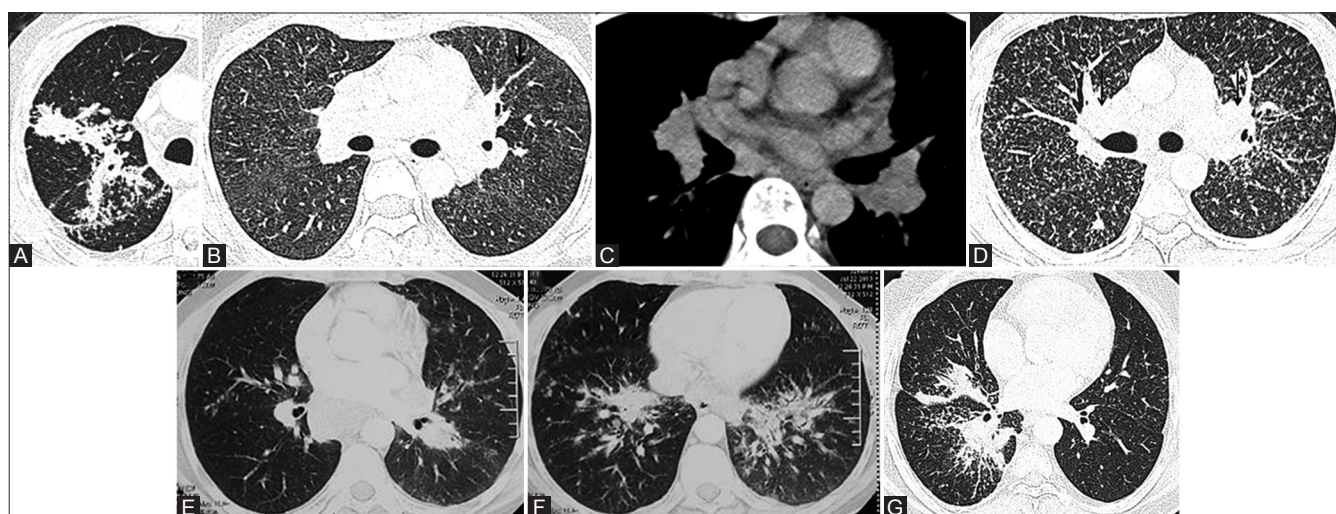


Figure 8 (A-G): Sarcoidosis with atypical manifestations. (A) Alveolar sarcoidosis: Magnified axial high resolution computed tomography (HRCT) image (lung window) shows ill-defined patchy consolidation in right upper lobe with multiple satellite nodules at the periphery-alveolar or acinar sarcoidosis. Note discrete perilymphatic nodules along right major fissure. (B and C) Sarcoidosis with GGO. (B) Axial HRCT image (lung window) in a patient with sarcoidosis showing diffuse areas of GGO bilaterally. Note nodular thickening of bronchovascular interstitium in left upper lobe (black arrow). (C) Axial CT image (mediastinal window) of the same patient showing discrete homogeneous bilateral hilar lymphadenopathy. (D) Sarcoidosis with miliary nodules. Axial HRCT image (lung window) in a patient with sarcoidosis shows multiple discrete nodules randomly distributed in bilateral lung parenchyma. Note bilateral hilar lymphadenopathy (black arrow). (E and F) Sarcoidosis with lower lobe predominance. Axial CT image (lung window) showing perilymphatic nodules and confluent perihilar masses with predominant lower lobe involvement bilaterally. (G) Sarcoidosis with asymmetric involvement. Axial HRCT image (lung window) in a patient with sarcoidosis shows perilymphatic micronodules and coalescent masses involving right lung

development of submucosal granulomas as well-leading to nodular bronchial wall thickening [Figure 12B and C]. The end result is distal obstructive atelectasis.^[23]

However, involvement of large airways is more frequently seen in TB, even in acute phase. Common manifestations in acute stage include smooth or irregular long-segment wall thickening of bronchi causing stenosis, endobronchial polypoid mass, or peribronchial cuff of soft tissue^[36] In addition to extrinsic compression, erosion of LN into airways may also be seen.^[36] Chronic stages may present with bronchial stenosis, predominantly involving the left main bronchus, bronchiectasis in apical and posterior

segments of bilateral upper lobes, broncholithiasis and bronchocele.^[37]

Small airway predominant disease

This includes findings of air trapping and mosaic attenuation on CT which are commonly seen in sarcoidosis patients. In sarcoidosis, it most often implies involvement of small airways by granulomas or fibrosis. Since, this pattern is non-specific in terms of its etiology as it may be seen in interstitial lung disease, small airway disease, and vascular pathology.^[38] Involvement of small airways in TB manifests as infectious bronchiolitis with centrilobular nodules along the bronchus and focal areas of air trapping;

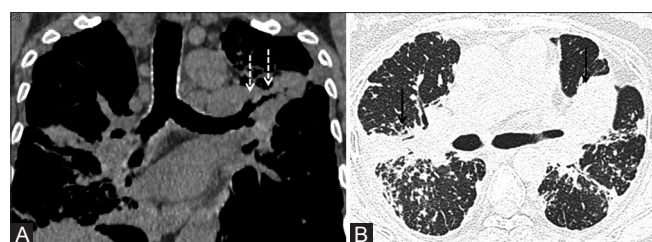


Figure 9 (A and B): Sarcoidosis: Parenchymal fibrotic changes. (A) Coronal reformatted CT image (mediastinal window) and (B) axial high resolution computed tomography (HRCT) image (lung window) in a patient with sarcoidosis shows bilateral confluent parahilar fibrotic masses extending to upper lobes (solid arrows). Note volume loss in left upper lobe with pulled-up left upper lobe bronchus (dashed arrows)

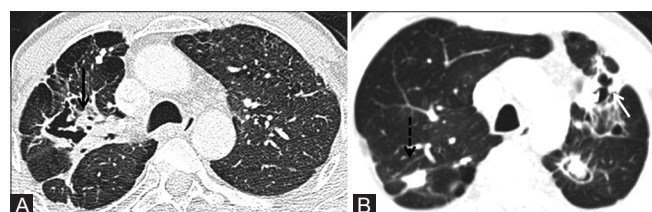


Figure 11 (A and B): Tuberculosis (TB): Fibrotic changes: (A) Axial high resolution computed tomography (HRCT) image (lung window) in a patient with healed TB shows unilateral fibroparenchymal changes with cavitation in right upper lobe (black arrow). (B) Axial CT image (lung window) in another patient shows asymmetric bilateral upper lobe involvement with parenchymal calcification (dashed arrow) and cavitation (white arrow) in another patient

Table 5: Parenchymal manifestations of sarcoidosis in active and fibrotic stages

Active disease	Fibrotic sequelae
Perilymphatic nodules	Traction bronchiectasis and bronchioectasis
Micronodules and macronodules	
Parenchymal consolidation	Reticular opacities
Ground glass opacity	Architectural distortion
	Cysts, bullae, and paracatricial emphysema
	Volume loss and tracheal displacement
	Cavity with mycetoma
	Secondary pulmonary arterial hypertension

however, diffuse air trapping with obliterative bronchiolitis is described as a sequelae of TB.^[18,36]

Pleural disease

Development of pleural effusion was considered a rare manifestation of thoracic sarcoidosis.^[39] However, it is no longer considered uncommon with increased recognition by use of CT scan (41%) compared to chest radiography (5–10%).^[39] Pleural manifestations include pleural effusion, chylothorax, pneumothorax, pleural thickening, and pleural calcification [Figure 13]^[23] Pleural effusions usually tend to be mild and generally resolve within 2–3 months regardless of treatment. Unilateral free pleural effusion or empyema; however, is frequently encountered in TB, representing active disease while isolated pleural thickening with or without calcification indicates healed TB.^[18]

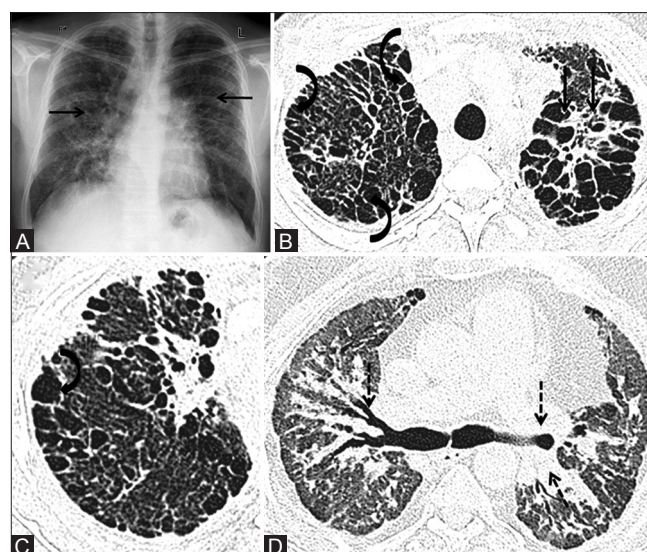


Figure 10 (A-D): Sarcoidosis with fibrocystic changes (A) Chest X-ray (CXR) of patient with sarcoidosis shows bilateral parahilar fibrotic opacities extending preferentially to upper and mid zones (black arrows). (B) Axial high resolution computed tomography (HRCT) image (lung window) in another patient shows peripheral subpleural honeycombing in bilateral upper lobes (curved arrows) alongwith fibrocystic changes in left upper lobe (solid arrows). (C) Magnified view of right hemithorax showing honeycombing with layering of cysts (curved arrow). (D) Axial HRCT image (lung window) in another patient shows parahilar fibrotic changes with bilateral central bronchial distortion and bronchiectasis (dashed arrows)

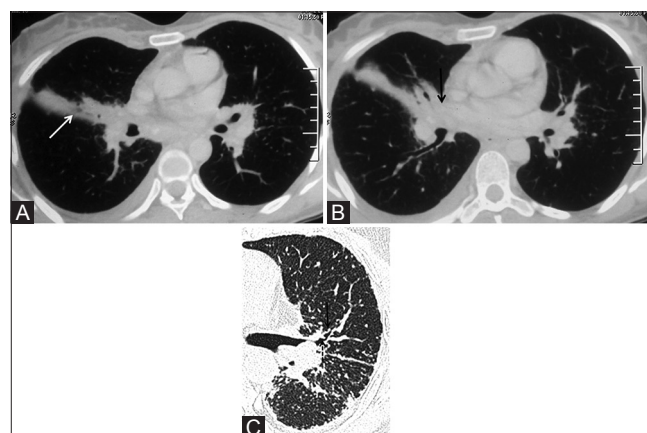


Figure 12 (A-C): Airway involvement in sarcoidosis. (A) Axial CT lung window image in a known case of sarcoidosis shows segmental atelectasis in right middle lobe (white arrow) likely due to compression on right middle lobe bronchus by right hilar lymphadenopathy (B) (black arrow). (C) Magnified axial high resolution computed tomography (HRCT) image in a different patient with pulmonary parenchymal sarcoidosis shows irregularity due to nodules along the walls of left upper lobe bronchus (thin arrow) and an endobronchial rounded nodule (dashed arrow) suggesting bronchial involvement by sarcoid granulomas. Rest of the lung shows subpleural and fissural micronodules

Some authors have found discrepancy between pleural fluid total protein and lactate dehydrogenase levels as being characteristic of sarcoid pleural effusion^[40] while others have documented similar characteristics of sarcoid and tuberculous pleural effusion, further adding to the dilemma in endemic countries. A definitive diagnosis can

be established by pleural biopsy with microbiological evaluation. Further, development of pleural effusion while on steroid therapy may; however, indicate superadded infection.^[41]

Pneumothorax usually occurs as a result of either rupture of an apical emphysematous bulla or by gradual necrosis of a subpleural sarcoid granuloma—conditions seen in advanced fibrotic stages of sarcoidosis.^[39] In addition, pleural plaque-like opacities seen in sarcoidosis are formed by coalescence of multiple subpleural micro-nodules/granulomas. However, such pleural opacities are not exclusive to sarcoidosis and may be seen in other conditions especially active TB and fibrosing pneumoconiosis.^[39]

Tuberculous Sarcoidosis or Tuberculosis and Sarcoidosis?

The association between TB and sarcoidosis has been extensively studied and uniformly acknowledged. Various molecular genetic and immunological assays have postulated the possible etiological role of *MTB* (in the development of sarcoidosis) as the underlying antigenic trigger to elicit T-cell response in a genetically predisposed individual^[42,43] This probably explains the higher incidence of sarcoidosis in TB-endemic regions and confounds the inability of available serological and molecular tests to confidently differentiate between the two diseases.^[44]

Scadding introduced the term “tuberculous sarcoidosis” in 1960 to segregate the category of patients who presented with overlapping clinical and pathological features of sarcoidosis and TB.^[45] However, with the growing knowledge about the variable pathological as well as clinical manifestations of both TB and sarcoidosis, it is now believed

that the entity “tuberculous sarcoidosis” may actually be a misnomer and rather redundant^[44] as sarcoidosis is known to co-exist, precede or follow TB^[45,46] and TB, on the other hand, may reactivate following treatment of sarcoidosis with corticosteroids due to its immunosuppressive effects [Figure 14].^[47]

Based on extensive studies into the humoral and cell-mediated immune responses in sarcoid and TB patients, some authors have hypothesized that the two entities are not mutually exclusive, but rather represent polar forms of the same disease spectrum based on the host immune response^[48] Expanding on the same proposition, Rupesh A *et al.* proposed a classification system for sarcoidosis and TB consisting of four categories: sarcoidosis (S), sarcoid-tuberculous (ST), tuberculous-sarcoid (TS), and TB^[48] The radiological correlate of this subdivision is rather clear on the two ends of the spectrum representing pure forms of the disease, i.e. bilateral symmetrical mediastinal lymphadenopathy and perilymphatic nodules in sarcoidosis (S) and cavitation with tree-in-bud nodules in tuberculosis (T). The “grey zones” consisting of ST and TS categories have been assigned overlapping imaging features of “primarily

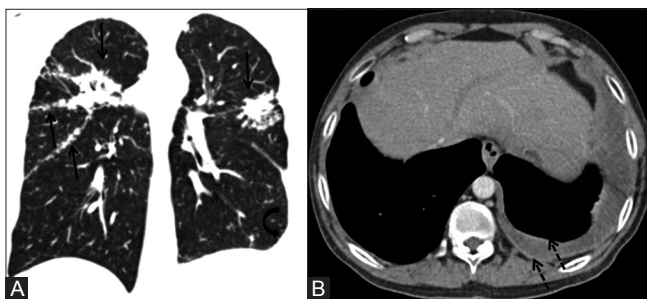


Figure 13 (A and B): Sarcoidosis with pleural involvement. (A) Coronal multiplanar reconstruction (MPR) image (lung window) of a patient with sarcoidosis shows typical perilymphatic nodules along interlobar fissures and subpleural interstitium with upper lobe predominance (black arrows). Note left sided pleural effusion (curved arrow) (B) Axial contrast-enhanced CT (CECT) image (mediastinal window) shows left-sided pleural effusion with mild pleural thickening and enhancement (dashed arrows). Pleural fluid analysis revealed low adenosine deaminase (ADA) level. Pleural biopsy was performed which showed non-necrotizing granuloma. The effusion subsequently resolved on treatment

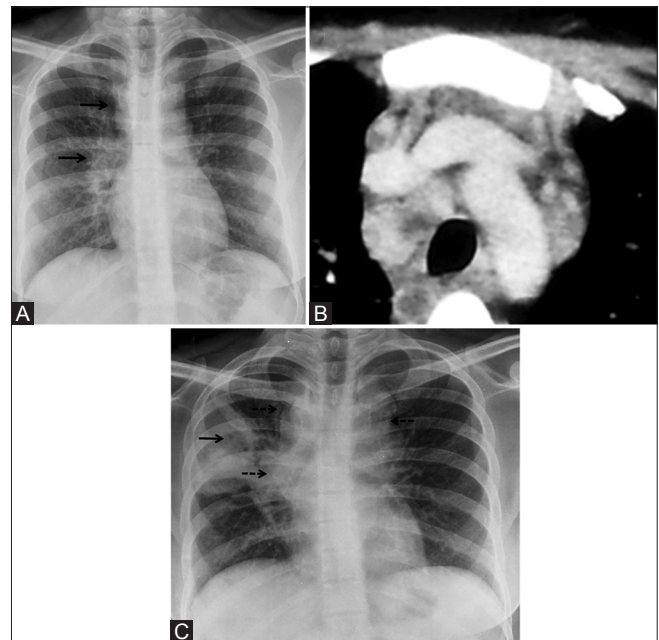


Figure 14 (A-C): 24-year old female presented with non-specific fever and breathlessness. (A) Chest X-ray (CXR) showed presence of right paratracheal and right hilar lymphadenopathy (black arrows). (B) Coned down axial contrast-enhanced CT (CECT) chest (mediastinal window) image showed discrete homogeneous pretracheal, right paratracheal, and prevascular lymphadenopathy. On lung window, there were perilymphatic nodules (not shown)—radiologically consistent with sarcoidosis. Patient was started on steroids. Three months later, she deteriorated with onset of productive cough and increasing breathlessness. (C) CXR revealed new-onset consolidation in right upper lobe with air bronchogram and cavitation (solid arrow) and increase in mediastinal and hilar lymphadenopathy (broken arrows). Sputum *acid fast bacilli* came out to be positive. Subsequently, anti-tubercular therapy was started following which she improved (not shown)

Table 6: Imaging features to suggest concurrent TB in a patient of sarcoidosis

Sr. no	Imaging features
1	Unilateral pleural effusion, especially with loculations, pleural thickening, and enhancement
2	Central necrosis within mediastinal lymph nodes
3	Focal consolidation especially with cavitation
4	Centrilobular nodules in a segmental distribution

lymphadenopathy” without any distinguishing features. While the treatment regimens of the two polar forms are well established, the prognostic implication of this classification system lies in the importance to recognize the “overlapping categories” which may benefit from a combination of immunosuppressants and anti-tubercular therapy instead of individual regimen.

The authors, hereby, propose the following imaging features which may suggest concurrent TB in a patient of sarcoidosis or alert the physician to the possibility of “grey zone” categories [Table 6].

In conclusion, the dilemma of excluding TB in a suspected patient of sarcoidosis or differentiating between the two entities continues to be a clinical and diagnostic challenge. Part 2 of this review addresses the current role of various imaging modalities in this context.

Financial support and sponsorship
Nil.

Conflicts of interest

There are no conflicts of interest.

References

- Miller BH, Rosado-de-Christenson ML, McAdams HP, Fishback NF. Thoracic sarcoidosis: Radiologic-pathologic correlation. *Radiographics* 1995;15:421-37.
- Pietinalho A, Hiraga Y, Hosoda Y, Lofroos AB, Yamaguchi M, Selroos O. The frequency of sarcoidosis in Finland and Hokkaido, Japan. A comparative epidemiological study. *Sarcoidosis* 1995;12:61-7.
- Rybicki BA, Major M, Popovich J Jr, Maliarik MJ, Iannuzzi MC. Racial differences in sarcoidosis incidence: A 5-year study in a health maintenance organization. *Am J Epidemiol* 1997;145:234-41.
- Gupta SK. Epidemiology of sarcoidosis. *Proceedings of the symposium Delhi: VP Chest Institute* 2002;27-31.
- Sharma SK, Mohan A. Sarcoidosis in India: Not so rare. *J Indian Acad Clin Med* 2004;3:12-21.
- WHO Global tuberculosis report. Available from www.who.int/tb/publications/global_report. 2016.
- Jindal SK, Gupta D, Aggarwal AN. Sarcoidosis in developing countries. *Curr Opin Pulm Med* 2000;6:448-54.
- Statement on sarcoidosis. Joint Statement of the American Thoracic Society (ATS), the European Respiratory Society (ERS) and the World Association of Sarcoidosis and Other Granulomatous Disorders (WASOG) adopted by the ATS Board of Directors and by the ERS Executive Committee, February 1999. *Am J Respir Crit Care Med* 1999;160:736-55.
- Bechtel JJ, Starr T 3rd, Dantzker DR, Bower JS. Airway hyperreactivity in patients with sarcoidosis. *Am Rev Respir Dis* 1981;124:759-61.
- Chang JC, Driver AG, Townsend CA, Kataria YP. Hemoptysis in sarcoidosis. *Sarcoidosis* 1987;4:49-54.
- Gupta D, Kumar S, Aggarwal AN, Verma I, Agarwal R. Interferon gamma release assay (QuantiFERON-TB Gold In Tube) in patients of sarcoidosis from a population with high prevalence of tuberculosis infection. *Sarcoidosis Vasc Diffuse Lung Dis* 2011;28:95-101.
- Bedi G, Bedi R. Diagnosing sarcoidosis: What is the value of A.C.E ? *Lung India* 2004;21:39-40.
- Ainslie GM, Benatar SR. Serum angiotensin converting enzyme in sarcoidosis: Sensitivity and specificity in diagnosis: Correlations with disease activity, duration, extra-thoracic involvement, radiographic type and therapy. *Q J Med* 1985;55:253-70.
- Studdy PR, Bird R, Neville E, James DG. Biochemical findings in sarcoidosis. *J Clin Pathol* 1980;33:528-33.
- Khan AH, Ghani F, Khan A, Khan MA, Khurshid M. Role of serum angiotensin converting enzyme in sarcoidosis. *J Pak Med Assoc* 1998;48:131-3.
- So E, Bolger DT Jr. Hypercalcaemia: Atypical presentation of miliary tuberculosis. *BMJ Case Rep* 2014;2014.
- Iliaz S, Iliaz R, Ortakoylu G, Bahadir A, Bagci BA, Caglar E. Value of neutrophil/lymphocyte ratio in the differential diagnosis of sarcoidosis and tuberculosis. *Ann Thorac Med* 2014;9:232-5.
- Bhalla AS, Goyal A, Guleria R, Gupta AK. Chest tuberculosis: Radiological review and imaging recommendations. *Indian J Radiol Imaging* 2015;25:213-25.
- Venkata Ramanan R, Pudhiavan A, Venkataramanan A. The “cluster of black pearls” sign of sarcoid lymphadenopathy: A new sign on thin-section contrast-enhanced multidetector CT. *Clin Radiol* 2017;72:729-36.
- Park HJ, Jung JI, Chung MH, Song SW, Kim HL, Baik JH, *et al.* Typical and atypical manifestations of intrathoracic sarcoidosis. *Korean J Radiol* 2009;10:623-31.
- Gross BH, Schneider HJ, Proto AV. Eggshell calcification of lymph nodes: An update. *AJR Am J Roentgenol* 1980;135:1265-8.
- Gumustas S, Inan N, Akansel G, Basyigit I, Ciftci E. Differentiation of lymphoma versus sarcoidosis in the setting of mediastinal-hilar lymphadenopathy: Assessment with diffusion-weighted MR imaging. *Sarcoidosis Vasc Diffuse Lung Dis* 2013;30:52-9.
- Criado E, Sanchez M, Ramirez J, Arguis P, de Caralt TM, Perea RJ, *et al.* Pulmonary sarcoidosis: Typical and atypical manifestations at high-resolution CT with pathologic correlation. *Radiographics* 2010;30:1567-86.
- Hansell DM, Bankier AA, MacMahon H, McLoud TC, Muller NL, Remy J. Fleischner Society: Glossary of terms for thoracic imaging. *Radiology* 2008;246:697-722.
- Nakatsu M, Hatabu H, Morikawa K, Uematsu H, Ohno Y, Nishimura K, *et al.* Large coalescent parenchymal nodules in pulmonary sarcoidosis: “Sarcoid galaxy” sign. *AJR Am J Roentgenol* 2002;178:1389-93.
- Herraez Ortega I, Alonso Orcajo N, Lopez Gonzalez L. The “sarcoid cluster sign”. A new sign in high resolution chest CT. *Radiologia* 2009;51:495-9.
- Ko JM, Park HJ, Kim CH. Clinoradiologic evidence of pulmonary lymphatic spread in adult patients with tuberculosis. *AJR Am J Roentgenol* 2015;204:38-43.
- Kumazoe H, Matsunaga K, Nagata N, Komori M, Wakamatsu K, Kajiki A, *et al.* “Reversed halo sign” of high-resolution computed tomography in pulmonary sarcoidosis. *J Thorac Imaging* 2009;24:66-8.

29. Marlow TJ, Krapiva PI, Schabel SI, Judson MA. The "fairy ring": A new radiographic finding in sarcoidosis. *Chest* 1999;115:275-6.
30. Wells A. High resolution computed tomography in sarcoidosis: A clinical perspective. *Sarcoidosis Vasc Diffuse Lung Dis* 1998;15:140-6.
31. Matsui Y, Akagawa S, Masuda K, Yamato A, Ohshima N, Matsui H, *et al.* Nine cases of pulmonary sarcoidosis predominantly affecting the lower lung fields. *Nihon Kokyuki Gakkai Zasshi* 2010;48:883-91.
32. Abehsera M, Valeyre D, Grenier P, Jailliet H, Battesti JP, Brauner MW. Sarcoidosis with pulmonary fibrosis: CT patterns and correlation with pulmonary function. *AJR Am J Roentgenol* 2000;174:1751-7.
33. Hours S, Nunes H, Kambouchner M, Uzunhan Y, Brauner MW, Valeyre D, *et al.* Pulmonary cavitary sarcoidosis: Clinico-radiologic characteristics and natural history of a rare form of sarcoidosis. *Medicine (Baltimore)* 2008;87:142-51.
34. Wollschlaeger C, Khan F. Aspergillomas complicating sarcoidosis. A prospective study in 100 patients. *Chest* 1984;86:585-8.
35. Denning DW, Cadranel J, Beigelman-Aubry C, Ader F, Chakrabarti A, Blot S, *et al.* Chronic pulmonary aspergillosis: Rationale and clinical guidelines for diagnosis and management. *Eur Respir J* 2016;47:45-68.
36. Arora A, Bhalla AS, Jana M, Sharma R. Overview of airway involvement in tuberculosis. *J Med Imaging Radiat Oncol* 2013;57:576-81.
37. Conces DJ Jr, Tarver RD, Vix VA. Broncholithiasis: CT features in 15 patients. *AJR Am J Roentgenol* 1991;157:249-53.
38. Bartz RR, Stern EJ. Airways obstruction in patients with sarcoidosis: Expiratory CT scan findings. *J Thorac Imaging* 2000;15:285-9.
39. Soskel NT, Sharma OP. Pleural involvement in sarcoidosis. *Curr Opin Pulm Med* 2000;6:455-68.
40. Huggins JT, Doelken P, Sahn SA, King L, Judson MA. Pleural effusions in a series of 181 outpatients with sarcoidosis. *Chest* 2006;129:1599-604.
41. Joshi S, Periwal P, Dogra V, Talwar D. Sarcoidosis as unusual cause of massive pleural effusion. *Respir Med Case Rep* 2015;16:143-5.
42. Gazouli M, Ikonopoulou J, Trigidou R, Foteinou M, Kittas C, Gorgoulis V. Assessment of mycobacterial, propionibacterial, and human herpesvirus 8 DNA in tissues of greek patients with sarcoidosis. *J Clin Microbiol* 2002;40:3060-3.
43. Chen ES, Wahlstrom J, Song Z, Willett MH, Wiken M, Yung RC, *et al.* T cell responses to mycobacterial catalase-peroxidase profile a pathogenic antigen in systemic sarcoidosis. *J Immunol* 2008;181:8784-96.
44. Gupta D, Agarwal R, Aggarwal AN, Jindal SK. Sarcoidosis and tuberculosis: The same disease with different manifestations or similar manifestations of different disorders. *Curr Opin Pulm Med* 2012;18:506-16.
45. Scadding JG. Mycobacterium tuberculosis in the aetiology of sarcoidosis. *Br Med J* 1960;2:1617-23.
46. Tufan A, Ranci O, Sungur A, Topeli A, Haznedaroglu I, Coplu L. Concurrent presentations of the sarcoidosis, tuberculosis and lymphoma in a single patient. *Respir Med* 2006;100:951-3.
47. Scadding JG, Mitchell D. Tuberculous pleural effusion occurring during corticosteroid treatment of sarcoidosis. *Thorax* 1987;42:320.
48. Agrawal R, Kee AR, Ang L, Tun Hang Y, Gupta V, Kon OM, *et al.* Tuberculosis or sarcoidosis: Opposite ends of the same disease spectrum? *Tuberculosis (Edinb)* 2016;98:21-6.