

SAPHO syndrome: A radiological case report

Anil Kumar Singh, Rahul S Ranjan¹

Department of Radiodiagnosis, SGPGIMS, Lucknow, ¹Department of Radiodiagnosis, Rama Medical College, Mandhana, Kanpur, Uttar Pradesh, India

Correspondence: Dr. Anil Kumar Singh, Department of Radiodiagnosis, Sanjay Gandhi Postgraduate Institute of Medical Sciences, Raebareli Road, Lucknow - 226 014, Uttar Pradesh, India. E-mail: singh.anil.kr01@gmail.com

Abstract

The SAPHO syndrome (synovitis–acne–pustulosis–hyperostosis–osteitis syndrome) is a rare chronic inflammatory disease of unknown etiology. Herein, we present a case of incidentally detected SAPHO syndrome in a middle-aged male patient who visited the hospital for pulmonary complaints.

Key words: Ankylosis; arthropathy; hyperostosis, osteitis; pustulosis; synovitis–acne–pustulosis–hyperostosis–osteitis

Introduction

The SAPHO syndrome (synovitis–acne–pustulosis–hyperostosis–osteitis syndrome) is a rare chronic inflammatory disease of unknown etiology and characterized by a combination of cutaneous and osteoarticular lesions. It can mimic many other conditions, however, characteristic clinical and radiological features help to differentiate it from other conditions in most of the cases. Adequate knowledge is necessary to avoid misdiagnosis and undesired investigations. Radiology plays an important role in its diagnosis, and at times where clinical signs and symptoms are not very obvious, characteristic radiological findings can prompt diagnosis. Although the disease has a good long-term prognosis, early diagnosis is necessary for appropriate treatment to control morbidity.

Case Report

A 40-year-old male patient under evaluation for pulmonary complaints was referred to the radiology department for CT

thorax study. In addition to infective pulmonary lesions, there were unrelated abnormalities in bones as well.

CT thorax study revealed diffuse osteosclerosis, anterior longitudinal ligament (ALL) ossification, syndesmophytes, vertebral facet joint arthropathy, and ankylosis, along with the variable extent of arthropathy and ankylosis at costovertebral and costotransverse joints. The patient also had hypertrophic arthropathy at the bilateral sternoclavicular joint. Smooth periosteal thickening was noted in some of the ribs. In view of these findings, a CT study of the abdominopelvic region/lumbosacral spine was done, which revealed a similar pattern in the lumbar spine. Additionally, involvement of the bilateral sacroiliac (SI) joints with ankylosis was also seen. Moreover, there were changes consistent with chronic arthropathy at the left hip joint with joint space reduction and subchondral cysts, and hyperostosis along the acetabular margins.

This is an open access journal, and articles are distributed under the terms of the Creative Commons Attribution-NonCommercial-ShareAlike 4.0 License, which allows others to remix, tweak, and build upon the work non-commercially, as long as appropriate credit is given and the new creations are licensed under the identical terms.

For reprints contact: reprints@medknow.com

Cite this article as: Singh AK, Ranjan RS. SAPHO syndrome: A radiological case report. Indian J Radiol Imaging 2020;30:84-8.

Received: 12-Jun-2018

Revised: 28-Sep-2018

Accepted: 30-Nov-2019

Published: 30-Mar-2020

Access this article online

Quick Response Code:



Website:
www.ijri.org

DOI:
10.4103/ijri.IJRI_203_18

The patient was then questioned about any symptoms of muscle or limb or joint pains. He then volunteered about on going backache for many years. In addition, there was a history of a single, episode of acute left hip pain many years back for which he was managed conservatively. The patient in his current status had a mild limp along with dull backache. The patient also had bilateral plantar pustules. However, there was no palmar pustulosis and no acne.

Laboratory findings were nonspecific with raised ESR and WBC count. The Patient had an active pulmonary infection in the right lung and respiratory complaints, which were the primary reason for his medical consultation.

In view of the predominant sclerotic and hyperostosis pattern of bone and joint disease, and the presence of plantar pustulosis, a diagnosis of SAPHO was arrived at.

Discussion

SAPHO syndrome, which is a rare clinical entity of unexplained etiology, is characterized by osteoarticular and skin lesions in varying combinations. The term SAPHO was first coined by Chamot and coworkers in 1987 as an acronym for five frequently combined lesions, namely, synovitis, acne, pustulosis, hyperostosis, and osteitis. The aetiology of the disease remains unexplained. Some patients have been found to be HLA-B27 positive suggesting a genetic predisposition. A hypothesis suggesting low virulence microbes as a causative agent has been proposed. *Propionibacterium acnes* is the most frequent microbe isolated from bone biopsy cultures, however, it is not seen in all cases.^[1-4]

This clinical entity is usually seen in young or middle-aged individuals, with an average age of 30 to 50 years. However, it has also been reported in children and at present it can evolve at any age. Overall, males and females are almost equally affected, however, there may be a gender predilection regarding some manifestations, e.g., acne more common in males and palmoplantar pustulosis more common in females.^[4-6]

There may be a longtime interval, in range of years, between different lesions and clinical manifestations, with no fixed chronological order. Moreover, a patient may not develop all features. A variable interval has been reported between the appearance of skin and bone lesions. Usually, the time interval between the onset of skin and osteoarticular lesions is 2 years but an interval of 38 years has been recorded in the literature. Pustulosis and acne, the main dermatological manifestations, are not always present in all cases. Skin lesions may be episodic and precede or follow bone lesions. Palmoplantar pustulosis and acne have been reported in 51.7% and 15.3% of patients with SAPHO syndrome, respectively. Bone and joint abnormalities can occur even

without associated skin disease. Most patients experience pain, soft-tissue swelling, and limitation of motion referable to the involved skeletal sites. Systemic manifestations are unusual but mild fever is sometimes encountered. The erythrocyte sedimentation rate is frequently elevated. C-reactive protein may be also elevated in some cases. Other laboratory values are usually within normal limits.^[2,4,5,7]

As far as bone and joint involvement are concerned, the involvement of the sternoclavicular joint is most frequent and characteristic. Symmetric activity the sternoclavicular region with a typical "bull's head" appearance has been described on bone scintigraphy. Other bones and joints of the axial and appendicular skeleton are variably involved. When multifocal, lesions can occur either simultaneously or successively. Bone lesions are sclerotic and lytic type, with osteosclerotic/osteoproliferative lesions (periosteal and cortical thickening, sclerosis, ankylosis) being predominant in many cases. Lytic bone lesions are usually seen in the early stage of the disease, and with healing, a sclerotic appearance is produced. As the clinical course advances over a period of time, characteristic features of osteitis and hyperostosis become more obvious. Synovitis usually manifests as joint space narrowing, juxta-articular osteoporosis, and even osseous erosions. These abnormalities are well demonstrated on radiographs and even better on CT. MRI helps to detect associated acute inflammatory changes i.e., marrow edema, and synovitis. Technetium bone scan shows increased activity in involved regions, irrespective of whether symptoms are referable to involved regions. In suspected cases with cutaneous findings, and no demonstrable lesion on radiography or CT, osteoarticular lesions may be demonstrated only on bone scan or MRI.^[4,5,8]

Chronic recurrent multifocal osteomyelitis (CRMO), seen in children, is considered by many Investigators, as a pediatric variant of SAPHO with predominant appendicular skeleton involvement. Usually, a multifocal long bone disease with metaphyseal involvement, with or without skin lesions is noted. The involvement of the axial skeleton is less frequent in pediatric age group.^[4,9]

SAPHO related spine disease needs to be differentiated from seronegative spondyloarthritis (SNSA), especially ankylosing spondylitis. Typical occurrence of cutaneous lesions, the involvement of sternoclavicular joint/anterior chest wall, dominant hyperostosis/sclerosis pattern, and nonmarginal syndesmophytes which are characteristic of SAPHO, help to differentiate it from ankylosing spondylitis. Whether SAPHO a subtype of SNSA is remains debatable.^[10]

SAPHO can clinically and radiologically also resemble other diseases such as osteomyelitis/infective spondylitis, neoplastic disease (like osteosarcoma, Ewing sarcoma, Paget's disease, metastases), osteitis condensans of the

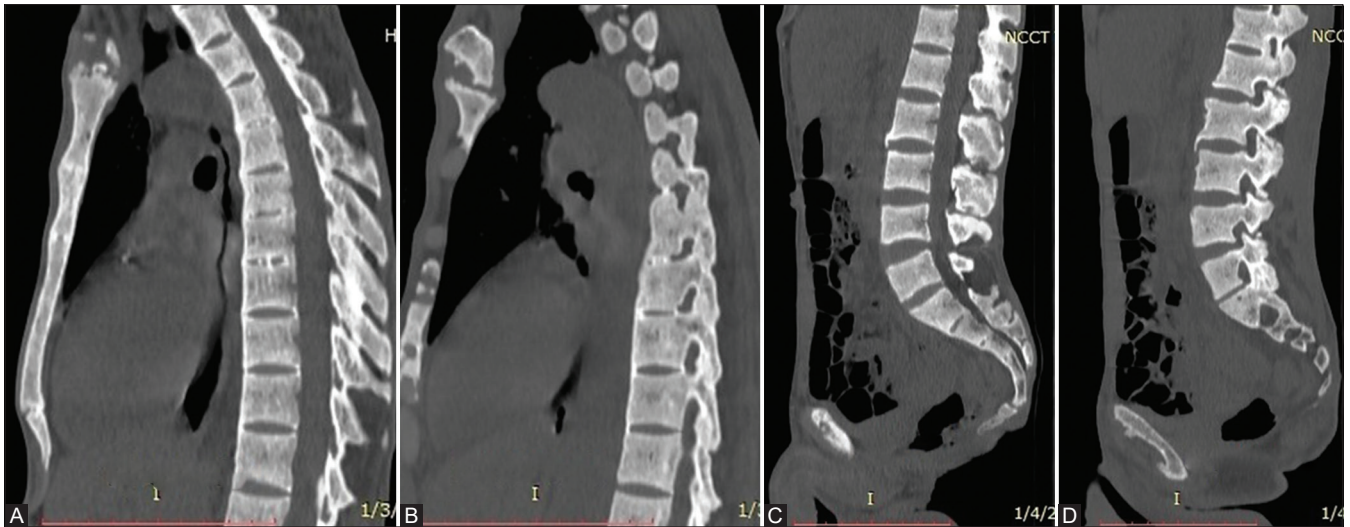


Figure 1 (A-D): (A-D) Midsagittal and parasagittal reformatted CT images of thoracic (A and B) and lumbar spine (C and D) showing diffuse osteosclerosis and facet joint arthropathy. Ossification of an anterior longitudinal ligament in the thoracic spine along with the varying degree of disc calcification. Syndesmophytes also noted in the lumbar spine

clavicle, and POEMS (polyneuropathy, organomegaly, endocrinopathy, monoclonal gammopathy, and skin changes). However, in the presence of characteristic radiological and imaging features, it is not difficult to differentiate SAPHO from these conditions. In the case of a single site involvement with no skin lesions, making the diagnosis can be difficult and biopsy may be needed. Aseptic inflammation/osteitis is one of the major characteristics of this syndrome. A biopsy is needed to exclude other diagnoses, in cases where clinical and radiological features are ambiguous.^[6,8,9]

Hence, it can be stated that SAPHO should be strongly suspected in patients with multifocal osteoarticular abnormalities, anterior chest wall pain, minimal systemic symptoms, unremarkable lab tests, and no history of other inflammatory arthropathy or primary cancer. Imaging studies have an important role to play. Though the presence of cutaneous lesions makes diagnosis easy, with proper radiological and clinical analysis, the diagnosis can be made with high confidence even in the absence of cutaneous lesions.^[7,8]

In our patient, bone and joint disease were extensive with limited cutaneous disease. Radiologically, osteoarticular disease was of predominant sclerotic/hyperostosis pattern with increased bone density, anterior longitudinal ligament (ALL) ossification, syndesmophyte formation, periosteal thickening, arthropathy and ankylosis involving joints of axial skeleton - sternoclavicular, facet, costovertebral/costotransverse and SI joints, [Figures 1A-D and 2-4], and appendicular skeleton - left hip joint [Figure 5]. Plantar pustulosis was present [Figure 6], however, no palmar pustulosis or acne. As reported in reviews and case reports in the past, skin lesions and bone/joint lesions may be seen in variable combinations and at different time spans. With

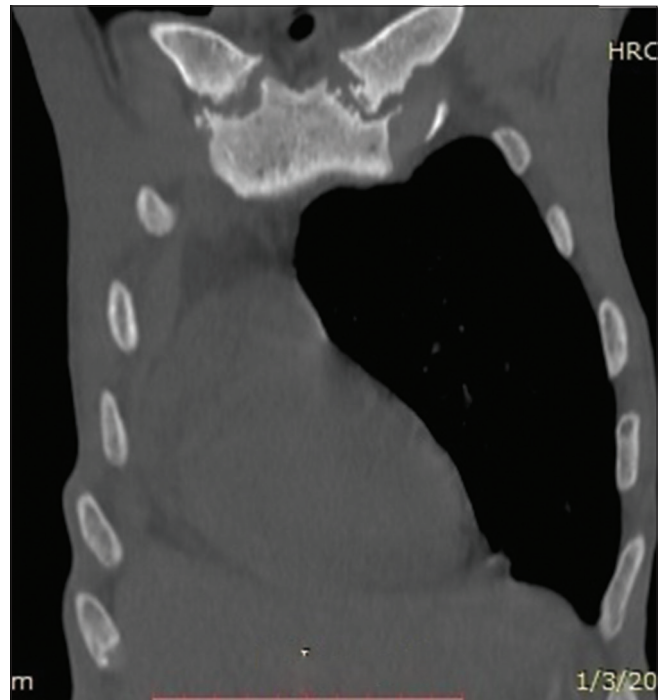

Figure 2: Coronal reformatted CT image of thorax showing osteitis and arthropathy at bilateral sternoclavicular joint

reference to musculoskeletal system, the patient had chronic dull backache and limping. Features were consistent with SAPHO syndrome.

Though the clinical presentation in our patient was relatively mild/indolent, except for one episode of acute left hip pain in the past, the radiological appearances encompassed almost the entire spectrum. Moreover, our patient belonged to the low socioeconomic group, which may account for his reluctance to seek proper care – the patient presented to our institution for pulmonary complaints only, and in addition

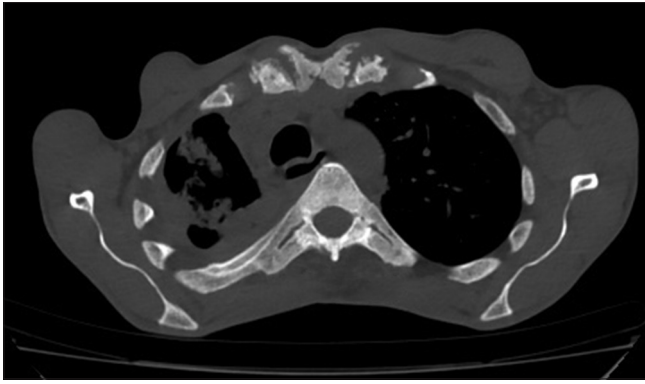


Figure 3: Axial CT image of thorax showing arthropathy with ankylosis at costotransverse and costovertebral joints. Smooth periosteal thickening in rib on the right side. Also noted osteitis and arthropathy bilateral sternoclavicular joint. Note: Right lung cavitary lesions with intracavitary fungus balls - the patient was referred for pulmonary symptoms

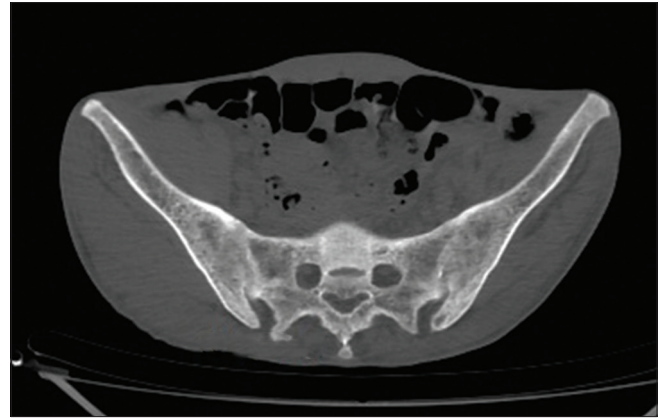


Figure 4: Axial CT image showing bilateral SI joint ankylosis

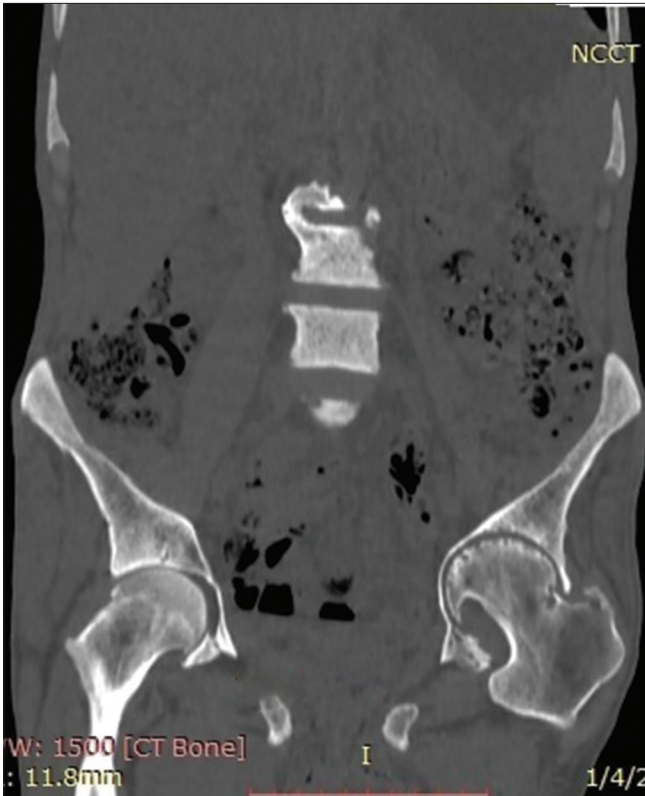

Figure 5: Coronal reformatted CT image showing left hip joint arthropathy with hyperostosis along the acetabular margin

to active pulmonary infection, was incidentally diagnosed with SAPHO syndrome.

There is no specific guideline regarding the treatment of SAPHO. NSAIDs are usually first-line treatment. Others include steroids, bisphosphonates, antirheumatic drugs, and disease-modifying agents which are less commonly used. Antibiotics are used in cases where biopsy culture is positive for *Propionibacterium acnes*. In other cases,

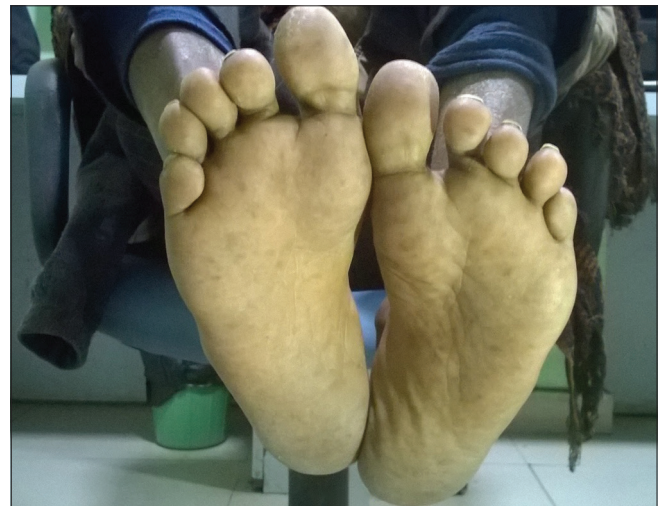

Figure 6: Photograph of patient's feet showing plantar pustulosis

antibiotics have no effect.^[7-9] Our patient was taking NSAIDs on and off as per the severity of backache which was the main symptom, apart from left lower limb limp. Although, the clinical course is prolonged, however, the long-term prognosis is known to be good.^[4,7]

Conclusion

Patients with SAPHO syndrome, especially those with absent or mild dermatological disease, may present late in course of disease with skeletal deformities. An understanding and knowledge of this entity is necessary to make early diagnosis even in those who are not overtly symptomatic and in such cases radiologists may be the first to suggest the diagnosis, and thus being helpful in the treatment and avoiding unnecessary tests.

Declaration of patient consent

The authors certify that they have obtained all appropriate patient consent forms. In the form the patient(s) has/have given his/her/their consent for his/her/their images and other clinical information to be reported in the journal. The

patients understand that their names and initials will not be published and due efforts will be made to conceal their identity, but anonymity cannot be guaranteed.

Financial support and sponsorship

Nil.

Conflicts of interest

There are no conflicts of interest.

References

1. Boutin RD, Resnick D. The SAPHO syndrome: An evolving concept for unifying several idiopathic disorders of bone and skin. *AJR Am J Roentgenol* 1998;170:585-91.
2. Davies AM, Marino AJ, Evans N, Grimer RJ, Deshmukh N, Mangham DC. SAPHO syndrome: 20-year follow-up. *Skeletal Radiol* 1999;28:159-62.
3. Matzaroglou Ch, Velissaris D, Karageorgos A, Marangos M, Panagiotopoulos E, Karanikolas M. SAPHO syndrome diagnosis and treatment: Report of five cases and review of the literature. *Open Orthop J* 2009;3:100-6.
4. Rukavina I. SAPHO syndrome: A review. *J Child Orthop* 2015;9:19-27.
5. Cotton A, Flipo RM, Mentre A, Delaporte E, Duquesnoy B, Chastanet P. SAPHO syndrome. *Radio Graphics* 1995;15:1147-54.
6. Depasquale R, Kumar N, Lalam RK, Tins BJ, Tyrrel PN, Singh J, *et al.* SAPHO: What radiologists should know. *Clin Radiol* 2012;67:195-206.
7. Zimmermann P, Curtis N. Synovitis, acne, pustulosis, hyperostosis, and osteitis (SAPHO) syndrome – A challenging diagnosis not to be missed. *J Infect* 2016;72(Suppl):S106-14.
8. Khanna L, El-Khoury GY. SAPHO syndrome – A pictorial assay. *Iowa Orthop J* 2012;32:189-95.
9. Sweeney SA, Kumar VA, Tayar J, Weber DM, Safdar A, Alonso C, *et al.* Case 181: Synovitis acne pustulosis hyperostosis osteitis (SAPHO) syndrome. *Radiology* 2012;263:613-7.
10. Takigawa T, Tanaka M, Nakanishi K, Misawa H, Sugimoto Y, Takahata T, *et al.* SAPHO syndrome associated spondylitis. *Eur Spine J* 2008;17:1391-7.