

Safety profile of adenosine stress cardiac MRI in a tertiary hospital in India

Vimal Raj, Pudhiavan A, Hrishikesh VJ, Asik Ali, Richa Kothari

Cardiothoracic Imaging Unit, Narayana Institute of Cardiac Sciences, Narayana Health City, Hosur Road, Bommasandra Industrial Estate, Bangalore, Karnataka, India

Correspondence: Dr. Vimal Raj, Cardiothoracic Imaging Unit, Narayana Institute of Cardiac Sciences, Narayana Health City, Hosur Road, Bommasandra Industrial Estate, Bangalore - 560 099, Karnataka, India. E-mail: drvimalraj@gmail.com

Abstract

Background: Coronary artery disease (CAD) is a major cause of morbidity and mortality in India. Stress Cardiac Magnetic Resonance (CMR) using vasodilator agent is well established in assessing the functional significance of CAD. Adenosine is the preferred agent, but can have severe side effects including dyspnoea, chest pain, atrioventricular block or bronchospasm. The stress CMR examination is not routinely performed in many of the clinical imaging departments in India. **Objective:** The aim of this study was to establish safety of adenosine as a pharmacological stressor agent for CMR in a tertiary care radiology department in India. **Methods:** A review of all patients undergoing stress CMR in our institution from May 2018 to May 2019 was made. Records were reviewed to collect response parameters and documented adverse reactions. **Results:** A total of 1057 patients underwent stress CMR during this period. No death, myocardial infarction or atrio-ventricular block related complications were seen. Transient hypotension was seen in 20 patients (1.8%) with spontaneous recovery after stopping infusion. Chest pain and breathlessness severe enough to discontinue the scan were seen in 6 (0.5%) and 10 (0.9%) patients, respectively. All patients with breathlessness recovered on low flow oxygen therapy with three requiring bronchodilator. Out of six patients with chest pain, three had immediate relief with sublingual nitroglycerin, and three required hospital admission for unstable angina. Of the latter three, 1 underwent revascularization on the same day and other two later in the week. **Conclusion:** Stress CMR using adenosine in appropriately selected patients is a highly safe procedure with significant side effects seen in less than 1% of patients. Therefore, it is safe to perform stress CMR studies in a fully equipped and well-trained radiology department in India.

Key words: Adenosine; cardiac MRI; coronary artery disease

Introduction

Coronary artery disease (CAD) is a major cause of morbidity and mortality in India and is expected to be the major cause of death worldwide by 2020.^[1-4] Vasodilator stress Cardiac Magnetic Resonance (CMR) imaging is highly accurate in detecting significant CAD and is very

cost-effective.^[5-7] It also has better sensitivity and negative predictive value compared to Single Photon Emission Computed Tomography (SPECT) in the detection of CAD.^[6-8] Stress CMR also has additional value in prognostication of

This is an open access journal, and articles are distributed under the terms of the Creative Commons Attribution-NonCommercial-ShareAlike 4.0 License, which allows others to remix, tweak, and build upon the work non-commercially, as long as appropriate credit is given and the new creations are licensed under the identical terms.

For reprints contact: WKHLRPMedknow_reprints@wolterskluwer.com

Cite this article as: Raj V, Pudhiavan A, Hrishikesh VJ, Ali A, Kothari R. Safety profile of adenosine stress cardiac MRI in a tertiary hospital in India. *Indian J Radiol Imaging* 2020;30:459-64.

Received: 23-Apr-2020

Revised: 17-Jun-2020

Accepted: 01-Sep-2020

Published: 13-Jan-2021

Access this article online

Quick Response Code:



Website:
www.ijri.org

DOI:
10.4103/ijri.IJRI_283_20

patients who present with chest pain syndromes and has been recommended as an appropriate test for the evaluation of symptomatic patients with intermediate to high pretest probability of CAD.^[5,9-13]

Multiple studies in western countries have shown that pharmacological vasodilator stress CMR using adenosine is a safe procedure and can be taken up in an outpatient setting.^[14-17] However, in India stress CMR is not routinely performed in many of the clinical imaging departments. Most common reason for this poor adoption is the fear of pulmonary and cardiovascular complications related to use of vasodilator agent.

This study aimed to establish the safety of adenosine as a pharmacological stressor agent for CMR in a tertiary care radiology department in India.

Vasodilator agent

Physical stress is ideal for assessment of myocardial flow reserve. Many patients can not perform adequate physical stress and it is practically difficult to adopt this in the CMR environment. Vasodilator agents, by increasing myocardial blood flow by four to five times, mimic physical stress in a controlled environment. Adenosine, regadenosine, and dipyridamole are coronary vasodilators that can be used for the assessment of myocardial perfusion. There are three adenosine receptor subtypes, A1, A2, and A3. A2 can be further subdivided into A2a and A2b. Stimulation of the A2a receptors on arterial vascular smooth muscle causes vasodilatation. Stimulation of A1, A2b, and A3 receptors may result in dyspnoea, chest pain, atrioventricular block or bronchospasm, accounting for its adverse side-effects.^[15-17] Different agents act differently in the adenosine pathway, with adenosine directly binding to multiple types of adenosine receptors and regadenoson selectively binding to A2 receptors. Dipyridamole blocks the cellular reuptake of adenosine, resulting in coronary vasodilatation with a subsequent increase in coronary flow. Regadenosine is not freely available in India and Dipyridamole has variable vasodilator capacity with a longer half-life. Adenosine, on the other hand, is widely available and has a very small half-life of less than 10 s.

Methods

A review was made of all patients, who underwent stress CMR examination in our institution between May 2018 and May 2019. The procedure was performed as per the department standard operating procedures and protocols. The study was approved by the institutional academic ethical committee (NHH/AEC-CL-2020-530). Patient hemodynamic parameters were recorded before, during and after the adenosine perfusion. Any symptoms or adverse events were recorded along with patient demographics. Patients who could not undergo CMR

(claustrophobia or non-MR compatible devices) or gadolinium-based contrast (poor renal function or known allergy) were excluded from the study. Patients who had contraindications for use of adenosine were also excluded from the study (please see below).

Stress CMR protocol

In our institution, all patients referred for stress CMR examination are first screened for the presence of contraindications to adenosine. These include severe asthma/active wheezing, acute myocardial infarction (within two weeks), severe left ventricle (LV) outflow obstruction and/or second/third-degree atrioventricular (AV) block. Patients are also screened for dipyridamole use due to its potentiating effect. A 12-lead ECG is performed before CMR to look for heart blocks. All patients are asked to abstain from coffee and other caffeine products for at least 24 hours before the scan. The CMR procedure is carefully explained to the patient before the scan, with emphasis on potential adenosine-related symptoms and informed consent obtained.

The CMR studies were performed with the patient supine, using a 3-T scanner (Ingenia, Philips Healthcare, Netherlands). Images were acquired during end-expiratory breath-hold if the patient was cooperative; otherwise, imaging was performed in free breathing. Standard imaging protocols were used.^[18,19] Cine images of long-axis views (4-chamber, 2-chamber, and 3-chamber) and outflow tract views were acquired and this was followed by stress perfusion sequences. The stress component of the study was always performed under the direct supervision of a radiologist trained in advanced cardiac life support (ACLS) accredited by the American Heart Association.

Venous access was obtained in both upper limbs, with one being used for continuous adenosine infusion and the other being used for contrast infusion at peak stress. Subjects were continuously monitored with peripheral oxygen saturation probe, heart rate, and real-time ECG throughout the CMR scan. Systemic blood pressure (BP) was recorded before starting the infusion. The BP cuff is always connected to the opposite limb of adenosine infusion to ensure uninterrupted infusion of the drug. Standard dose (140 mcg/kg/min) of adenosine infusion was started and BP was checked every minute during the infusion. Patients were asked for any symptoms during the infusion to assess for adequate hemodynamic response. Adequate hemodynamic response was said to be achieved if two or more of the following criteria were met: increase in heart rate of >10 bpm, drop in systolic (≥ 20 mm Hg) or diastolic blood pressure (≥ 10 mm Hg) or the occurrence of symptoms (shortness of breath, chest pain/discomfort and other symptoms like flushing, nausea and headache). If after 3 minutes of continuous infusion, the haemodynamic response was inadequate, then the infusion rate was

gradually increased up to a dose of 210 mcg/kg/min or until response was achieved. After the response was achieved, gadolinium contrast (0.1 mmol/kg) was injected via MR compatible injector at 4.5 ml/sec. Perfusion imaging was performed in every cardiac cycle during the first pass, using an echo-planar imaging sequence in 3 short-axis slices, positioned from the base to the apex of the LV.

The infusion was discontinued if the patient developed bradycardia, severe hypotension (systolic blood pressure <90 mmHg) or bronchospasm. Aminophylline for bronchospasm and nitroglycerine for persistent chest pain was kept readily available, and a fully equipped resuscitation trolley with a defibrillator is also kept ready within the unit.

The stress perfusion sequence was followed by cine short-axis slices without any gap for volumetric cavity assessment. Late gadolinium enhancement (LGE) imaging was performed about 10 min after the administration of contrast. Images were acquired in both short and long-axis views ensuring whole heart coverage in phase-sensitive inversion recovery sequence. Native and post-contrast myocardial T1 mapping was integrated into the routine imaging protocol. After 15 minutes of adenosine infusion, a rest perfusion was performed in selective patients.

Results

Patient characteristics

A total of 1090 patients were referred for stress CMR during the study period. Of these, 33 patients did not undergo stress CMR due to contraindications to MR and/or adenosine infusion. Of the 1057 who underwent stress CMR, 926 (88%) were men and 131 women. Mean age of the subjects was 55.5 ± 9.9 years (range 21-86 years). The clinical indications included known coronary artery disease (CAD), hypertrophic cardiomyopathy and dilated cardiomyopathy [Tables 1 and 2].

Multivessel CAD was seen in 451 patients and single-vessel CAD in 140 patients. Five patients had undergone coronary artery bypass graft (CABG). LV ejection fraction was <30% in 86 (12.2%), 50–70% in 863 (81.6%) and >70% in 108 (1.2%) patients [Table 3].

Hemodynamic response to adenosine

An increase in heart rate was seen in 983 (93%) patients and a reduction in blood pressure in 380 (36%) patients [Chart 1]. A total of 863 patients (81%) showed symptoms, with breathing difficulty being the most common symptom seen in 463 (54%) patients. This was followed by chest pain in 211 patients (24%) [Chart 2]. Table 4 depicts the hemodynamic effects of adenosine in our patients. Overall, there was a mild decrease (3–4 mmHg) in the mean systolic and diastolic blood pressure with a compensatory increase in the mean heart rate (20 beats/min). This resulted in a significant rise in rate- pressure product during stress.

Table 1: Patient demographics and clinical characteristics

Age in years- mean, range	55.5±9.9, 21-86
Gender	M=926, F=131
Body mass index (kg/m ²)	25.94±3.6
Coronary Artery Disease	1002
Dilated Cardiomyopathy	39
Hypertrophic Cardiomyopathy	3
Ischemic heart disease + Hypertrophic cardiomyopathy	13
Mean Ejection Fraction (%)	53.08±14.88

Table 2. Age and gender distribution

Age	Male	Female	Total
<31	3	8	11
31-40	6	60	66
41-50	25	217	242
51-60	44	346	390
61-70	45	247	292
>70	8	48	56

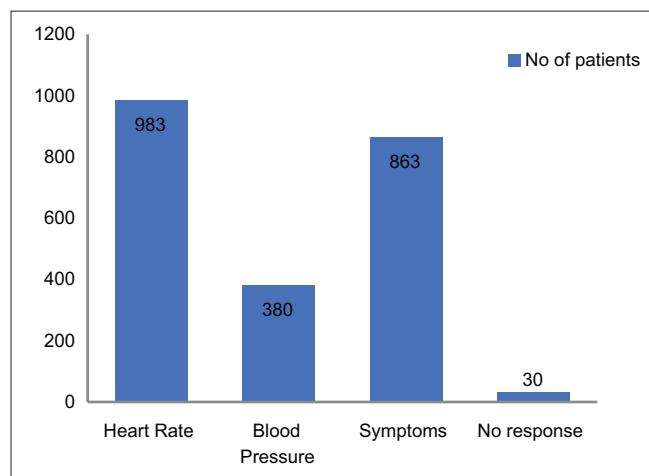


Chart 1: Hemodynamic response to adenosine

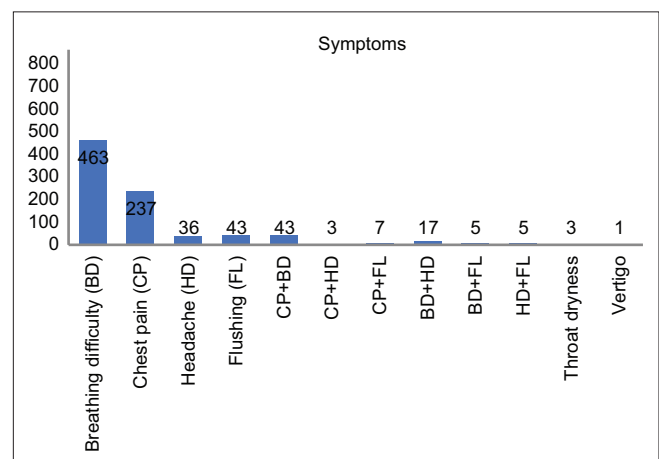


Chart 2: Frequency of symptoms

Adverse events of adenosine infusion

Transient hypotension (fall of BP below 9 mm of Hg systolic and/or 40 mm Hg diastolic with return to normotension at the end of the scan) was the most common complication in 20 patients (1.8%). Among the patients who had transient hypotension, no symptoms like giddiness or loss of consciousness were reported. Severe chest pain and breathlessness were seen in 6 (0.5%) and 10 (0.9%) patients respectively [Chart 3]. In the 10 patients with severe breathlessness, 5 had a Left Ventricle Ejection Fraction (LVEF) of <50%. Five had double vessel disease and two had triple vessel disease. None of the patients with severe breathlessness had left main stem disease. Of these 10 patients with severe breathlessness, three patients required nebulization with bronchodilator. Of these three patients, who required nebulization, only one had an LVEF of <50% and another one had triple vessel disease.

Six patients had severe chest pain requiring further intervention. All of them had an LVEF of >50% with one patient each having triple vessel and single-vessel disease.

Table 3: Ejection fraction (EF)

EF (%)	No of patients	Percentage (%)
<30	86	12.2
30-39	129	81.6
40-49	174	
50-70	560	
>70	108	10.2

Table 4: Hemodynamic Parameters at Rest and During Adenosine Stress

	Rest	Adenosine Stress
Heart Rate (bpm)	73.44 ± 13.2	95.1 ± 13.5
Systolic BP (mm Hg)	136.4 ± 25.0	132.7 ± 48.0
Diastolic BP (mm Hg)	72.3 ± 12.9	68.84 ± 14.4
Rate pressure product	10047 ± 2751	12650 ± 5216

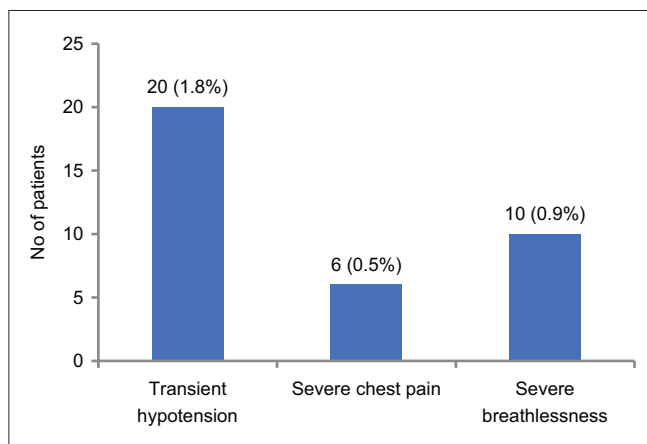


Chart 3: Adverse effects of Adenosine infusion

Three of these patients had good relief with sublingual nitroglycerin and were discharged from the unit. Three patients required hospital admission for unstable angina. Of these, 1 had a large ischemic burden of more than 50% and underwent revascularization on the same day. Remaining two patients underwent revascularization later in that week. No death, myocardial infarction or atrio-ventricular block was recorded during the study period.

Discussion

In this study, we demonstrate that adenosine stress CMR in appropriately selected patients is a safe procedure with less than 1% of patients having significant side effects. To the best of our knowledge, this is the first of its kind study in India with such a large cohort of patients.

Vasodilator agents and physical stress increases systemic and myocardial blood flow. In a severely diseased artery, the capillaries are already maximally dilated and can not cope with this increased myocardial oxygen demand. This leads to delayed delivery of contrast/blood, which is seen as an area of perfusion defect in the myocardium. CMR is highly accurate in demonstrating these perfusion defects and helps in the prognosis of patients.^[5,11,16,20,21]

CMR has a higher spatial resolution (2 mm) compared with SPECT (10 mm) and PET (5 mm), allowing greater sensitivity for detecting perfusion defects. Also, there are no attenuation artefacts on CMR, conferring it a higher sensitivity in detecting diffuse balanced ischemia when compared to SPECT. CMR is also free of ionising radiation in comparison to SPECT and PET.^[22] Numerous studies have demonstrated the utility and superiority of stress CMR in comparison with SPECT.^[6-8]

Within a single study, CMR can assess regional wall motion abnormality, ventricular function, valvular competency, as well as localize and evaluate regions of myocardial ischemia and viability. All these factors have shown to provide added prognostic value in the assessment of patients with CAD.^[9]

Adenosine is the preferred vasodilator agent and is shown to have a better sensitivity and specificity compared to dipyridamole (90% and 81% versus 86% and 77%).^[20] Regadenoson is another potent vasodilator with limited side effects due to its selective binding to A2 receptors. In a comparison study by Vasu *et al.*, when adjusted for heart rate, there was no difference noted in stress myocardial blood flow (MBF) and myocardial perfusion reserve (MPR) between regadenoson and adenosine. Both these parameters were significantly lower with dipyridamole.^[23] From a safety profile, regadenoson may be a preferred drug but it has very limited availability in the Indian market.

In our study, a significant number of patients had hemodynamic response with 81% developing mild symptoms confirming the adequate infusion of adenosine. Most of the symptoms resolved spontaneously on stopping the infusion. Transient hypotension and breathlessness were other side effects which also recovered without much intervention. These findings are consistent and comparable with previously published studies.^[14,24] None of our patients developed high degree AV blocks which is similar to some of the published studies^[17] while it contradicts the findings of some of the other studies.^[14-16]

Severe adverse effects requiring active intervention were seen in 3 patients with chest pain and 3 with breathlessness. The latter recovered after oxygen therapy/bronchodilators and were discharged. There were no common factors relating to LVEF or Left main disease in these patients. Three patients with persistent chest pain at the end of the examination required hospital admission. Of these three, 1 patient had severe double vessel disease with an ischemic burden of more than 50% and underwent revascularization on the same day. The other 2 patients required revascularization later in the week. There was no delayed or recurrent side effects in the 24 hours after adenosine infusion in any patient. We strongly believe, the main reason for such low incidence of severe adverse effects is due to our robust screening procedure and rigorous monitoring protocols during the stress.

This is the largest study looking at the safety of adenosine stress CMR. Being a tertiary referral care center our practices may not be easily replicable in other units. This has to be kept in mind before generalizing our findings. Even though none of the patients developed high degree AV block, cardiac arrest or syncope we would still recommend the availability of all necessary MR compatible resuscitation equipment in the MR suite.

Conclusion

Stress CMR is a comprehensive one-stop tool in the assessment of patients with known or suspected CAD. Stress CMR using adenosine in appropriately selected patients is a highly safe procedure with significant side effects seen in less than 1% of patients. Therefore, it is safe to perform stress CMR studies in a fully equipped and well-trained radiology department in India. Robust screening/selection criteria before accepting patients and proper monitoring during the study are very important. Our study supports the wider adoption of stress CMR in routine clinical practice in India.

Declaration of patient consent

Patient consent was deemed not necessary by the institutional review board.

Financial support and sponsorship

Nil.

Conflicts of interest

There are no conflicts of interest.

References

1. Christopher J, Raj V, Nukala S, Venugopal K. State of overall cardiovascular risk and imaging strategies in India. *Curr Cardiovasc Imaging Rep* 2015;8.
2. Gupta R, Joshi P, Mohan V, Reddy KS, Yusuf S. Epidemiology and causation of coronary heart disease and stroke in India. *Heart* 2008;94:16-26.
3. Gupta S, Gudapati R, Gaurav K, Bhise M. Emerging risk factors for cardiovascular diseases: Indian context. *Indian J Endocrinol Metab* 2013;17:806-14.
4. Murray CJ, Lopez AD. Alternative projections of mortality and disability by cause 1990-2020: Global burden of disease study. *Lancet* 1997;349:1498-504.
5. Kwong RY, Ge Y, Steel K, Bingham S, Abdullah S, Fujikura K, *et al.* Cardiac magnetic resonance stress perfusion imaging for evaluation of patients with chest pain. *J Am Coll Cardiol* 2019;74:1741-55.
6. Schwitter J, Wacker CM, van Rossum AC, Lombardi M, Al-Saadi N, Ahlstrom H, *et al.* MR-IMPACT: Comparison of perfusion-cardiac magnetic resonance with single-photon emission computed tomography for the detection of coronary artery disease in a multicentre, multivendor, randomized trial. *Eur Heart J* 2008;29:480-9.
7. Schwitter J, Wacker CM, Wilke N, Al-Saadi N, Sauer E, Huettle K, *et al.* MR-IMPACT II: Magnetic resonance imaging for myocardial perfusion assessment in coronary artery disease trial: Perfusion-cardiac magnetic resonance vs. single-photon emission computed tomography for the detection of coronary artery disease: A comparative multicentre, multivendor trial. *Eur Heart J* 2013;34:775-81.
8. Greenwood JP, Maredia N, Younger JF, Brown JM, Nixon J, Everett CC, *et al.* Cardiovascular magnetic resonance and single-photon emission computed tomography for diagnosis of coronary heart disease (CE-MARC): A prospective trial. *Lancet* 2012;379:453-60.
9. Bingham SE, Hachamovitch R. Incremental prognostic significance of combined cardiac magnetic resonance imaging, adenosine stress perfusion, delayed enhancement, and left ventricular function over preimaging information for the prediction of adverse events. *Circulation* 2011;123:1509-18.
10. Bodi V, Sanchis J, Lopez-Lereu MP, Nunez J, Mainar L, Monmeneu JV, *et al.* Prognostic value of dipyridamole stress cardiovascular magnetic resonance imaging in patients with known or suspected coronary artery disease. *J Am Coll Cardiol* 2007;50:1174-9.
11. Lipinski MJ, McVey CM, Berger JS, Kramer CM, Salerno M. Prognostic value of stress cardiac magnetic resonance imaging in patients with known or suspected coronary artery disease: A systematic review and meta-analysis. *J Am Coll Cardiol* 2013;62:826-38.
12. Shah R, Heydari B, Coelho-Filho O, Murthy VL, Abbasi S, Feng JH, *et al.* Stress cardiac magnetic resonance imaging provides effective cardiac risk reclassification in patients with known or suspected stable coronary artery disease. *Circulation* 2013;128:605-14.
13. Wolk MJ, Bailey SR, Doherty JU, Douglas PS, Hendel RC, Kramer CM, *et al.* ACCF/AHA/ASE/ASNC/HFSA/HRS/SCAI/

- SCCT/SCMR/STS 2013 multimodality appropriate use criteria for the detection and risk assessment of stable ischemic heart disease: A report of the American College of Cardiology Foundation Appropriate Use Criteria Task Force, American Heart Association, American Society of Echocardiography, American Society of Nuclear Cardiology, Heart Failure Society of America, Heart Rhythm Society, Society for Cardiovascular Angiography and Interventions, Society of Cardiovascular Computed Tomography, Society for Cardiovascular Magnetic Resonance, and Society of Thoracic Surgeons. *J Am Coll Cardiol* 2014;63:380-406.
14. Cerqueira MD, Verani MS, Schwaiager M, Heo J, Iskandrian AS. Safety profile of adenosine stress perfusion imaging: Results from the Adenoscan Multicenter Trial Registry. *J Am Coll Cardiol* 1994;23:384-9.
 15. Karamitsos TD, Arnold JR, Pegg TJ, Cheng AS, van Gaal WJ, Francis JM, *et al.* Tolerance and safety of adenosine stress perfusion cardiovascular magnetic resonance imaging in patients with severe coronary artery disease. *Int J Cardiovasc Imaging* 2009;25:277-83.
 16. Khoo JP, Grundy BJ, Steadman CD, Sonnex EP, Coulden RA, McCann GP. Stress cardiovascular MR in routine clinical practice: Referral patterns, accuracy, tolerance, safety and incidental findings. *Br J Radiol* 2012;85:e851-7.
 17. Voigtlander T, Schmermund A, Bramlage P, Elsasser A, Magedanz A, Kauczor HU, *et al.* The adverse events and hemodynamic effects of adenosine-based cardiac MRI. *Korean J Radiol* 2011;12:424-30.
 18. Kramer CM, Barkhausen J, Bucciarelli-Ducci C, Flamm SD, Kim RJ, Nagel E. Standardized cardiovascular magnetic resonance imaging (CMR) protocols: 2020 update. *J Cardiovasc Magn Reson* 2020;22:17.
 19. Kramer CM, Barkhausen J, Flamm SD, Kim RJ, Nagel E, Society for cardiovascular magnetic resonance board of trustees task force on standardized P. Standardized cardiovascular magnetic resonance (CMR) protocols 2013 update. *J Cardiovasc Magn Reson* 2013;15:91.
 20. Hamon M, Fau G, Nee G, Ehtisham J, Morello R, Hamon M. Meta-analysis of the diagnostic performance of stress perfusion cardiovascular magnetic resonance for detection of coronary artery disease. *J Cardiovasc Magn Reson* 2010;12:29.
 21. Schwitzer J, Nanz D, Kneifel S, Bertschinger K, Buchi M, Knusel PR, *et al.* Assessment of myocardial perfusion in coronary artery disease by magnetic resonance: A comparison with positron emission tomography and coronary angiography. *Circulation* 2001;103:2230-5.
 22. Vogel-Claussen J, Skrok J, Dombroski D, Shea SM, Shapiro EP, Bohlman M, *et al.* Comprehensive adenosine stress perfusion MRI defines the etiology of chest pain in the emergency room: Comparison with nuclear stress test. *J Magn Reson Imaging* 2009;30:753-62.
 23. Vasu S, Bandettini WP, Hsu LY, Kellman P, Leung S, Mancini C, *et al.* Regadenoson and adenosine are equivalent vasodilators and are superior than dipyridamole- a study of first pass quantitative perfusion cardiovascular magnetic resonance. *J Cardiovasc Magn Reson* 2013;15:85.
 24. Nishimura S, Nishimura T, Yamazaki J, Doi O, Konishi T, Iwasaki T, *et al.* Comparison of myocardial perfusion imaging by thallium-201 single-photon emission computed tomography with SUNY4001 (adenosine) and exercise--crossover clinical trial at multi-center. *Kaku Igaku* 2004;41:143-54.