

Chest radiography in adult critical care unit: A pictorial review

Sanjay N Jain, Tanvi Modi¹, Yashant Aswani¹, Ravi U Varma¹

Department of Radiology, Prince Aly Khan Hospital, Aga Hall, Nesbit Road, Mazagaon, ¹Department of Radiology, TNMC and BYL Nair Hospital, Mumbai Central, Mumbai, Maharashtra, India

Correspondence: Dr. Tanvi Modi, Department of Radiology, B.Y.L Nair Hospital, Mumbai, Maharashtra, India.
E-mail: tanvimodi134@gmail.com

Abstract

Patients in the intensive care units suffer from a myriad of cardiopulmonary processes for which portable chest radiography is the most utilized imaging modality. A pragmatic approach toward evaluating the nearly similar radiographic findings seen in most of the pathologies with comparative review and strong clinical acumen can help the radiologists and clinicians achieve a rapid and precise diagnosis.

Key words: Acute respiratory distress syndrome; aspiration, intensive care unit; portable chest radiograph; pulmonary edema

Introduction

The bedside chest radiograph is an indispensable diagnostic tool in the management of critical patients admitted in the intensive care unit (ICU). Studies have shown that up to 65% of ICU chest films may reveal a significant or unsuspected process. The American College of Radiology (ACR) suggests that daily chest radiographs be obtained on patients with acute cardiopulmonary problems and those receiving mechanical ventilation.^[1] The present manuscript attempts to integrate clinical and radiographic perspectives of typical ICU syndromes and conditions seen in ICUs around the world.

Acute respiratory distress syndrome (ARDS)

ARDS is a rapidly progressive hypoxemic state due to diffuse alveolar damage resulting in permeability edema which is independent of concurrent cardiac disease^[1-5] and has a high fatality rate of 50%.^[3] It can result from direct injury to lung (pneumonia, aspiration, near drowning, or

inhalational injury) or secondary to systemic pathologies, such as pancreatitis, severe trauma, extensive burns, and drug overdose.^[3]

The findings on a chest radiograph are stereotypical and evolve as three overlapping phases.^[4] Following an insult, there is a short period of radiographic latency. The earliest findings include those of an interstitial pattern, shortly followed by alveolar flooding of protein rich fluid resulting in air space opacification [Figure 1A]. Thus, Kerley B lines may be seldom radiographed.^[4] The alveolar edema then progresses rapidly within the next 48–72 h passing from patchy opacities to diffuse consolidation^[3-5] [Figure 1B]. The fact that this appearance cannot be fully explained by presence of pleural effusion, atelectasis, or pulmonary nodules^[2] is a clue to diagnosis. The plain film features of exudative phase often mimic that of cardiogenic pulmonary

This is an open access journal, and articles are distributed under the terms of the Creative Commons Attribution-NonCommercial-ShareAlike 4.0 License, which allows others to remix, tweak, and build upon the work non-commercially, as long as appropriate credit is given and the new creations are licensed under the identical terms.

For reprints contact: reprints@medknow.com

Cite this article as: Jain SN, Modi T, Aswani Y, Varma RU. Chest radiography in adult critical care unit: A pictorial review. Indian J Radiol Imaging 2019;29:418-25.

Received: 02-Aug-2019

Revision: 04-Sep-2019

Accepted: 08-Nov-2019

Published: 31-Dec-2019

Access this article online

Quick Response Code:



Website:
www.ijri.org

DOI:
10.4103/ijri.IJRI_329_19

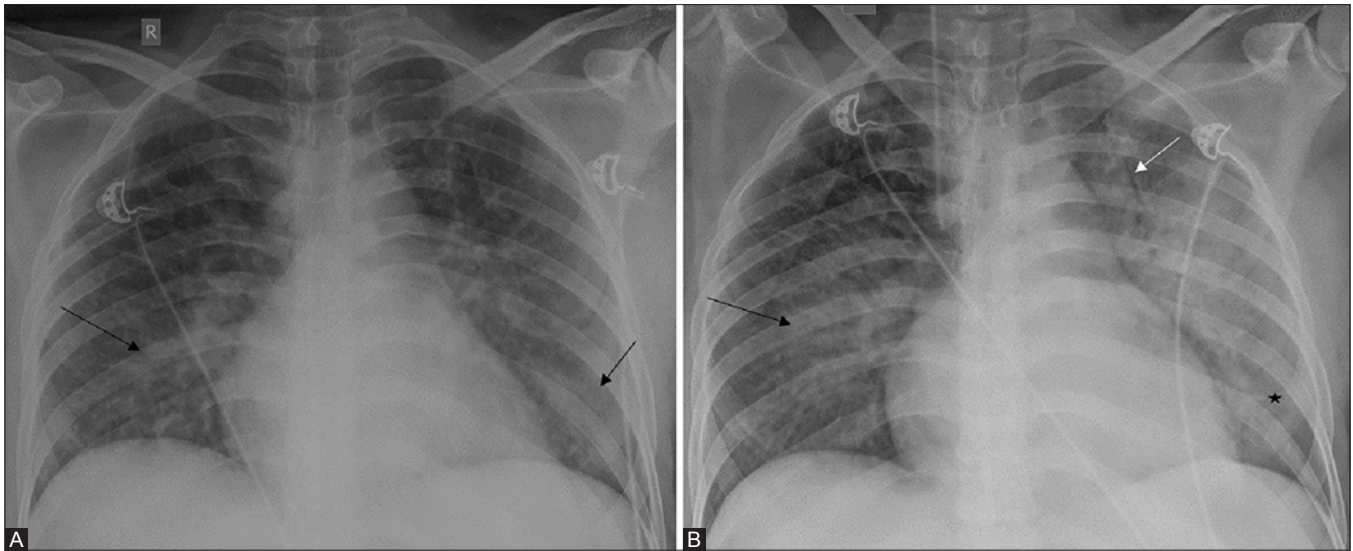


Figure 1 (A and B): (A) Early “exudative phase”-Development of patchy air space consolidations bilaterally (black arrows) resembling alveolar edema. (B) “Proliferative phase”-Visible increase in air space opacities forming coalescent consolidations (black arrow), predominantly in lower zones (asterisk). Note the classic presence of air bronchograms (white arrow)

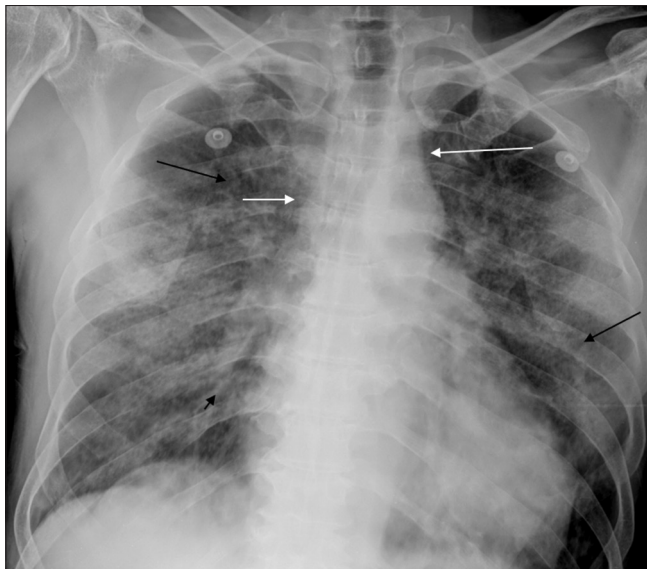

Figure 2: Diffuse, bilateral reticular opacities (black arrows), presence of air bronchograms (black arrowhead), normal vascular pedicle width (white arrows), no “cephalization” of vasculature, normal cardiothoracic ratio, and absent pleural effusions- these findings help zero in on the diagnosis of ARDS

edema; however, absence of cardiomegaly, normal vascular pedicle and lack of apical vascular redistribution, peribronchovascular cuffing and pleural effusion in the former help arrive at a diagnosis [Figure 2]. Further, a near constant radiographic appearance demonstrated by daily portable x-ray favors ARDS over pulmonary edema^[4] which quickly clears on improving the hemodynamic alterations.^[3-5] However, there exists a host of confounding factors like coexistence of ARDS and cardiogenic pulmonary edema especially when ARDS complicates a case of sepsis, presence of pleural effusion in ARDS, and heart failure in a

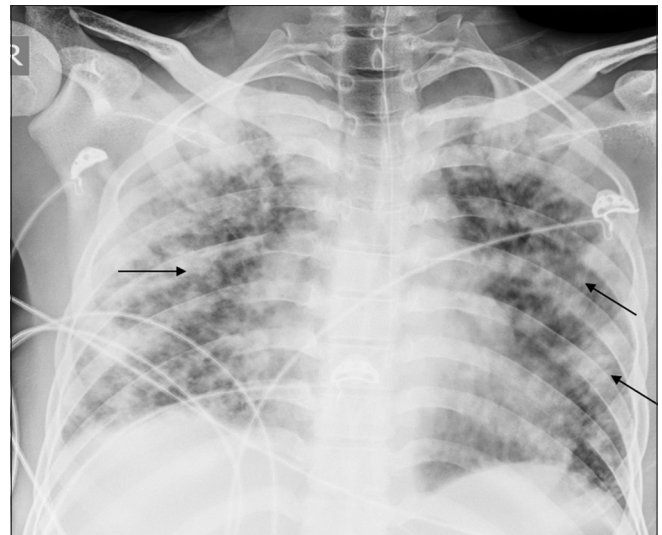

Figure 3: Multifocal patchy air space opacities (black arrows) - pulmonary hemorrhage, a mimicker of ARDS

normal sized heart.^[3] Pulmonary contusion may also share a few imaging features with ARDS^[3] [Figure 3]. However, the former is characterized by localized opacities which are both earlier to appear as well as undergo faster resolution than ARDS.

Progression to proliferative stage is marked by appearance of ground glass opacities. The radiographic appearances of this phase usually stabilize and remain static for a variable period. Hence, the appearance of new air space opacities would mean superadded infections or ARDS related complications^[4] [Figure 4]. Finally, there may be resolution of x- ray findings^[3-5] or persistence of coarse reticular pattern (in 10% of survivors) or formation of subpleural

and or intraparenchymal cysts which when rupture result in pneumothorax.^[3-5]

Patients with ARDS frequently need positive-end expiratory pressure ventilation (contrary to pulmonary edema). A chest radiograph may help tailor the ventilator settings in this regard. Further, serial x-rays may depict changes of barotrauma namely interstitial, mediastinal, subcutaneous emphysema, and pneumothorax^[4] [Figure 4].

Pulmonary edema

Pulmonary edema can be a cause of admission in an ICU or conversely occur during the course of ICU stay.^[5] This transmigration of fluid may be a result of an imbalance between hydrostatic and oncotic pressures, changes in capillary permeability, or a combination of both.^[6] The former is generally seen secondary to cardiac failure, overhydration, or renal insufficiency.^[1]

The increased hydrostatic pressure edema has two phases.^[1,6] An increase of 15 to 25 mm Hg in transmural arterial pressure marks the beginning of interstitial edema. Classic findings in this stage include blurring of vascular markings, appearance of Kerley B lines, subpleural effusions, and peribronchial cuffing^[1,5,6] [Figure 5A-C]. With continued increase in transmural arterial pressure, typically in excess of 25 mm Hg, alveolar flooding is evident which is characterized by appearance of tiny nodular or acinar shadows.^[6] Further worsening may result in frank consolidation. The classic bat-wing edema is seen in 10%

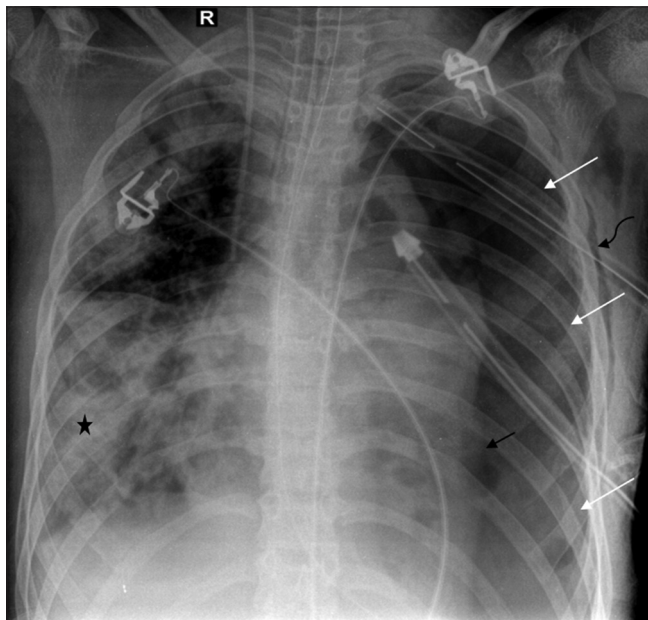


Figure 4: Patient under treatment for ARDS with focal patchy consolidation in right mid and lower zone (asterisk)-frequently seen complication of superimposed pneumonia. Intubation may induce complications of barotrauma - pneumothorax in left hemithorax (white arrows) with medial collapse of left lung (black arrow). Chest drain *in situ* with associated subcutaneous emphysema (curved black arrow)

of patients and displays a perihilar distribution owing to rapidly progressive alveolar flooding^[6] [Figure 5D].

Variability in appearances of pulmonary edema may be due to lung parenchymal changes (Chronic Obstructive Pulmonary Disease, fibrosis due to tuberculosis), specific conditions (right upper lobe involvement in acute mitral regurgitation), and patient position. These may result in a unilateral, lobar, or lower zone distribution or a miliary pattern^[1,6] [Figure 6].

The permeability edema of ARDS can be distinguished from hydrostatic pressure edema based on the presence of cardiomegaly and a vascular pedicle more than 7–8 cm in the latter^[5] [Figure 7].

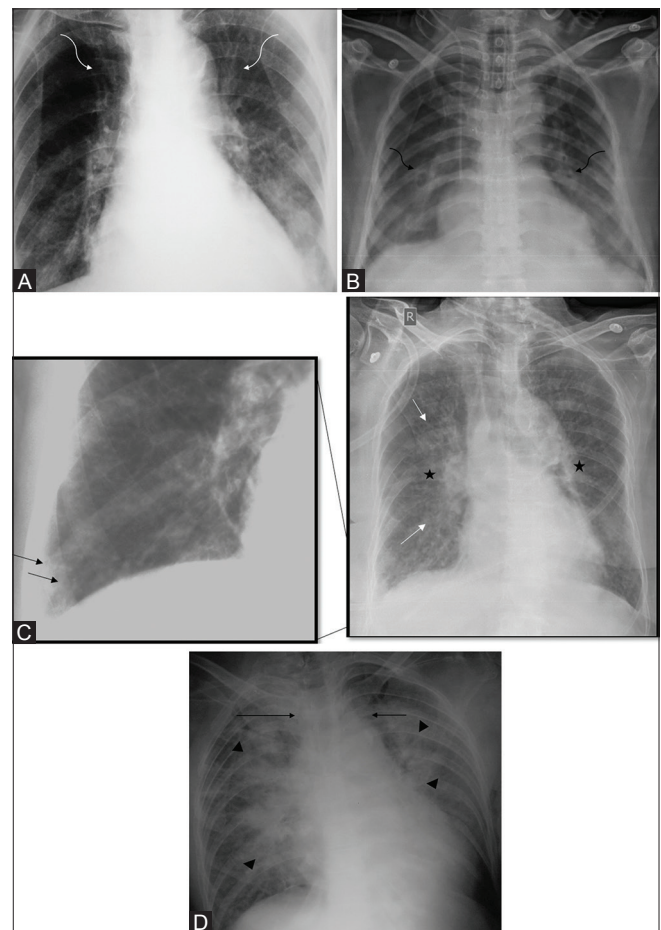


Figure 5 (A-D): (A) Earliest changes of pulmonary edema (CVP 10-25 mmHg): redistribution of pulmonary veins- “cephalization” (curved white arrows). (B) With increasing pressure (CVP 20–25 mmHg), transudation of fluid around bronchi seen as peribronchial cuffing (curved black arrows). (C) Interstitial edema within lymphatics - Kerley B lines [thin, short lines 1–2 cm in length, at the periphery perpendicular to pleural surface] (black arrows). Other features seen are cardiomegaly, indistinctness of pulmonary vessels (asterisks), and early changes of perihilar bat wing opacities (white arrows). (D) At CVP 25- 30 mm Hg, fluid accumulates in alveoli producing classic perihilar batwing or angel wing consolidation (black arrow heads). Increased vascular pedicle width (black arrows) points to a likely underlying renal pathology (overhydration), leading to pulmonary edema

Ventilator-associated pneumonia

Ventilator-associated pneumonia (VAP) is a polymicrobial pneumonia that occurs 48–72 h after intubation.^[7] It constitutes 50% of cases of hospital acquired pneumonia and occurs in 9–27% of mechanically ventilated patients.^[7] It is the leading cause of death in ICU patients^[1] and hence its early diagnosis is crucial. However, both clinical as well as radiographic criteria to diagnose the condition are nonspecific.^[1,5,7,8]

Typical plain film findings in VAP include patchy areas of consolidation or poorly defined opacities which are

often multifocal^[1,5] [Figure 8]. Additional finding of pleural effusion favors this diagnosis. Absence of volume loss makes atelectasis an unlikely consideration. Likewise, a change in pattern over hours (following correction of hemodynamics) is a tell-tale sign of pulmonary edema.^[5] About a third of patients may be missed based on clinical evaluation.^[7] Hence, complications like abscess [Figure 9], pleural empyema, and bronchopleural fistula may be more commonly encountered in them.^[1] It is of prime importance to bear in mind that a

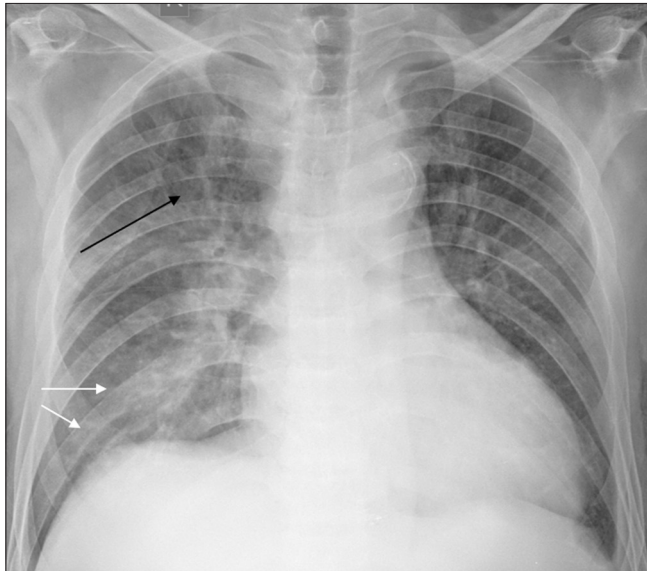


Figure 6: Cardiomegaly with cephalization of pulmonary vessels (black arrow) and patchy right-sided air space opacities (white arrows) - Right-sided unilateral pulmonary edema. Unilaterality can be mistaken for pneumonia, pulmonary hemorrhage, aspiration

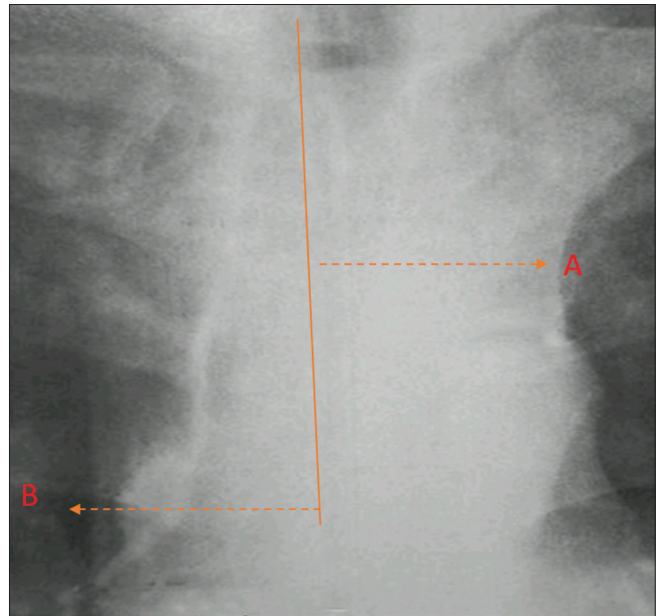


Figure 7: Measurement of vascular pedicle width: Draw a perpendicular A at the junction of left subclavian artery with aorta. Draw a perpendicular B at the intersection of superior vena cava with right mainstem bronchus. Normal width: 7–8 cm

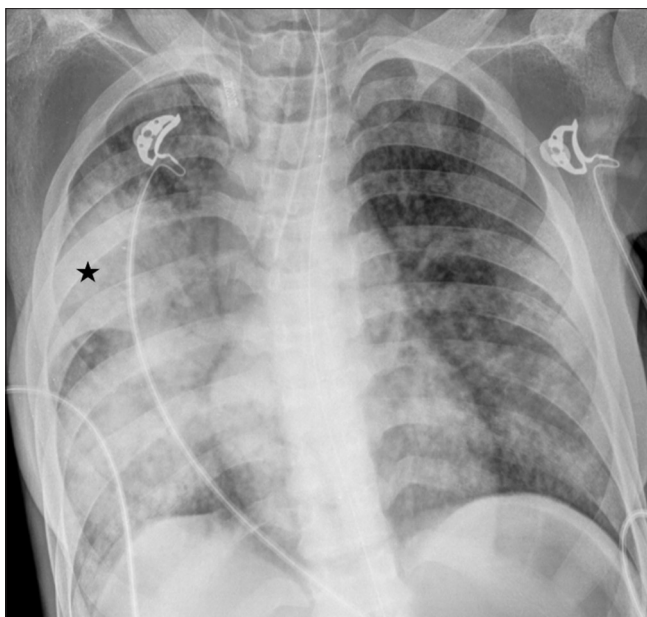


Figure 8: Patchy areas of multifocal opacities in right lung fields (asterisk) – developing ventilator associated pneumonia

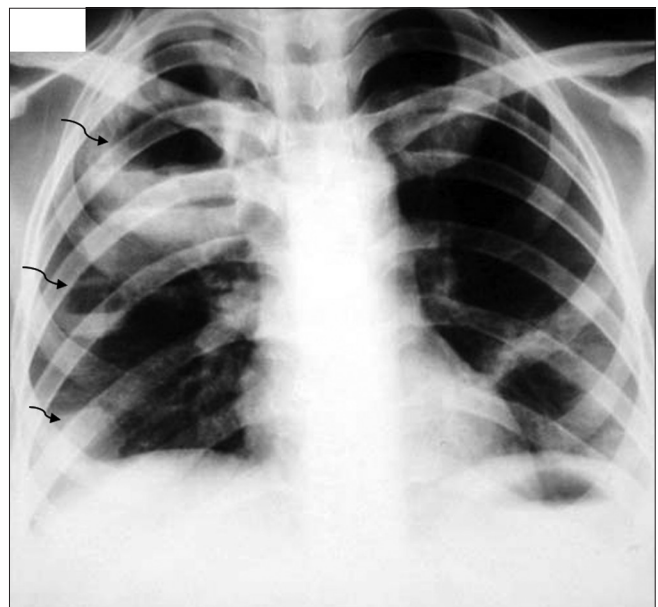


Figure 9: Multiple round opacities demonstrating air fluid levels in right lung fields (curved black arrows) - abscess formation as a complication of pneumonia

negative chest x-ray does not exclude the possibility of VAP, particularly in immunocompromised patients.^[5]

Atelectasis

Atelectasis is defined as failure of the lung or part of it to expand completely.^[1] It may be caused by an endobronchial obstructive pathology or alternatively by pleural fluid, pneumonia or lymph nodes compressing the bronchus, resulting in compressive atelectasis.^[5] Statistically, atelectasis is the leading cause of radio-opacity on a chest film in an ICU setup.^[5]

Roentgenographic findings include an increase in opacity and signs of volume loss namely displacement of fissures and hilum, crowding of pulmonary vessels, hilum, deviation of trachea, unilateral elevation of diaphragm, and compensatory overinflation^[1,5] [Figures 10 and 11]. However, the signs may often be subtle leading to a misdiagnosis.

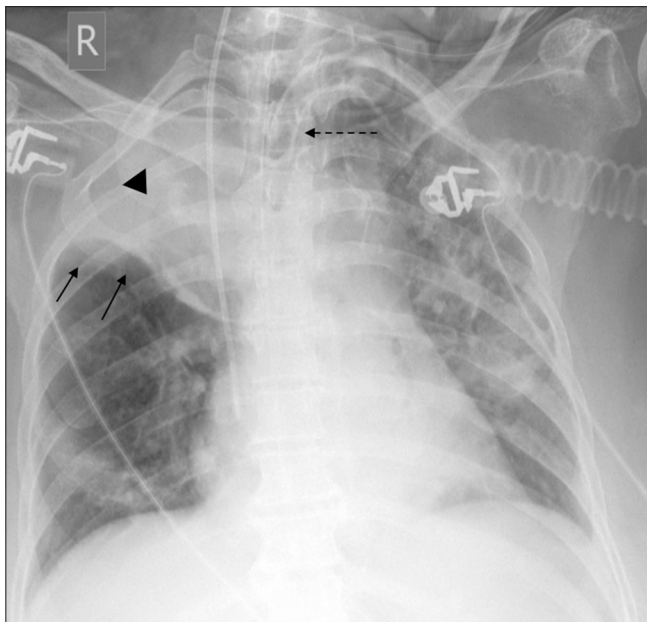


Figure 10: Homogenous air space opacity in right upper zone (arrow head) with absent air bronchogram, upward fissural displacement (black arrows), tracheal pull (interrupted black arrow)

A lower lobe collapse presents with a wedge shaped radio-opacity that points toward the hilum and obscures the respective hemidiaphragm with downward, posterior, and medial migration of the atelectatic lobe.^[1,9] An underpenetrated film may miss the retrocardiac atelectatic lobe in case of marked collapse of left lower lobe.^[9] Atelectasis of right middle lobe or lingula on left presents with subtle increase in density with loss of discreteness of cardiac borders.^[9] A lateral film shows the collapse to a better advantage.

With collapse of right upper lobe, the lesser fissure migrates superiorly and medially resulting in a triangular radiopacity^[9] [Figure 10]. On the contrary, the left upper lobe collapses anteriorly and upward with a faint lateral margin (because of absence of minor fissure on the left).^[1,9] The loss of interface with the

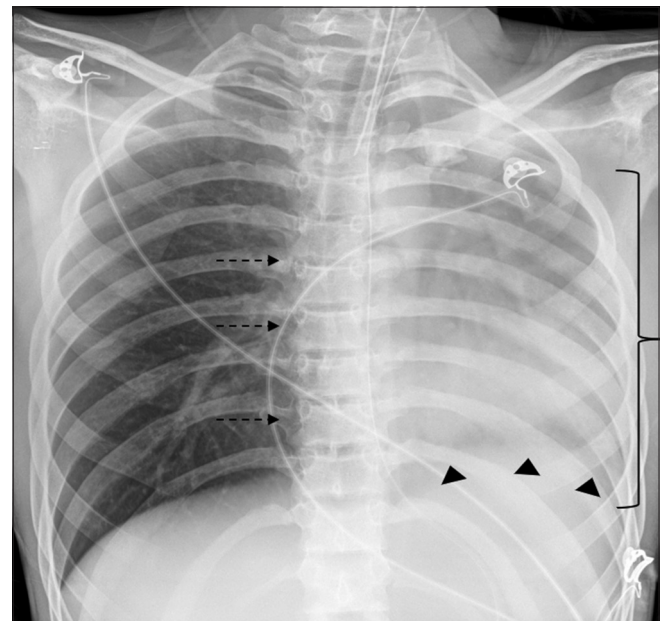


Figure 11: Left-sided atelectasis with crowding of ribs (bracket), ipsilateral mediastinal shift (interrupted arrows), elevation of hemidiaphragm (arrowheads)

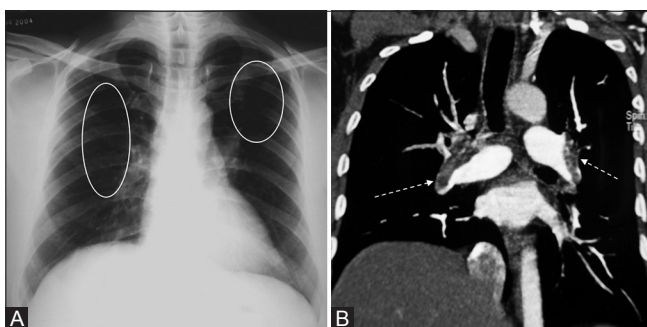


Figure 12 (A and B): Bilateral lucent areas (white circles) representing oligemia in a patient (A) with computed tomography (B) suggestive of bilateral pulmonary emboli (white interrupted arrows)

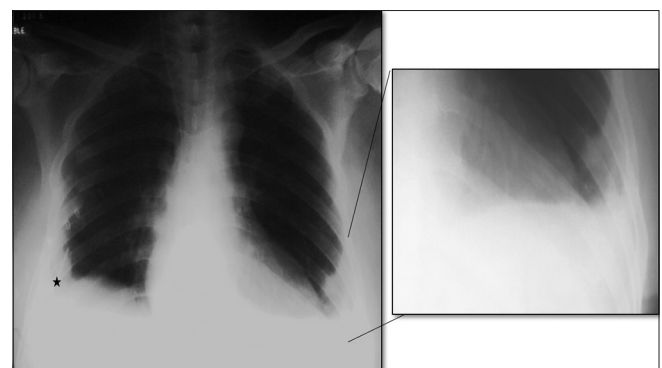


Figure 13: A pleural-based triangular opacity (inset) seen in left lower lobe representing “Hampton’s hump”- an area of peripheral infarction secondary to pulmonary embolism with blunting of right costophrenic angle (asterisk) representing pleural effusion

aortic knob that occurs with collapse may sometimes be occupied by radiolucency of hyperexpanded left lower lobe (luftsichel sign).

Pulmonary thromboembolism

Acute pulmonary thromboembolism (APTE) is frequently unsuspected and underdiagnosed.^[1] Although radiographic findings of APTE are subtle and usually nonspecific; the key role of a plain film is to exclude alternate diagnoses.^[1] Cardiomegaly is the most common finding.^[10] The enlargement of right heart and theazygous system of veins is secondary to acute pulmonary hypertension.^[11]

Atelectasis is yet another common finding in APTE and presents as subsegmental curved lines that abut the pleural surface.^[11] Pleural effusion howsoever nonspecific is reported to be present in 50% of cases of APTE. The effusion is serous, generally bilateral, and mild in quantity.^[1,11] Occurrence of specific signs like enlargement of right descending pulmonary artery (Palla’s sign)^[1,11,12]

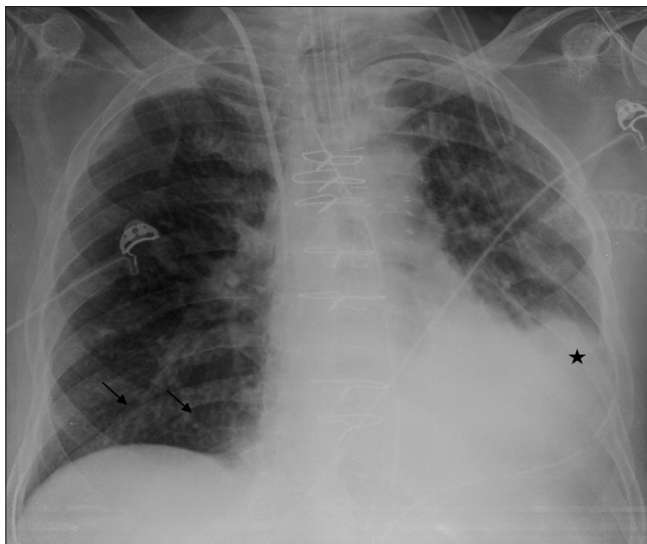


Figure 14: Patchy air space opacity with absent air bronchogram in left lower zone (asterisk) with reticular opacities in right lower zone (black arrows)- dependent opacities in aspiration

or the central one (Fleischner’s sign),^[12] abrupt tapering of pulmonary artery (knuckle sign),^[12] oligemia beyond the site of occlusion (Westermark sign)^[1,11,12] [Figure 12A and B], and a triangular radiopacity that lacks air bronchogram with the apex pointing toward hilum (Hampton’s hump) [Figure 13] is uncommon.^[11] Similarly, pulmonary infarction is rare and usually manifests as multifocal consolidation, 12–24 h following an embolic event with a propensity to involve the basal segments.^[1]

Aspiration

Aspiration of gastric and/or oropharyngeal secretions is common in mental obtundation,^[13] placement of endotracheal or nasogastric tubes^[1] or tracheostomy with manifestations varying from mild bronchiolitis to hemorrhagic pulmonary edema. The condition further worsens owing to secondary infection or may resolve without any complications.

Chest x-ray features in aspiration are nonspecific^[13] with variability being the hallmark. Common appearances include small irregular shadows present singly or in combination with confluent or acinar infiltration.^[13] The distribution of these opacities depends on patient position, gravity, and dynamics of air flow with perihilar and basal^[1,13] or superior segment of lower lobe [Figure 14] and posterior segment of upper lobe^[14] being the commonest. The diagnosis of aspiration needs to be entertained in the correct clinical setting with rapidly and extensively developing pulmonary infiltrates in a previously normal documented radiograph, an uncomplicated course with prompt resolution, normal cardiac silhouette, and absence of pleural effusion.^[13]

Neurogenic Pulmonary Edema

Neurogenic pulmonary edema (NPE) is seen in patients with subarachnoid hemorrhage, status epilepticus, and trauma.^[6,15] It is a rare event. A massive adrenergic drive following the severe neural insult^[15] triggers a mixed

Table 1: Comparison of radiographic findings in each pathology

Radio graphic finding	ARDS	Pulmonary edema	Ventilator-associated pneumonia	Atelectasis	APTE	Aspiration	Neurogenic pulmonary edema
Vascular pedicle width	Normal	Widened	Normal	Normal	Normal	Normal	Normal
Cardiac size	Normal	Increased	Normal	Normal	Increased	Normal	Increased
Hilar prominence	Absent	Present	+/-	Absent	Present	Absent	Present
Pleural effusion	Absent	Present	Present	+/-	+/-	Absent	Present
Pulmonary opacities	Patchy, diffuse	Perihilar	Focal/Multifocal	Lobar specificity	Subpleural, basal	Dependent	Perihilar, upper zone
Interstitial markings	Present	Present	Absent	Absent	Absent	Present	Present
Volume loss	Chronic change	Absent	Absent	Present	+/-	Absent	Absent
Silhouette sign	+/-	+/-	Present	Present	+/-	+/-	+/-
Resolution	Delayed/fibrosis	Early	Delayed, complications +/-	Variable	Delayed/absent	Early	Early

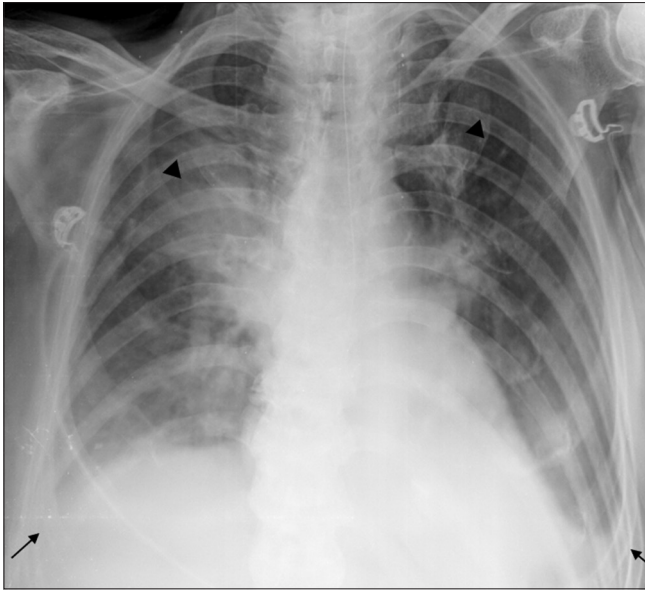


Figure 15: Frontal radiograph of a patient with stroke taken 6 h post thrombolysis shows bilateral, homogenous, upper zone predominant alveolar opacities (arrow heads), and bilateral blunting of costophrenic angles (black arrows) suggesting pleural effusion. Repeat radiograph after 3 days was normal- neurogenic pulmonary edema

pulmonary edema (hydrostatic pressure and permeability edema) without diffuse alveolar damage.

NPE may develop within seconds to minutes after a seizure activity and resolves in 24–48 h.^[6] Chest radiographic findings are those of cardiogenic pulmonary edema [Figure 15] and hence diagnosis of NPE is one of exclusion. It is important to recognize NPE as hypoxemia caused by the pulmonary event may further aggravate the initial neural insult.^[15]

A comparison of the various entities has been provided below [Table 1].

In order to ensure accuracy, radiologists can refer to a checklist prior to preparing a report as follows:

1. Is there cardiomegaly?
2. Is there any abnormality of vascular markings- hilar prominence/cephalization of vessels/prominent descending pulmonary arteries?
3. Are there interstitial markings, Kerley lines seen?
4. Pulmonary opacities
 - distinguishable from overlying lines and tubes?
 - persistent or newly developed?
 - with air bronchogram?
 - do they conform to any specific underlying pathology?
 - with features of volume loss?
 - is there any loss of silhouette?
 - secondary cavitation?
 - progression on serial radiographs?

5. Costophrenic angles, major and minor fissures to be evaluated for pleural effusion
6. Lines and tubes
 - type of device
 - appropriate positioning
 - secondary complications
 - barotrauma
7. Bony cage
 - fractures or dislocation of ribs (or flail chest)/vertebrae sternum/clavicle/scapula
 - deformities of bony cage
 - post-procedural changes: sternotomy wires vertebroplasty/kyphoplasty/spinal fixation/thoracotomy and associated complications
8. Soft tissue structures - subcutaneous emphysema/soft tissue lesion/postoperative changes (e.g., mastectomy)
9. Abdomen- pneumoperitoneum/pathological calcifications/bowel gas pattern
10. Comparison of serial radiographs.

Conclusion

The interpretation of the portable ICU chest radiograph finding is often challenging. To the inexperienced clinician and radiologist, the findings often seem nonspecific and appear to be overlapping in majority of conditions. A systematic study of the bedside radiographs with amalgamation of clinical and laboratory information and review of sequential radiographs helps to arrive at the diagnosis in most cases.

Financial support and sponsorship

Nil.

Conflicts of interest

There are no conflicts of interest.

References

1. Khan AN, Al-Jahdali H, Al-Ghanem S, Gouda A. Reading chest radiographs in the critically ill (Part II): Radiography of lung pathologies common in the ICU patient. *Ann Thorac Med* 2009;4:149-57.
2. Fanelli V, Vlachou A, Ghannadian S, Simonetti U, Slutsky AS, Zhang H. Acute respiratory distress syndrome: New definition, current and future therapeutic options. *J Thorac Dis* 2013;5:326-34.
3. Zompatori M, Ciccarese F, Fasano L. Overview of current lung imaging in acute respiratory distress syndrome. *Eur Respir Rev* 2014;23:519-30.
4. Sheard S, Rao P, Devaraj A. Imaging of acute respiratory distress syndrome. *Respir Care* 2012;57:607-12.
5. Eisenhuber E, Schaefer-Prokop CM, Prosch H, Schima W. Bedside chest radiography. *Respir Care* 2012;57:427-43.
6. Gluecker T, Capasso P, Schnyder P, Gudinchet F, Schaller MD, Revelly JP, *et al.* Clinical and radiologic features of pulmonary edema. *Radiographics* 1999;19:1507-31; discussion 1532-3.

7. Kalanuria AA, Zai W, Mirski M. Ventilator-associated pneumonia in the ICU. *Crit Care* 2014;18:208.
8. Mandell LA, Wunderink R. Pneumonia. In: Fauci AS, Braunwald E, Kasper DL, *et al.*, (eds.), *Harrison's Principles of Internal Medicine*. 17th ed., vol. 2. USA: McGraw-Hill Companies; 2008. p. 1619-28.
9. Felson B. The Lobes. In: *Chest Roentgenology*, Indian ed. New Delhi: AITBS Publishers; 2011. p. 92-124.
10. Elliott CG, Goldhaber SZ, Visani L, DeRosa M. Chest radiographs in acute pulmonary embolism. Results from the International cooperative pulmonary embolism registry. *Chest* 2000;118:33-8.
11. Cardinale L, Volpicelli G, Lamorte A, Martino J, Veltri A. Revisiting signs, strengths and weaknesses of standard chest radiography in patients of acute dyspnea in the emergency department. *J Thorac Dis* 2012;4:398-407.
12. Abbas A, St Joseph EV, Mansour OM, Peebles CR. Radiographic features of pulmonary embolism: Westermark and Palla signs. *Postgrad Med J* 2014;90:422-3.
13. Landay MJ, Christensen EE, Bynum LJ. Pulmonary manifestations of acute aspiration of gastric contents. *AJR Am J Roentgenol* 1978;131:587-92.
14. Franquet T, Giménez A, Rosón N, Torrubia S, Sabaté JM, Pérez C. Aspiration diseases: Findings, pitfalls, and differential diagnosis. *Radiographics* 2000;20:673-85.
15. Ridenti FA. Neurogenic pulmonary edema: A current literature review. *Rev Bras TerIntensiva* 2012;24:91-6.