

Hyperglycemia-induced seizures - Understanding the clinico- radiological association

Shivaprakash B Hiremath^{1,2}, Amol A Gautam^{2,3}, Prince J George², Agnes Thomas², Reji Thomas⁴, Geena Benjamin²

¹Department of Medical Imaging, The Ottawa Hospital, Ottawa, Ontario, Canada, ²Department of Radiodiagnosis, Krishna Institute of Medical Sciences, Karad, Maharashtra, Departments of ³Radiodiagnosis and ⁴Neurology, Pushpagiri Institute of Medical Sciences and Research Centre, Tiruvalla, Kerala, India

Correspondence: Dr. Amol A Gautam, Department of Radiodiagnosis, Krishna Institute of Medical Sciences, Karad, Maharashtra, India.
E-mail: gautamamol75@gmail.com

Abstract

Objectives: To highlight the typical magnetic resonance imaging (MRI) findings in hyperglycemia-induced seizures and compare the results with similar previous studies with a brief mention of pathophysiological mechanisms. **Materials and Methods:** This retrospective study included medical and imaging records of six consecutive patients with hyperglycemia-induced seizures. The data analysis included a clinical presentation and biochemical parameters at admission. The MRI sequences were evaluated for region involved, presence of subcortical T2 hypo-intensity, cortical hyper-intensity, and restricted diffusion. Similar previous studies from the National Library of Medicine (NLM) were analyzed and compared with our study. **Results:** Twenty-four patients were included from four studies in previous literature for comparison. In our study, on imaging, posterior cerebral region was predominantly involved, with parietal involvement in 83.3%, followed by occipital, frontal, and temporal involvement in 33.3% patients compared with occipital in 58.3%, parietal in 45.8%, and frontal and temporal in 16.6% of patients in previous literature. The subcortical T2 hypo-intensity was present in 83.3% of the patients, cortical hyper-intensity in all patients, and restricted diffusion in 66.6% of the patients in our study compared with subcortical T2 hypo-intensity in 95.8% of the patients, cortical hyper-intensity in 62.5%, and restricted diffusion in 58.3% of the patients in previous literature. **Conclusion:** Although many etiologies present with subcortical T2 hypointensity, cortical hyperintensity, restricted diffusion, and postcontrast enhancement on MRI, the clinical setting of seizures in a patient with uncontrolled hyperglycemia, hyperosmolar state, and absence of ketones should suggest hyperglycemia-induced seizures to avoid misdiagnosis, unnecessary invasive investigations, and initiate timely management. **Advances in Knowledge:** Our study highlights the presence of posterior predominant subcortical T2, fluid-attenuated inversion recovery (FLAIR), and susceptibility-weighted angiography (SWAN) hypointensity; cortical hyperintensity; and restricted diffusion in hyperglycemia-induced seizures. The presence of T2 and SWAN hypointensity could support the hypothesis of possible deposition of free radicals and iron in the subcortical white matter.

Key words: Hyperglycemia; magnetic resonance imaging; seizures

This is an open access journal, and articles are distributed under the terms of the Creative Commons Attribution-NonCommercial-ShareAlike 4.0 License, which allows others to remix, tweak, and build upon the work non-commercially, as long as appropriate credit is given and the new creations are licensed under the identical terms.

For reprints contact: reprints@medknow.com

Cite this article as: Hiremath SB, Gautam AA, George PJ, Thomas A, Thomas R, Benjamin G. Hyperglycemia-induced seizures - Understanding the clinico- radiological association. Indian J Radiol Imaging 2019;29:343-9.

Received: 31-Aug-2019

Revision: 08-Oct-2019

Accepted: 23-Oct-2019

Published: 31-Dec-2019

Access this article online

Quick Response Code:



Website:
www.ijri.org

DOI:
10.4103/ijri.IJRI_344_19

Introduction

The hyperglycemic hyperosmolar state (HHS) is a clinical syndrome characterized by increased blood glucose levels and serum osmolality; dehydration, in the absence of serum and urinary ketones; and acidosis.^[1] Although the incidence of HHS is not exactly known, it accounts for about <1% of hospital admissions because of diabetes.^[2] Usually, HHS presents in elderly individuals with prolonged type II diabetes and has a higher mortality of about 20% compared to <5% in diabetic ketoacidosis (DKA).^[3-5] It can clinically present with symptoms of focal seizures, epilepsy partialis continua (EPC), myoclonus, hemiparesis, hypertonia, and altered sensorium.^[6,7] Early recognition of imaging findings in HHS in those who present with seizures is necessary to avert future complications, initiate prompt management, and reduce mortality.

Characteristic magnetic resonance imaging (MRI) findings in hyperglycemia-induced seizures include focal altered signal intensity, i.e., subcortical T2 hypointensity with gyral hyperintensity involving the cortex and cortical or leptomeningeal postcontrast enhancement.^[8-12] In this study, we present the clinical and MRI findings in six patients with hyperglycemia-induced seizures with a mention of possible underlying pathophysiological mechanisms and review of the literature. We performed a PUBMED search for articles published in English in the database of the National Library of Medicine (NLM) with keywords including “hyperglycemia,” “seizures,” “nonketotic hyperglycemia,” “MRI,” and “imaging findings.” We included all the studies published with three or more patients describing MRI findings in hyperglycemia-induced seizures after the exclusion of case reports.

Materials and Methods

Study participants

The institute ethics committee of Pushpagiri Institute of Medical Sciences, Tiruvalla, Kerala waived the need for approval due to the retrospective nature of the study. The study group comprised of six consecutive patients with clinical and imaging diagnosis of hyperglycemia-induced seizures in an appropriate clinical setting followed by resolution post-therapy from June 2016 to June 2018 after exclusion of those with an alternate diagnosis on further clinical workup.

The clinical records of the patients were reviewed by an experienced neurologist (RT) for symptoms at presentation, history of diabetes, random blood sugar levels, serum electrolytes (sodium and potassium), blood urea, and HbA1C levels at presentation. The serum osmolality and blood urea nitrogen were calculated as follows,

Serum osmolality ($mOsm/kg = (2x (Na \{mmol/L\} + K \{mmol/L\}) + (BUN \{mg/dl\}/2.8) + (glucose \{mg/dl\}/18)$

Blood urea nitrogen (mg/dl) = $Urea (mg/dl)/2.14$

Image acquisition

All the patients underwent MRI on a 1.5 Tesla scanner (Signa HDxt, GE Healthcare, Milwaukee, USA), including conventional sequences (T1 weighted image [T1W], T2W, and fluid-attenuated inversion recovery [FLAIR]) and advanced sequences (diffusion-weighted imaging [DWI] and susceptibility-weighted angiography [SWAN]). None of the patients underwent postcontrast T1W/FLAIR imaging.

Image analysis

Two radiologists (AAG and SBH with experience of >5 years) assessed the MRI findings in hyperglycemia-induced seizures. The regions of the brain involved, and the presence of altered signal intensity of the cortex and subcortical white matter was evaluated on T2W, FLAIR, and SWAN with the presence of restricted diffusion on DWI.

Statistical analysis

The Statistical Package for the Social Sciences (SPSS) software, version 22 (IBM, Armonk, New York: IBM Corp) was utilized to perform the statistical analysis of all datasets. Descriptive statistics were used for continuous and discrete variables.

The blood levels of random blood sugar and serum osmolality were available in all the included studies and were compared using a one-way analysis of variance (ANOVA) test. Similarly, the signal intensity of subcortical white matter on T2Ws, cortical signal intensity on FLAIR, and DWIs were compared using an independent Chi-square test. $P < 0.05$ was deemed statistically significant.

Results

Clinical and demographic characteristics

The clinical and laboratory findings are as shown in Table 1. There were six patients, four males and two females, with age ranging from 60 to 68 years (mean \pm standard deviation [SD], 63 ± 2.9 years). All patients had type 2 diabetes mellitus (DM), presented with seizures and underwent MRI showing abnormalities. None of the patients had any known etiology for epilepsy other than hyperglycemia. All patients had uncontrolled DM with increased blood glucose levels (range, 385–563 mg/dl; mean \pm SD, 500.8 ± 64.2) and glycated hemoglobin (range, 7.2–13.6 mg/dl; mean \pm SD, 10.4 ± 2.0). The serum osmolality values were mildly elevated in five patients with normal value in one patient (range, 294–319; mean \pm SD, 308.1 ± 8.8). The blood urea nitrogen levels were variable (range, 13–25.7 mg/dl; mean \pm SD, 19.2 ± 4.8). Two patients underwent lumbar puncture with normal cerebrospinal fluid (CSF) analysis and showed normal cell counts with no features to suggest bacterial or viral infection. All the patients showed a lack of ketones on urinalysis with elevated urine sugar levels. Two patients

underwent electroencephalogram (EEG) with no abnormal ictal discharges.

MRI findings

The MRI abnormalities are as shown in Table 2 and Figures 1-3. Cortical hyperintensity was seen in all patients on T2W and FLAIR sequences with restricted diffusion in four patients and the hyperintense cortex on SWAN in two patients. The DWI showed no restriction in two patients with the isointense signal in the cortex in the involved areas. The subcortical T2, FLAIR, and SWAN hypointensity were seen in five patients with the hypointense subcortical white matter on DWI in one patient. The subcortical white matter showed an isointense signal on T2, FLAIR, and SWAN in one patient with isointensity in the subcortical white matter on DWI. There was no evidence of hemorrhage in the involved areas on SWAN. The involvement was predominantly in the posterior cerebral region with parietal involvement in five

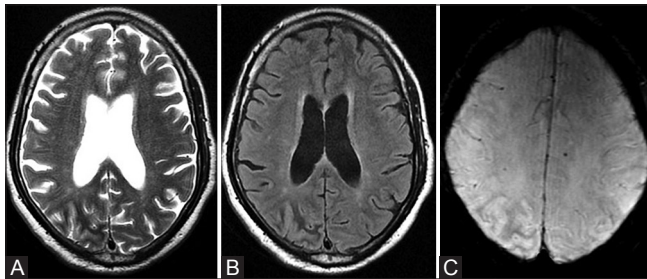


Figure 1 (A-C): Axial T2W (A) FLAIR (B) and SWAN (C) images of the brain show cortical hyper-intensity on T2W, FLAIR, and SWAN images involving right parietooccipital region with adjacent subcortical white matter hypo-intensity

of six patients (83.3%), followed by occipital in two (33.3%), frontal in two (33.3%), and temporal in two patients (33.3%).

Follow-up

All the patients were seizure-free after glycemic control and adequate hydration at discharge. The patients were on antiepileptic medication in the period of hospitalization with no further episodes of seizures on follow-up.

Comparison between the various included studies

The analysis of biochemical parameters among various included studies, i.e., random blood sugar and serum osmolality levels were similar as they lacked statistically significant difference as depicted in Table 3. Similarly, the MRI findings, i.e., the subcortical T2 signal intensity and cortical signal intensity on DWIs lacked statistically significant difference as depicted in Table 4. However, the cortical signal intensity on FLAIR among various included studies showed a statistically significant difference, suggesting variability in the FLAIR signal intensity of the cortex.

Discussion

Hyperglycemia-induced seizures are refractory to antiepileptic medications, account for 15–40% of seizures in patients with HHS, and are commonly focal motor seizures and epilepsy partialis continua.^[13,14] Two patients presented with focal motor seizures, two with myoclonic jerks, and one with generalized tonic-clonic seizures and complex partial seizures. It has been documented that,

Table 1: Demographics, clinical presentation, and laboratory investigations

Age/ Sex	Clinical presentation	Blood glucose (mg/dl)	HbA1C (mg/dl)	Na ⁺ /K ⁺ (mmol/L)	BUN (mg/dl)	Serum osmolality (mOsm/kg)	Urinary investigations	
							Sugar	Ketones
61/M	Left focal motor seizures (Left frontal headache)	482	10.4	132/4.2	15.87	305	+++	Nil
68/F	Right focal motor seizures	540	13.6	130/4.5	25.67	308	+++	Nil
64/M	Multiple myoclonic jerks-Right lower limb	563	7.2	136/3.7	23.8	319	+++	Nil
60/M	Myoclonic jerks in lower limbs (Increased sweating, altered sensorium, slurring of speech)	539	10.3	136/3.2	20.07	316	+++	Nil
64/M	Generalized tonic clonic seizures (Right hemiparesis)	496	10.9	133/4.5	13.07	307	++++	Nil
61/F	Right complex partial seizures (Acute onset confusion and disorientation, slurring of speech)	385	10.2	129/4.3	16.8	294	+++	Nil

BUN=Blood urea nitrogen

Table 2: Summary of MRI findings

Location involved	Cortex			Subcortical white matter		
	T2/FLAIR	DWI	SWAN	T2/FLAIR	DWI	SWAN
Left frontoparietal	Hyperintense	Restriction	Isointense	Hypointense	Isointense	Hypointense
Left temporoparietal	Hyperintense	Isointense	Isointense	Hypointense	Isointense	Hypointense
Right parietooccipital	Hyperintense	Restriction	Isointense	Hypointense	Isointense	Hypointense
Left parietooccipital	Hyperintense	Isointense	Hyperintense	Isointense	Isointense	Isointense
Right frontal	Hyperintense	Restriction	Hyperintense	Hypointense	Hypointense	Hypointense
Left temporoparietal	Hyperintense	Patchy restriction	Isointense	Hypointense	Isointense	Hypointense

MRI=Magnetic resonance imaging, FLAIR=Fluid attenuation inversion recovery, DWI=Diffusion-weighted imaging, SWAN=Susceptibility-weighted angiography

patients with poorly controlled diabetes and high glycated hemoglobin are at increased risk of seizures.^[9,15,16] All the patients in our series, had documented hyperglycemia at presentation, a possible proconvulsant state with elevated HbA1C levels, indicating poorly controlled diabetes of long duration.

A total of four studies (with ≥3 patients) describing MRI findings in hyperglycemia-induced seizures comprising a total of 24 patients were found on PUBMED search in the database of the NLM.^[11,12,17,18] The imaging findings of the patients in previous studies have been described in Supplementary Table 1. All the patients in our study showed cortical hyperintensity with restricted diffusion involving 4 of 6 patients (66.6%) compared with cortical hyperintensity in 15 of total 24 patients (62.5%) and restricted diffusion in 14 of 24 patients (58.3%) in previous literature. In our study, 5 of the 6 patients showed subcortical T2 hypointensity with the mild hypointense signal on the SWAN sequence

(83.3%) compared with subcortical hypo-intensity seen in 23 of 24 patients (95.8%) in the included studies. The involvement was predominantly in the posterior cerebral regions, i.e., parietal involvement in 83.3% along with frontal, occipital, and temporal involvement in 33.3% patients in our study. Similarly, the posterior cerebral involvement was also predominant in the included studies with occipital involvement being most common (58.3%), followed by parietal (45.8%), temporal (16.6%), and frontal region (16.6%). Postcontrast cortical or leptomeningeal enhancement was reported in 19 of 24 patients (79.2%) in previously published studies.

The comparison of biochemical parameters and MRI findings among various included studies suggests similarity in the published literature except for variability in the cortical signal intensity on FLAIR. The variability in FLAIR signal among various studies could be because of differences in the time from ictus to initial MRI and interobserver and scanner variability in the identification of abnormal cortical signal intensity as described in other etiologies.^[19-21]

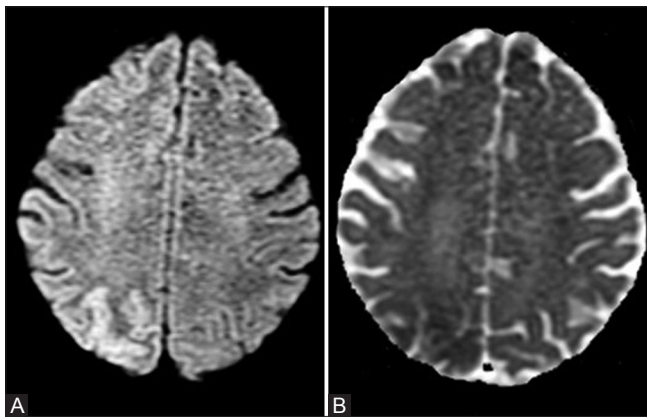


Figure 2 (A and B): Axial DWI (A) image shows cortical hyper-intensity with corresponding low signal on ADC (B) i.e., restricted diffusion involving the right parietooccipital region

Table 3: Comparison for biochemical parameters in various included studies

Study (Year published)	Random blood sugar (mean ± SD)	^a P	Serum osmolality (mean ± SD)	^b P
Seo <i>et al.</i> (2003)	418.3 ± 114.8	0.184	300.8 ± 12.5	0.198
Raghavendra <i>et al.</i> (2007)	405.5 ± 110.6		310 ± 5.9	
Chen <i>et al.</i> (2011)	416.3 ± 76.9		300.3 ± 9.4	
Lee <i>et al.</i> (2016)	391 ± 82.7		309.9 ± 7.7	
Our study (2019)	500.8 ± 64.2		308.1 ± 8.8	

^aP for statistical difference between random blood sugar levels between included studies, ^bP for statistical difference between serum osmolality levels between included studies, SD=Standard deviation

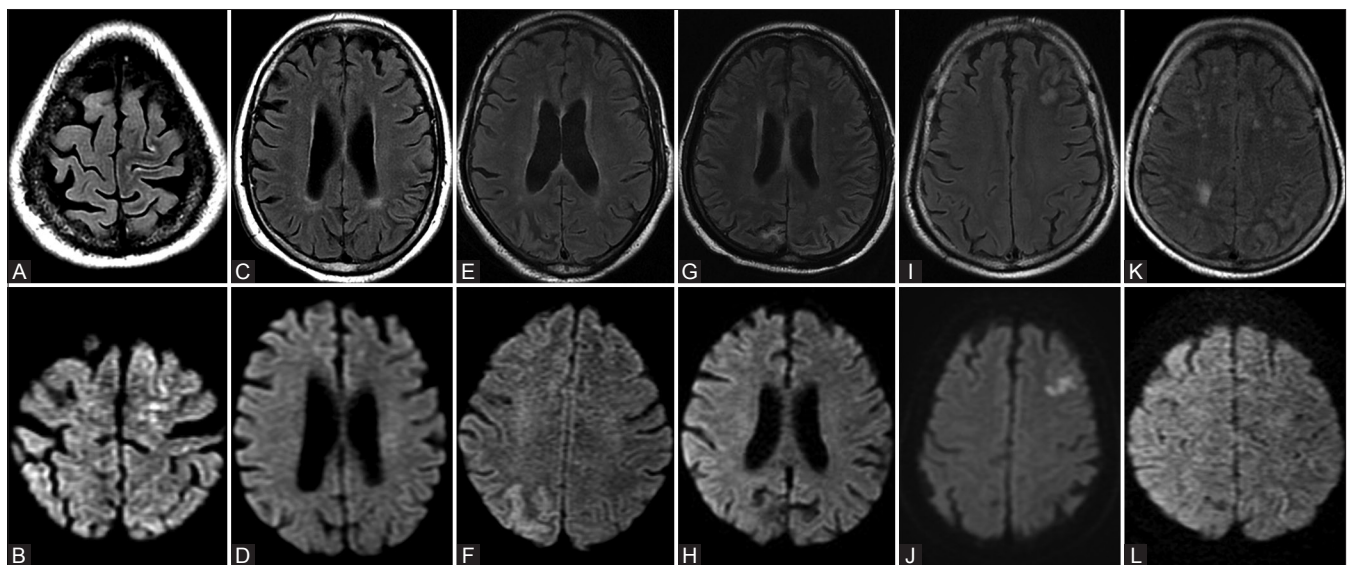


Figure 3 (A-L): The composite image of FLAIR (A, C, E, G, I and K) and DWI (B, D, F, H, J, and L) showing different locations and imaging findings in six patients as described in Table 2

Table 4: Comparison of MRI findings in various included studies

Study (Year published)	Subcortical T2 SI		^a P	Cortical T2 FLAIR SI		^b P	Cortical DWI SI		^c P
	Hypointense	Normal		Hyperintense	Normal		Restriction	Normal	
Seo et al. (2003)	3 (100)	0 (0)	0.522	1 (33.3)	2 (66.7)	0.036	1 (33.3)	2 (66.7)	0.094
Raghavendra et al. (2007)	4 (100)	0 (0)		3 (75)	1 (25)		3 (75)	1 (25)	
Chen et al. (2011)	5 (83.3)	1 (16.7)		6 (100)	0 (0)		6 (100)	0 (0)	
Lee et al. (2016)	11 (100)	0 (0)		5 (45.4)	6 (54.6)		4 (36.3)	7 (63.7)	
Our study (2019)	5 (83.3)	1 (16.7)		6 (100)	0 (0)		4 (66.7)	2 (33.3)	

^aP for statistical difference between subcortical T2 signal intensity between included studies. ^bP for statistical difference between cortical T2 FLAIR signal intensity between included studies. ^cP for statistical difference between cortical diffusion-weighted imaging signal intensity between included studies. MRI=Magnetic resonance imaging, SI=Signal intensity, FLAIR=Fluid attenuation inversion recovery, DWI=Diffusion-weighted imaging

Pathophysiology of seizures and MRI findings

The exact pathophysiology leading to seizures in the hyperglycemic hyperosmolar state is not entirely understood. One of the postulated mechanisms is a decrease in the levels of gamma-aminobutyric acid (GABA) because of depression in glucose utilization and Krebs cycle, thereby elevating alternate pathways of glucose metabolism. These metabolic changes lead to the production of succinic acid from GABA using the succinic–semialdehyde pathway, which supplies up to 40% of the energy requirements of brain tissue.^[7] This decrease in the levels of GABA leads to a reduction in the seizure threshold and proconvulsive state. In contrast, diabetic ketoacidosis has an antiepileptic effect as ketone bodies supply most of the energy requirements of neural tissue. Adenosine triphosphate-sensitive potassium channels (K_{ATP}) with diminished levels of GABA have been incriminated for the effects of increased extracellular glucose levels leading to neuronal hyperexcitability, neuropropagation, and seizures.^[22]

Although a few studies reported no significant abnormalities in the MRI, subcortical T2 hypo-intensity, cortical hyper intensity with restricted diffusion, and cortical or leptomeningeal postcontrast enhancement, predominantly involving parietooccipital region are characteristic findings reported in hyperglycemia-induced seizures.^[12,18,23,24] Most of the previous studies on MRI changes in peri-ictal period, post generalized tonic-clonic seizures, or status epilepticus reported subcortical T2 hyperintensity and in contrast, most studies reported subcortical T2 hypointensity in hyperglycemia-induced seizures.^[18,25,26] The exact pathophysiology leading to subcortical T2 hypo-intensity is not known and many hypotheses have been put forward. The transient deposition of free radicals and/or iron because of excitotoxic axonal damage during hyperglycemia-induced seizures and intracellular dehydration in glial and supporting tissues are postulated mechanisms for subcortical altered signal intensity.^[10,11]

In addition to subcortical T2 hypointensity, hyperglycemia-induced seizures are associated with gyriform restricted diffusion and cortical hyperintensity on T2 and FLAIR. Focal hypoxic-ischemic injury with resultant excitotoxic damage and mitochondrial dysfunction during epileptogenic

activity lead to the failure of Na^+/K^+ ATPase pump, cellular swelling, and cytotoxic edema.^[25] Cytotoxic edema along with hyperperfusion and vasogenic edema results in restricted diffusion and cortical hyperintensity on T2 and FLAIR imaging.^[27-29] Cortical or leptomeningeal postcontrast enhancement could be because of increased perfusion and vascular permeability resulting in loss of blood–brain barrier (BBB) in response to the hypermetabolic state during epileptic activity.^[27-29]

The posterior predilection of involvement in hyperglycemia-induced seizures could be attributed to sympathetic dysautonomia, endothelial damage, and dysfunction leading to altered cerebrovascular reactivity secondary to long-standing diabetes. The regions of involvement are akin to posterior reversible encephalopathy syndrome (PRES) although imaging manifestations differ.^[30]

There are many clinical pathologies associated with subcortical T2 hypointensity other than hyperglycemia-induced seizures, including infectious etiologies, such as meningitis and viral encephalitis; hypoxic-ischemic events, such as hemorrhagic infarct and hypoxic insult; and neoplastic etiology, such as leptomeningeal metastasis.^[31,32] The leptomeningeal enhancement is seen in infectious causes, such as bacterial, viral, and fungal meningitis and neoplastic causes, such as carcinomatous meningitis. Cortical enhancement is observed in vascular causes, such as post-ischemic vasodilatation, seizures, PRES, and migraine, and infectious causes, such as meningitis and encephalitis.^[33,34] Although myriad etiologies present with subcortical T2 hypointensity, cortical hyperintensity, and postcontrast leptomeningeal or cortical enhancement, seizures at initial presentation in the clinical setting of uncontrolled hyperglycemia, hyperosmolar state, and absence of ketone bodies should suggest the possibility of hyperglycemia-induced seizures.

The current study has a few limitations. First is the modest sample size in our study and the included studies and their retrospective nature limiting extrapolation of the findings to the general population. This necessitates a prospective study with a large sample size to address the issue. Second,

the inability to compare postcontrast sequences among the included studies because of lack of contrast-enhanced sequences in our study group. Third, the investigations to rule out all the possible etiologies causing subcortical T2 hypointensity were not performed in all patients because of clinical background at presentation. However, seizure-free course after adequate therapy leaves no scope for alternate diagnosis. Fourth, the lack of follow-up imaging limits the assessment for reversible nature of the imaging findings. Lastly, inability to compare all the biochemical investigations and imaging findings included heterogeneity in the data among the studies.

Conclusion

Our study highlights the presence of posterior predominant subcortical T2, FLAIR, and SWAN hypo-intensity; cortical hyper intensity; and restricted diffusion in hyperglycemia-induced seizures. The awareness of MRI findings in hyperglycemia-induced seizures may facilitate early diagnosis, prevent misdiagnosis and inadvertent invasive workup, and further facilitate the timely administration of appropriate management, as they are usually drug-resistant and respond only after control of elevated blood glucose levels.

Main Points

1. There are myriad etiologies that can present with subcortical T2 hypo signal, including infectious etiologies, such as meningitis and viral encephalitis; hypoxic-ischemic events, such as hemorrhagic infarct and hypoxic insult; and neoplastic etiology, such as leptomeningeal metastasis along with hyperglycemia-induced seizures
2. Seizures at initial presentation in the clinical setting of uncontrolled hyperglycemia, hyperosmolar state, and absence of blood and urinary ketones along with subcortical T2 hypo-intensity most likely represents hyperglycemia-induced seizures. Awareness of this entity helps avoid misdiagnosis, inadvertent invasive workup and initiate appropriate management
3. Although the posterior predominant involvement is hypothesized, analysis of pooled data suggests the presence of the anterior involvement, i.e., signal changes in frontal and temporal lobes are not uncommon
4. The observation of variability in cortical FLAIR signal in the pooled data could possibly be attributed to the differences in the time from ictus to initial MRI, inter-observer, and scanner variability in identification of abnormal cortical signal, which has also been described in other etiologies.

Financial support and sponsorship

Nil.

Conflicts of interest

There are no conflicts of interest.

References

1. Venkatraman R, Singhi SC. Hyperglycemic hyperosmolar nonketotic syndrome. *Indian J Pediatr* 2006;73:55-60.
2. Fishbein HA, Palumbo PJ. Acute metabolic complications in diabetes. In: *Diabetes in America*. National Diabetes Data Group, National Institutes of Health; 1995. p. 283-91 (NIH publ. no. 95-1468).
3. Milionis HJ, Elisaf MS. Therapeutic management of hyperglycaemic hyperosmolar syndrome. *Expert Opin Pharmacother* 2005;6:1841-9.
4. Kitabchi AE, Umpierrez GE, Miles JM, Fisher JN. Hyperglycemic crises in adult patients with diabetes. *Diabetes Care* 2009;32:1335-43.
5. Fadini GP, de Kreutzenberg SV, Rigato M, Brocco S, Marchesan M, Tiengo A, *et al.* Characteristics and outcomes of the hyperglycemic hyperosmolar non-ketotic syndrome in a cohort of 51 consecutive cases at a single center. *Diabetes Res Clin Pract* 2011;94:172-9.
6. Morres CA, Dire DJ. Movement disorders as a manifestation of nonketotic hyperglycemia. *J Emerg Med* 1989;7:359-64.
7. Guisado R, Arieff AI. Neurologic manifestations of diabetic comas: Correlation with biochemical alterations in the brain. *Metabolism* 1975;24:665-79.
8. Placidi F, Floris R, Bozzao A, Romigi A, Baviera ME, Tombini M, *et al.* Ketotic hyperglycemia and epilepsy partialis continua. *Neurology* 2001;57:534-7.
9. Hung WL, Hsieh PF, Lee YC, Chang MH. Occipital lobe seizures related to marked elevation of hemoglobin A1C: Report of two cases. *Seizure* 2010;19:359-62.
10. Lavin PJ. Hyperglycemic hemianopia: A reversible complication of nonketotic hyperglycemia. *Neurology* 2005;65:616-9.
11. Seo DW, Na DG, Na DL, Moon SY, Hong SB. Subcortical hypo-intensity in partial status epilepticus associated with nonketotic hyperglycemia. *J Neuroimaging* 2003;13:259-63.
12. Raghavendra S, Ashalatha R, Thomas SV, Kesavadas C. Focal neuronal loss, reversible subcortical focal T2 hypointensity in seizures with a nonketotic hyperglycemic hyperosmolar state. *Neuroradiology* 2007;49:299-305.
13. Maccario M, Messis CP, Vastola EF. Focal seizures as a manifestation of hyperglycemia without ketoacidosis. A report of seven cases with review of the literature. *Neurology* 1965;15:195-206.
14. Cochin JP, Hannequin D, Delangre T, Guegan-Massardier E, Augustin P. Continuous partial epilepsy disclosing diabetes mellitus. *Rev Neurol* 1994;150:239-41.
15. Tiamkao S, Pratipanawatr T, Tiamkao S, Nitinavakarn B, Chotmongkol V, Jitpimolmard S. Seizures in nonketotic hyperglycemia. *Seizure* 2003;12:409-10.
16. Huang CW, Tsai JJ, Ou HY, Wang ST, Cheng JT, Wu SN, *et al.* Diabetic hyperglycemia is associated with the severity of epileptic seizures in adults. *Epilepsy Res* 2008;79:71-7.
17. Chen CC, Chai JW, Wu CH, Chen WS, Hung HC, Lee SK. Neuroimaging in seizure patients associated with nonketotic hyperglycemia. *Neuroradiol J* 2011;24:215-20.
18. Lee EJ, Kim KK, Lee EK, Lee JE. Characteristic MRI findings in hyper glycaemia-induced seizures: Diagnostic value of contrast-enhanced fluid-attenuated inversion recovery imaging. *Clin Radiol* 2016;71:1240-7.
19. Yetkin FZ, Haughton VM, Fischer ME, Papke RA, Daniels DL, Mark LP, *et al.* High-signal foci on MR images of the brain: Observer variability in their quantification. *AJR Am J Roentgenol* 1992;159:185-8.
20. Havsteen I, Ovesen C, Willer L, Nybing JD, Ægidius K,

- Marstrand J, *et al.* Comparison of 3- and 20-gradient direction diffusion-weighted imaging in a clinical subacute cohort of patients with transient ischemic attack: Application of standard vendor protocols for lesion detection and final infarct size projection. *Front Neurol* 2017;8:691.
21. Guo C, Niu K, Luo Y, Shi L, Wang Z, Zhao M, *et al.* Intra-scanner and inter-scanner reproducibility of automatic white matter hyperintensities quantification. *Front. Neurosci* 2019;13:679.
 22. Huang CW, Huang CC, Cheng JT, Tsai JJ, Wu SN. Glucose and hippocampal neuronal excitability: Role of ATP-sensitive potassium channels. *J Neurosci Res* 2007;85:1468-77.
 23. Younes S, Cherif Y, Aissi M, Alaya W, Berriche O, Boughammoura A, *et al.* Seizures and movement disorders induced by hyperglycemia without ketosis in elderly. *Iran J Neurol* 2014;13:172-6.
 24. Wu YJ, Tsai JJ, Huang CW. Nonketotic hyperglycemia-related reflex epileptic seizures induced by Mah-Jong playing. *Epilepsy Behav* 2010;19:533-5.
 25. Kim JA, Chung JI, Yoon PH, Kim DI, Chung TS, Kim EJ, *et al.* Transient MR signal changes in patients with generalized tonic-clonic seizure or status epilepticus: Peri-ictal diffusion-weighted imaging. *Am J Neuroradiol* 2001;22:1149-60.
 26. Raghavendra S, Ashalatha R, Krishnamoorthy T, Kesavadas C, Thomas SV. Reversible peri-ictal MRI abnormalities: Clinical correlates and long-term outcome in 12 patients. *Epilepsy Res* 2007;73:129-36.
 27. Cole AJ. Status epilepticus and periictal imaging. *Epilepsia* 2004;45:72-7.
 28. Briellmann RS, Wellard RM, Jackson GD. Seizure associated abnormalities in epilepsy: Evidence from MR imaging. *Epilepsia* 2005;46:760-6.
 29. Moritani T, Smoker WRK, Sato Y, Numaguchi Y, Westesson PA. Diffusion-weighted imaging of acute excitotoxic brain injury. *AJNR Am J Neuroradiol* 2005;26:216-28.
 30. Cotton F, Kamoun S, Rety-Jacob F, Tran-Minh VA, Nighoghossian N, Hermier M. Acute hypertensive encephalopathy with widespread small-vessel disease at MRI in a diabetic patient: Pathogenetic hypotheses. *Neuroradiology* 2005;47:599-603.
 31. Putta SL, Weisholtz D, Milligan TA. Occipital seizures and subcortical T2 hypointensity in the setting of hyperglycemia. *Epilepsy Behav Case Rep* 2014;2:96-9.
 32. Lee JH, Na DG, Choi KH, Kim KJ, Ryoo JW, Lee SY, *et al.* Subcortical low intensity on MR images of meningitis, viral encephalitis, and leptomeningeal metastasis. *AJNR Am J Neuroradiol* 2002;23:535-42.
 33. Smirniotopoulos JG, Murphy FM, Rushing EJ, Rees JH, Schroeder JW. Patterns of contrast enhancement in the brain and meninges. *Radiographics* 2007;27:525-52.
 34. Dietemann JL, Correia Bernardo R, Bogorin A, Abu Eid M, Koob M, Nogueira T, *et al.* Normal and abnormal meningeal enhancement: MRI features. *J Radiol* 2005;86:1659-83.