

Niche role of MRI in the evaluation of female infertility

Shabnam Bhandari Grover, Neha Antil, Amit Katyan, Heena Rajani, Hemal Grover¹, Pratima Mittal², Sudha Prasad³

Departments of Radiology and Imaging and ²Obstetrics and Gynecology, Vardhman Mahavir Medical College and Safdarjung Hospital, ³Department of Obstetrics and Gynecology, Maulana Azad Medical College, New Delhi, India, ¹Department of Radiology, Icahn School of Medicine at Mount Sinai West, New York, USA

Correspondence: Dr. Shabnam Bhandari Grover, E-81, Kalkaji, New Delhi - 110 019, India. E-mail: shabnamgrover@yahoo.com

Abstract

Infertility is a major social and clinical problem affecting 13–15% of couples worldwide. The pelvic causes of female infertility are categorized as ovarian disorders, tubal, peritubal disorders, and uterine disorders. Appropriate selection of an imaging modality is essential to accurately diagnose the aetiology of infertility, since the imaging diagnosis directs the appropriate treatment to be instituted. Imaging evaluation begins with hystero-salpingography (HSG), to evaluate fallopian tube patency. Uterine filling defects and contour abnormalities may be discovered at HSG but usually require further characterization with pelvic ultrasound (US), sono-hysterography (syn: hystero-sonography/saline infusion sonography) or pelvic magnetic resonance imaging (MRI), when US remains inconclusive. The major limitation of hystero-graphic US, is its inability to visualize extraluminal pathologies, which are better evaluated by pelvic US and MRI. Although pelvic US is a valuable modality in diagnosing entities comprising the garden variety, however, extensive pelvic inflammatory disease, complex tubo-ovarian pathologies, deep-seated endometriosis deposits with its related complications, Mullerian duct anomalies, uterine synechiae and adenomyosis, often remain unresolved by both transabdominal and transvaginal US. Thus, MRI comes to the rescue and has a niche role in resolving complex adnexal masses, endometriosis, and Mullerian duct anomalies with greater ease. This is a review, based on the authors' experience at tertiary care teaching hospitals and aims to provide an imaging approach towards the abnormalities which are not definitively diagnosed by ultrasound alone.

Key words: Complex tubo-ovarian pathologies; endometriosis; female infertility; HSG; MR imaging; MRI; Mullerian duct anomalies

Introduction

Infertility is defined as the inability of a couple to conceive naturally after one year of regular unprotected sexual intercourse. This clinical entity which bears extreme social relevance affects 13-15% couples globally.^[1-3] Amongst the common causes of female infertility, 30-50% of cases are due to tubal and peritubal disorders, while ovarian disorders account for 30-40% of all cases of female infertility.^[4-7] Imaging modalities available in the Radiologist's

armamentarium include hysterosalpingography (HSG), transabdominal and transvaginal ultrasound, MRI and less commonly sono-hysterography (syn: hystero-sonography/saline infusion sonography). Initial imaging evaluation begins with hysterosalpingography (HSG) to evaluate fallopian tube patency. Uterine filling defects and contour abnormalities may also be delineated at HSG, but usually require further characterization with ultrasound (US) or

This is an open access journal, and articles are distributed under the terms of the Creative Commons Attribution-NonCommercial-ShareAlike 4.0 License, which allows others to remix, tweak, and build upon the work non-commercially, as long as appropriate credit is given and the new creations are licensed under the identical terms.

For reprints contact: reprints@medknow.com

Cite this article as: Grover SB, Antil N, Katyan A, Rajani H, Grover H, Mittal P, *et al.* Niche role of MRI in the evaluation of female infertility. *Indian J Radiol Imaging* 2020;30:32-45.

Received: 13-Sep-2019

Revised: 16-Jan-2020

Accepted: 11-Feb-2020

Published: 30-Mar-2020

Access this article online

Quick Response Code:



Website:
www.ijri.org

DOI:
10.4103/ijri.IJRI_377_19

magnetic resonance imaging (MRI). Pelvic US is a valuable modality in diagnosing entities comprising the garden variety, however, complex tubo-ovarian pathologies, complicated endometriosis, and adenomyosis often remain unresolved by both transabdominal and transvaginal US. In the era of evidence-based medicine, MRI has an indispensable role in the diagnosis and management of female infertility. MRI increases the diagnostic performance of transvaginal sonography in the accurate detection of extensive pelvic inflammation, complex tubo ovarian pathologies, leiomyomas, exact delineation of endometriosis and adenomyosis. MRI provides a pre-surgical mapping of location and vascularity of leiomyomas and guides final management. Definitive diagnosis by MRI, obviates the necessity of invasive diagnostic laparoscopy and hysteroscopy in patients with endometriosis and intrauterine adhesions. Owing to its high spatial resolution, MRI provides accurate anatomical information about Mullerian duct anomalies and is considered to be the standard of care, in such patients.^[8,9] This is a review, based on the authors' experience at tertiary care teaching hospitals and aims to provide an imaging approach towards the abnormalities which are not definitively diagnosed by ultrasound alone.

Pelvic inflammatory disease (PID) and Tubal/peritubal disorders

Pelvic inflammatory disease (PID) is defined as an acute clinical syndrome characterized by acute pelvic pain, vaginal discharge, fever, and leukocytosis. PID is caused by ascending microbial infections, usually due to sexually transmitted microorganisms such as chlamydia trachomatis, Neisseria gonorrhoeae, Mycoplasma genitalium and gram negative bacteria.^[9] The disease, characteristically follows

a sequential pattern of an initial stage of endometritis and salpingitis, which culminates into a late stage of spread of infection into peritubular structures, resulting in the formation of tubo-ovarian abscesses (TOAs). In India, tuberculosis is a frequently encountered aetiology of TOA. It is the late chronic stage of disease which is usually indolent and asymptomatic, that is accidentally discovered in the course of infertility evaluation.

Early stage: Development of endometritis and hydrosalpinx/pyosalpinx

Ascending endometrial infection manifests on HSG as fraying of endometrial margins. The infection progresses to involve the fallopian tubes leading to the formation of adhesions which eventually results in ampullary blockage and tubal dilatation. This inflammatory cascade is detected on US as dilated tubular structures showing incomplete septae and internal echoes associated with wall thickening and profuse vascularity on Color Doppler [Figure 1]. MRI appearances which favour hydrosalpinx, comprise of dilated fallopian tubes which are hypointense on T1W and hyperintense on T2W sequences. In case the condition worsens and a pyosalpinx develops, then T2W sequences show a hyperintense inner tubal rim. Contrast-enhanced MRI features of hyperintense inner tubal rim and heterogeneous contrast enhancement of the tubal walls is diagnostic of pyosalpinx.^[6,7] Our experience shows that additional abnormalities may be detected on MRI, which are critical for changing the management of the patient, as substantiated for the patient illustrated in Figure 1. In this patient, besides pyosalpinx, a cornual fibroid contributing to infertility, was not detected on US, but was well delineated on MRI.

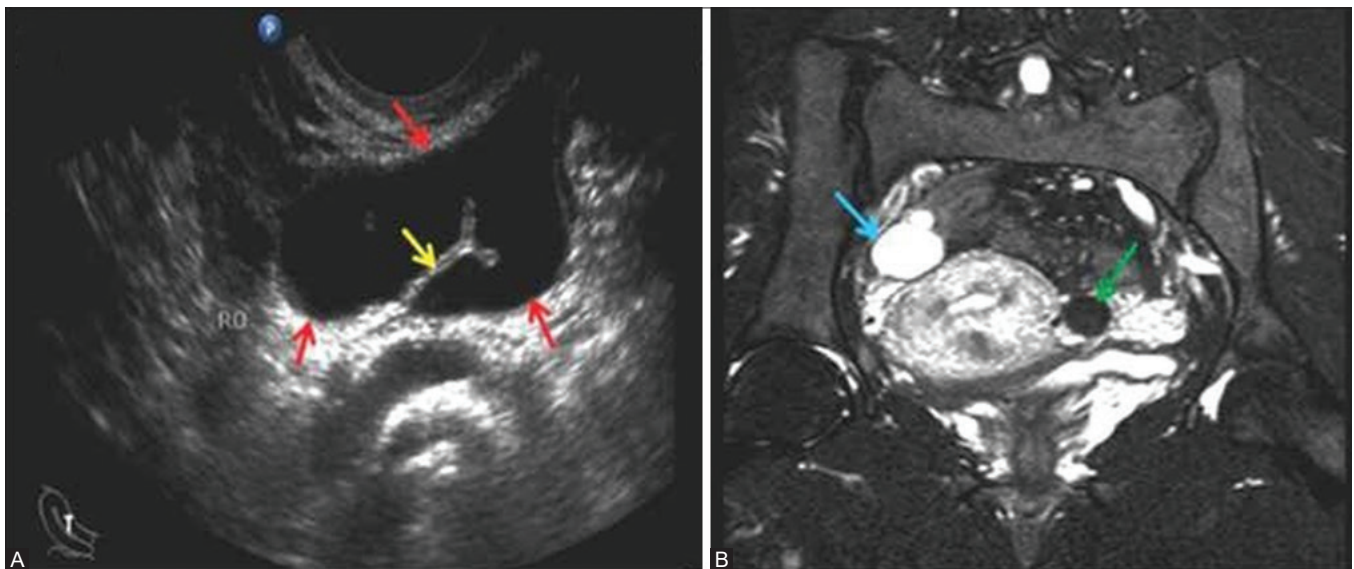


Figure 1 (A and B): Imaging studies (A and B) of a 35-year-old woman with secondary infertility. The transvaginal ultrasound study (A) reveals a right-sided hydrosalpinx (red arrows) showing an incomplete septa within (yellow arrow). MRI pelvis (B) of the same patient reveals a small fibroid at the left cornua of the uterus (green arrow) in addition to the dilated right fallopian tube (hydrosalpinx, blue arrow). The features are characteristic of early stage PID.

Late stage: Development of tubo-ovarian abscesses

Ascending infection spreads to the ovaries and surrounding pelvic structures resulting in the formation of tubo-ovarian abscesses (TOAs).

Sonographic imaging features of TOAs include multilocular complex lesions showing thickened irregular walls, internal debris, and septations. Ovaries and tubes are not distinctly separable in a tubo-ovarian abscess, which is a feature that

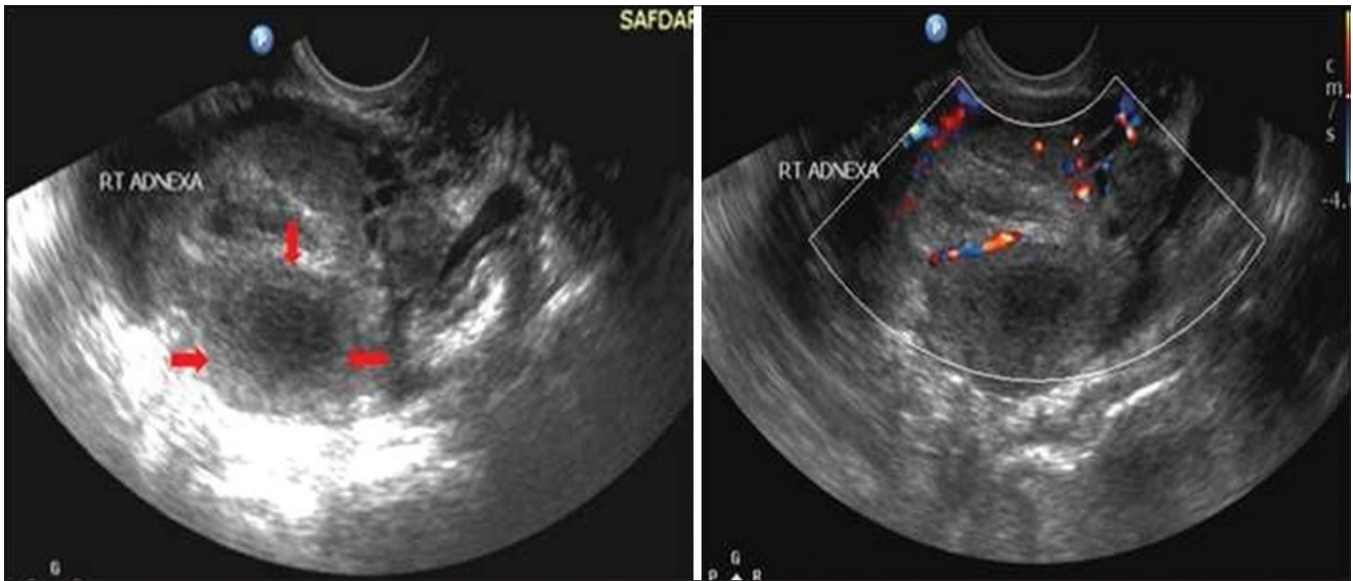


Figure 2: Ultrasound study in a 26-year-old girl, married for years, with primary infertility. In addition, there was a recent history of pelvic pain and fever for 4 months. The ultrasound and color Doppler study reveals a right-sided tubo-ovarian mass (red arrows) with fluid in the pouch of Douglas and increased peripheral vascularity: Features are characteristic of late stage PID, with development of TO abscess.

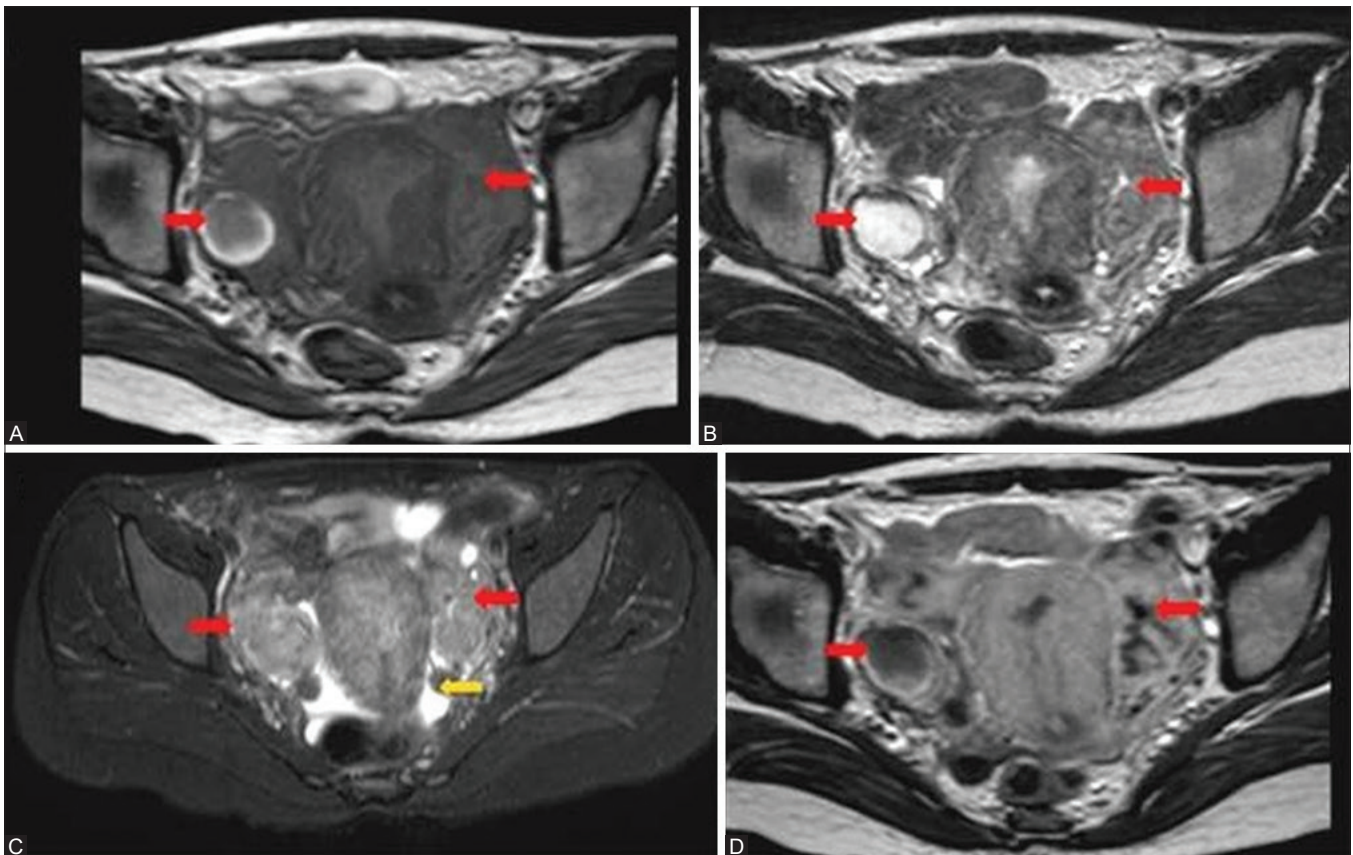


Figure 3 (A-D): MRI study (A-D) of the same patient (as in Figure 2) reveals bilateral enhancing tubo-ovarian abscesses (red arrows) with inflammatory changes in the parametrium along with moderate fluid in the pelvis (yellow arrow). The patient recovered clinically and radiologically after a complete course of antibiotics.

differentiates it from other “adnexal masses.” On color Doppler, tubo-ovarian abscess shows increased peritubal and peri-adnexal vascularity^[6] [Figure 2]. However, ultrasound is frequently unable to detect precise organ involvement and the Color Doppler findings are not always infallible in assessing the activity and stage of disease.

MRI is excellent in not just arriving at a definitive diagnosis in sonographically undiagnosed tubo-ovarian masses, but also in delineating stage, severity, and extent of spread of pelvic inflammatory disease. Characteristic MRI appearances in tubo-ovarian abscesses include, complex cystic solid masses in adnexal region, with ovaries not separately delineated. These lesions appear heterogeneously hypointense on T1W sequences, hyperintense on T2W sequences, and show heterogeneous contrast enhancement of the tubal walls and septae on gadolinium administration. These masses have irregular wall thickening, debris, and internal septations [Figure 3]. MRI is superior to US in determining both tubal and peri-tubal components of PID. Contrast-enhanced MRI provides a unique assessment of the spread of infection along the broad ligament in patients with PID, [Figure 3], which is a critical factor in staging the disease process.^[6,7,10] Subsequently adhesions develop in the parametrium, which also enhance on CE MRI. In patients with right iliac

fossa pain, peri-ovarian fat stranding is also an important feature to distinguish TOA from appendicitis.^[10]

Radiological features of TOA may mimic those of other complex cystic ovarian masses, including hemorrhagic cysts, endometriomas, dermoid cysts, and cystic ovarian neoplasms. The differential diagnosis of all these entities is easily achieved by a multiparametric MRI approach, using a combination of Contrast enhanced MRI and DWI. All the mimicking entities have their own characteristic features on various MRI parameters, which are described in the relevant sections. In our experience and in that of few other Authors, tubercular tubo-ovarian affliction, is an important aetiology as aetiology of TOA and can also present as a mass with ascites as can an ovarian malignancy,^[10,11] In such instances, DWI is relevant, because though ovarian tumors enhance on gadolinium injection akin to TOA, malignant tumors definitely show restricted diffusion on DWI, with significantly lower ADC values. Furthermore, a meticulous exclusion of other sites of tuberculosis, especially the lung parenchyma, is useful in corroborating that the aetiology is likely to be non tubercular.

Various investigators have opined that MRI has a superior sensitivity (95% vs 81%), specificity (89% vs. 78%), and

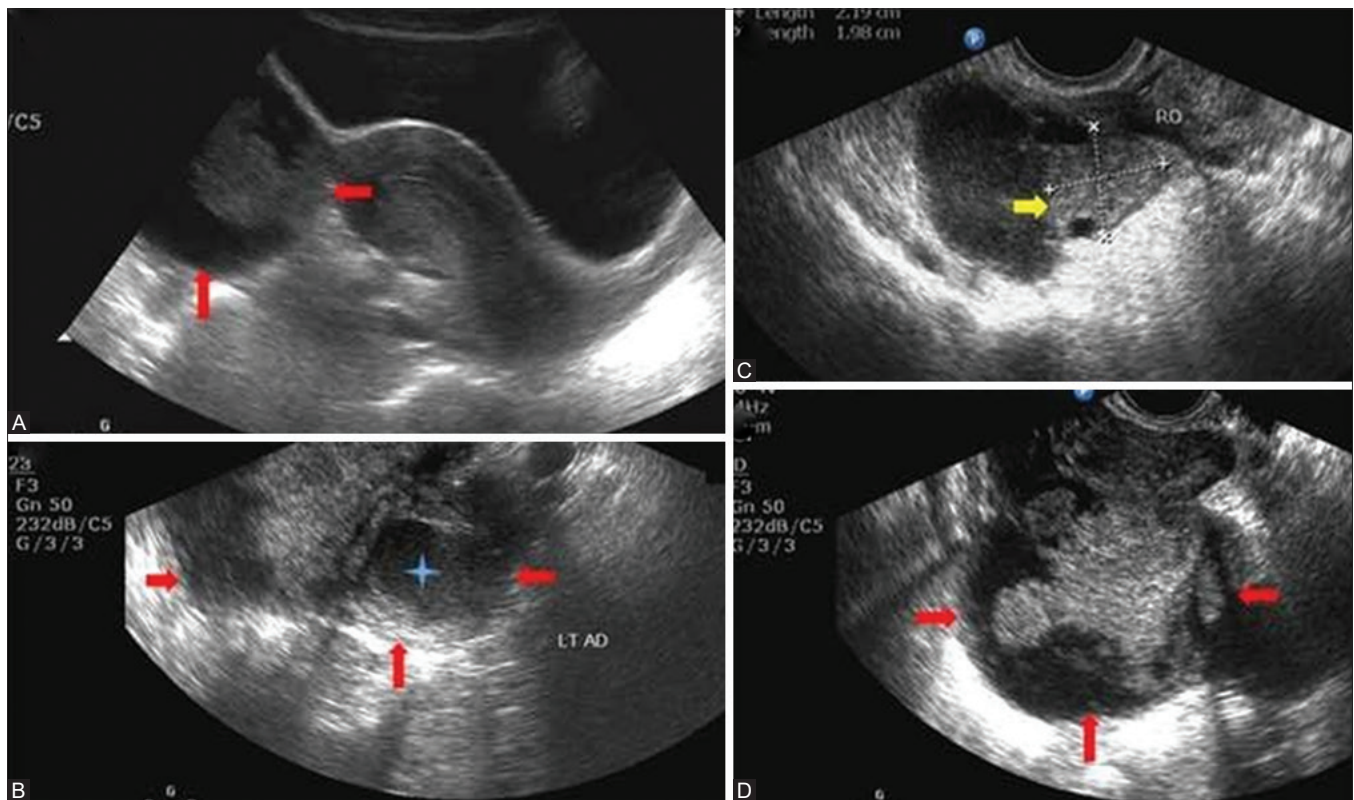


Figure 4 (A-D): Ultrasound study (A-D) of a 35-year-old lady with secondary infertility. Pervaginal examination had revealed bilateral adnexal masses. Ultrasound reveals bilateral large complex adnexal masses with cystic and solid components (red arrows). The right ovary is seen separately from the lesion (yellow arrow). An ill-defined heteroechoic cystic lesion with low-level internal echoes is seen in the left adnexa (blue star). Left ovary not visualized separately.

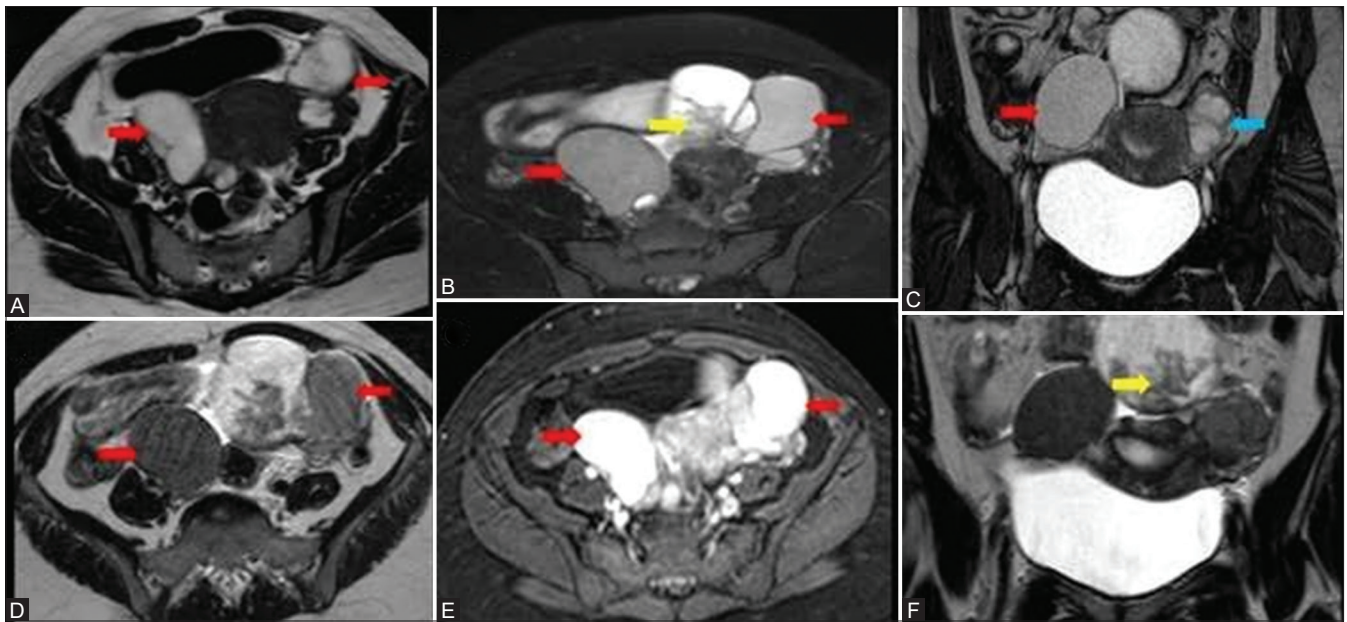


Figure 5 (A-F): MRI study (A-F) of the same patient (as Figure 4) delineates the ovarian and tubal component of the masses with the presence of blood in the dilated tubes (red arrows) suggestive of bilateral hematosalpinx and left ovarian endometrioma (blue arrow) with dependant organized blood clots (yellow arrows).

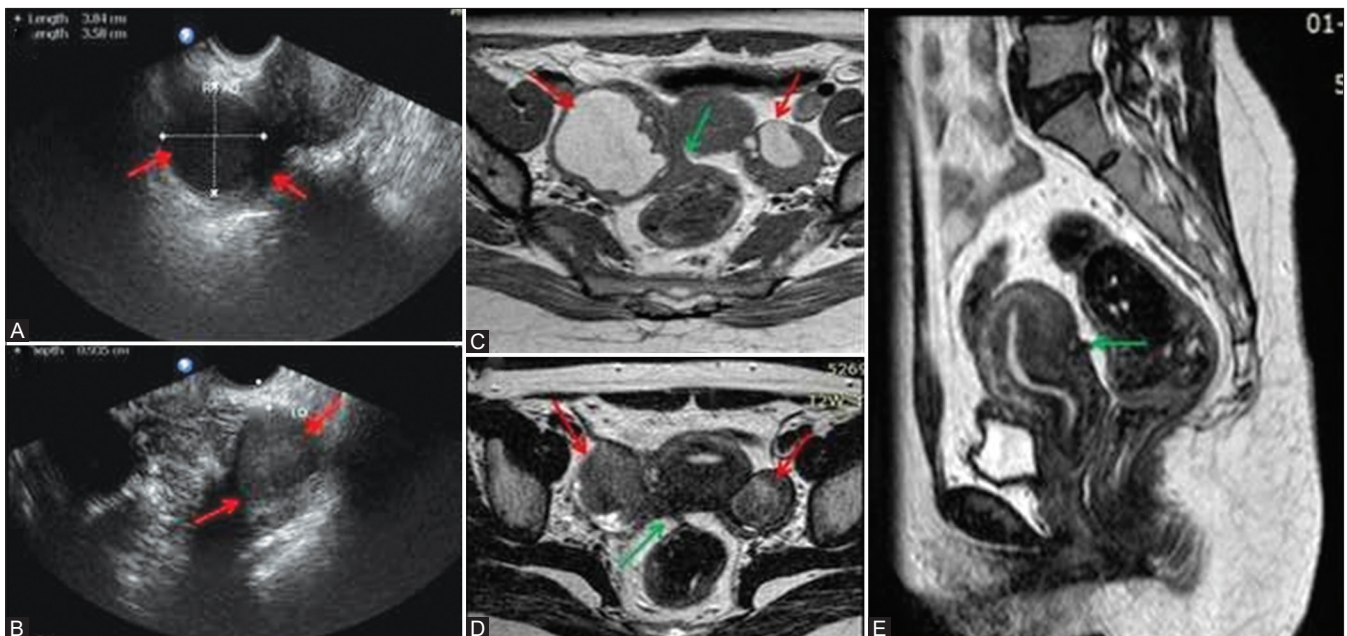


Figure 6 (A-E): Imaging studies (A-E) of a 22-year-old lady with primary infertility. Pervaginal examination had revealed tenderness in the recto-vaginal pouch. Ultrasound examination (A, B) reveals bilateral ovarian cystic masses with homogeneous low-level echoes as contents (red arrows). MRI (C-E) reveals multiple deposits and adhesions (green arrows) in the recto-uterine pouch, along with uterosacral ligament and recto-ovarian adhesion on the right side. The findings were confirmed on laparoscopy as deep infiltrating endometriosis.

overall diagnostic accuracy (93% vs. 80%) for the diagnosis of pelvic inflammatory disease as compared to transvaginal ultrasound. These authors have further concluded that the superior performance of MRI may reduce the need for diagnostic laparoscopy.^[12,13] Diffusion-weighted MRI shows superior sensitivity (100% vs. 47.1%), specificity (97.1% vs. 91.4%), positive predictive value

(97.1% vs. 84.2%), negative predictive value (100% vs 64%), and overall accuracy (98.6% vs. 69.6%) as compared to standard MRI sequences in assessment of tubo-ovarian abscess.^[14] Our experience shows that a Multiparametric approach using both DWI and contrast enhanced MRI is an ideal algorithm for differential diagnosis of ovarian malignancy, endometriosis and TOAs.

Learning points

1. Complex tubo-ovarian masses are unravelled on MRI, which delineates the involved structures. The presence of thick, irregular enhancing walls and the absence of solid components helps in the definitive diagnosis of an infective etiology. Tuberculosis as an aetiology is an important consideration in India.
2. Contrast-enhanced MRI is superior to US in exquisitely delineating the parametrial spread of PID, by the demonstration of abnormal enhancement in this region.
3. DWI MRI provides an accurate differential diagnosis between TOA (pyogenic or tubercular) and malignancy.

Endometriosis

Endometriosis is classically defined as the presence of functional endometrial glands and stroma outside the uterine cavity and its musculature. Patients usually present with infertility, dyspareunia, dysmenorrhea, and chronic

pelvic pain. Endometriosis is categorized depending on the specific organ involvement into ovarian, tubal, peritoneal, and deep infiltrating endometriosis (DIE).^[15] The most common locations for endometriotic deposits are the ovaries, followed by the pouch of Douglas, fallopian tubes, uterosacral ligament, and uterine walls.^[6] In patients with endometriosis, we have found MRI an invaluable modality not only for definitive diagnosis but also for delineation of the extent of disease.

Ovarian endometriosis

Ovaries are the most common site for endometrial deposits and very frequently the involvement is bilateral.^[6] The classical ultrasound appearance of ovarian endometrioma is an adnexal mass with faint internal echoes and highly echogenic mural foci [Figure 4]. The diagnostic MRI features include ovarian cysts of high-signal intensity on both T1- and T2-weighted images or high-signal intensity on T1-weighted images and low signal intensity

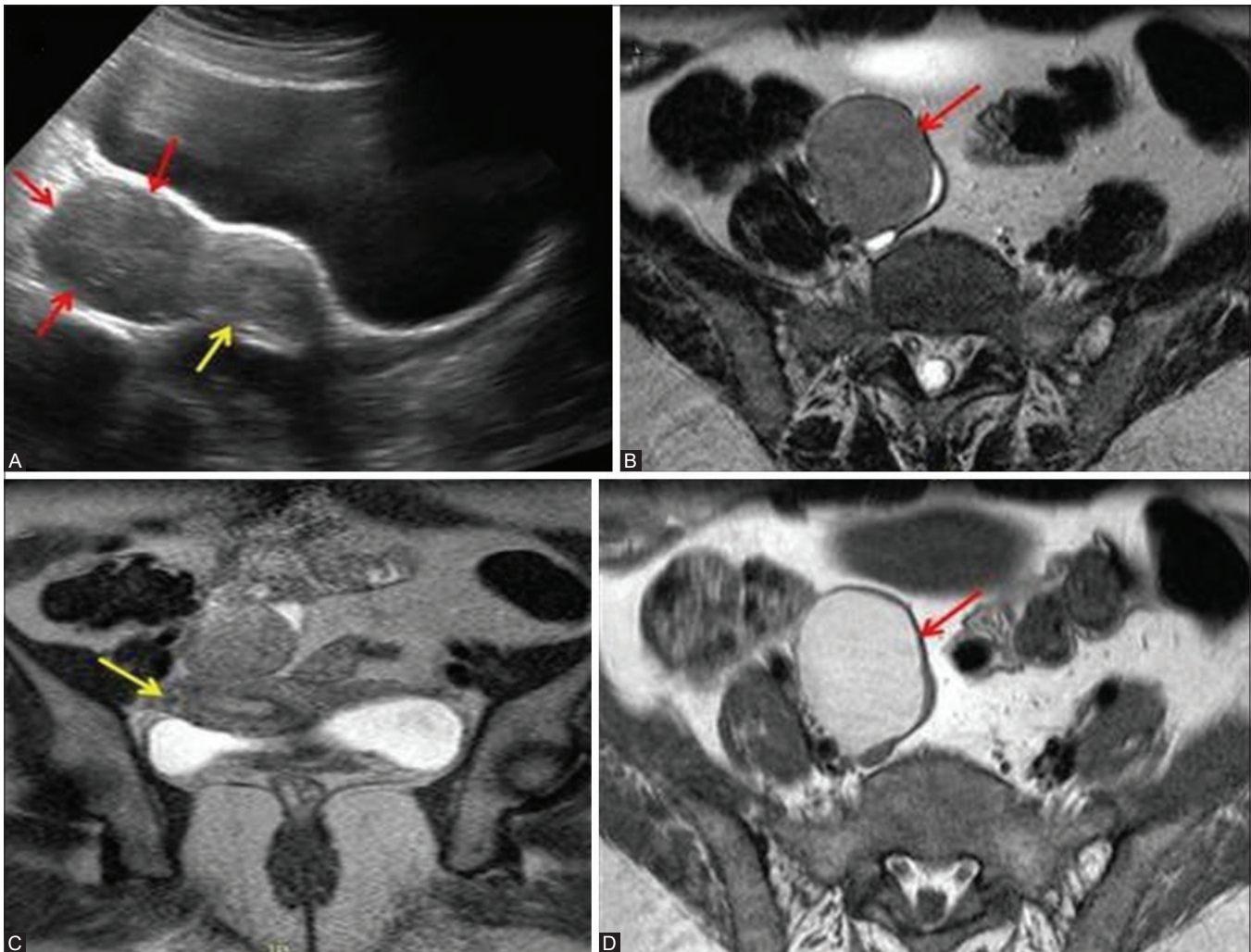


Figure 7 (A-D): Imaging studies (A-D) of a 23-year-old female with primary infertility. Ultrasound (a) shows a well-defined heteroechoic lesion (red arrows) in the right adnexa with low-level internal echoes with a right-sided deviated uterus (yellow arrow). MRI (B-D) shows a unicornuate uterus with a sonographically detected right adnexal lesion (red arrows) showing T1W hyperintense and T2W hypointense signals characteristic of endometrioma.

on T2-weighted images. Additionally, T2W dark spots and T2W shading are highly specific for clinching the diagnosis^[2,4,6,16,17] [Figures 5-7]. Ovarian endometriomas can be easily distinguished from hemorrhagic cyst, cystic teratoma and cystic ovarian tumors, based on their MRI signal characteristics. Haemorrhagic cysts are hyperintense on T1W with the variable signal on T2W sequences, depending on the temporal evolution of the haemorrhage. On US, a complex cystic mass due to a mature teratoma (dermoid), is a mass with echogenic foci, fat fluid levels, and “tip of iceberg sign” (echogenic masses with intense post acoustic shadowing obscuring the posterior border). On MRI, dermoid shows a hyperintense signal on T1W and variable signal on T2W imaging, with a drop of a signal on T1W fat saturation sequences. Cystic ovarian tumors, of malignant origin, show enhancement of solid components on contrast enhanced MRI and restricted diffusion on DWI with significantly low ADC values.

The sensitivity and specificity of MRI for documenting ovarian endometriosis is known to be significantly higher than that of ultrasound and is reported to be 90% and 98%, respectively.^[4,7,18] In contradistinction, the sensitivity of ultrasound is only 45% although its specificity is 99%.^[7]

Tubal endometriosis

Fallopian tubes endometriosis is another major cause of peritubal adhesions in women of reproductive age, resulting in tubal occlusion, and infertility.^[15] High signal on T1-weighted sequences within the tubes, suggests hematosalpinx [Figure 5], which is a sign of endometriosis, even if it is present without evidence of co existing endometriosis elsewhere in the pelvis. MRI is superior to ultrasound as it may help in differentiating hematosalpinx from hydrosalpinx and / or pyosalpinx based on the signal characteristics of fresh and resolving haemorrhage^[15] [Figure 5]. Additionally, There is a specific role of contrast

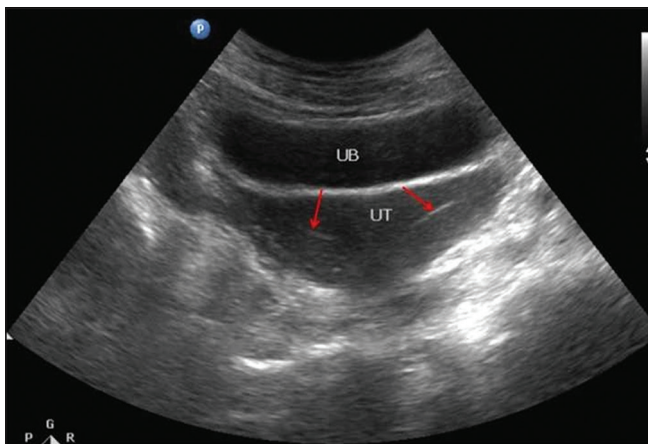


Figure 8: Transabdominal sonography in a 25-year-old female with primary infertility, who presented with acute left pelvic pain reveals two separate endometrial cavities (red arrows).

enhanced MRI for distinguishing endometriosis from tubal infections, TOA and tubal malignancy, as both latter entities enhance post gadolinium injection, as described above. Another MRI feature is that, in infection there is enhancement only of the tubal walls, where as in tubal malignancy, we have found that there is associated enhancement of solid components within the tubes.

Peritoneal and deep infiltrating endometriosis (DIE)

DIE refers to endometriotic peritoneal implants involving a peritoneal depth greater than 5 mm.^[15,16] It most commonly involves the posterior cul-de-sac, which accounts for about 56% of DIE.

MRI findings in posterior cul-de-sac endometriosis include, the presence of macroscopic (>5 mm) endometriotic implants in the pouch of Douglas, asymmetrical thickening of the uterosacral ligament, thickened bands/adhesions between uterus and intestine, obliteration of recto-uterine fat by a fibrous mass, and serosal uterine deposits. As these deposits comprise of blood products in various stages, the signal intensity may vary accordingly. Indirect signs such as retroflexion of the uterus, the elevation of posterior cervical fornix, angulation, and adherence of bowel loops to the posterior surface of the uterus may also be seen.^[15-17] The exquisite demonstration of adhesions in the pelvic cavity, by MRI is well documented in the patient illustrated in Figure 6. Other sites of peritoneal and DIE implants are bowel, bladder surface, round ligaments, and rectouterine ligaments.

MRI has a better diagnostic performance than US for evaluation of recto-uterine endometriosis implants. It is an excellent pre-surgical mapping tool for accurately localizing deep implants located in the rectouterine pouch, posterior vaginal fornix and rectosigmoid surface, bladder surface, and rectouterine ligaments.^[15,17,19] Although MRI has a 90% sensitivity and 91% specificity for evaluating deep-seated endometriosis, laparoscopy continues to be considered as the gold standard, for the confirmation of diagnosis.^[6,16] However, in our experience, laparoscopy needs to reserved only for those patients in whom therapeutic excision of endometriosis implants is being considered.

Learning points

1. High signal on T1 fat-saturated sequences and T2 dark spots (shading) within the lesion are highly suggestive of endometrioma.
2. Contrast enhance MRI is vital in distinguishing endometrioma from enhancing adhesions which occur due to PID.
3. MRI is a superior non-invasive modality for demonstrating the extent of disease, which is vital for pre-surgical mapping of peritoneal and deep-seated deposits.

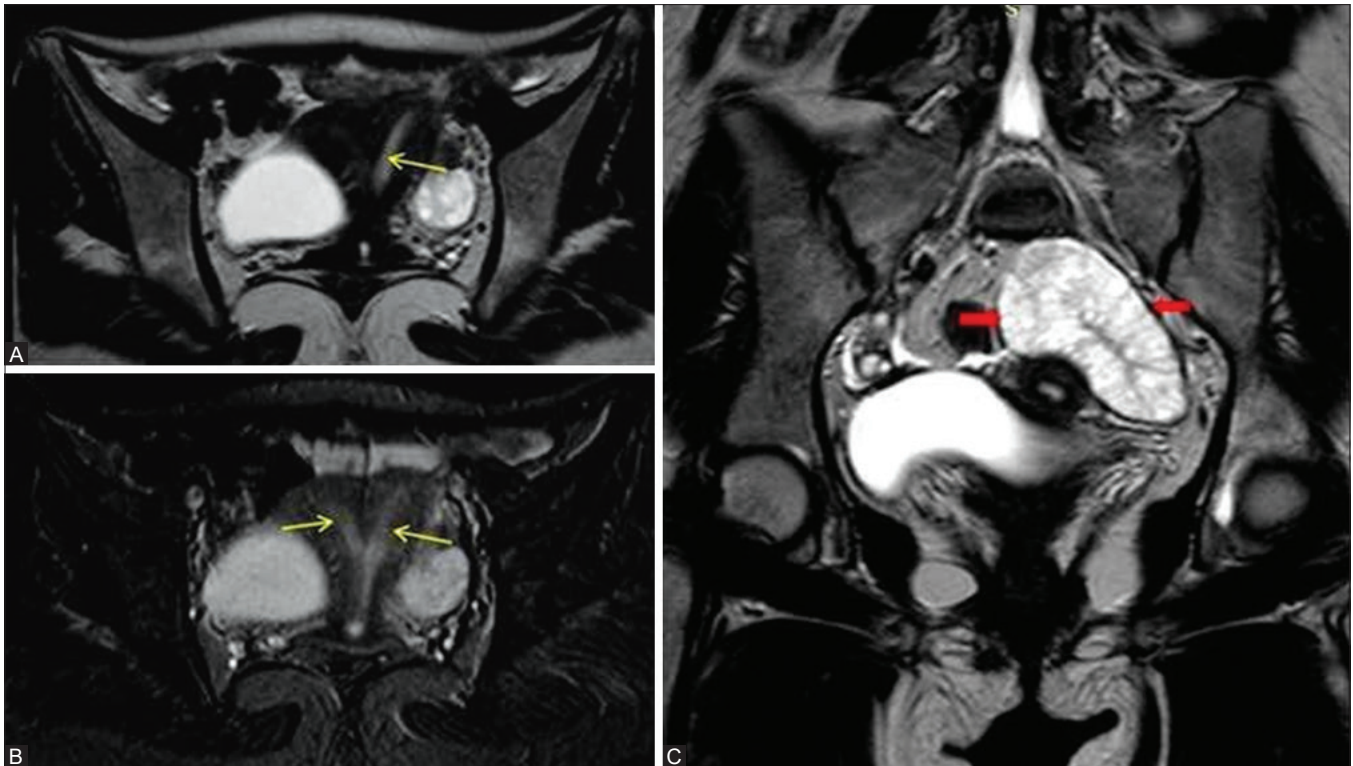


Figure 9 (A-C): MRI study (A-C) of the same patient (as Figure 8) shows a partial septate uterus with two distinct endometrial cavities (yellow arrows) and associated left ovarian torsion (red arrows).

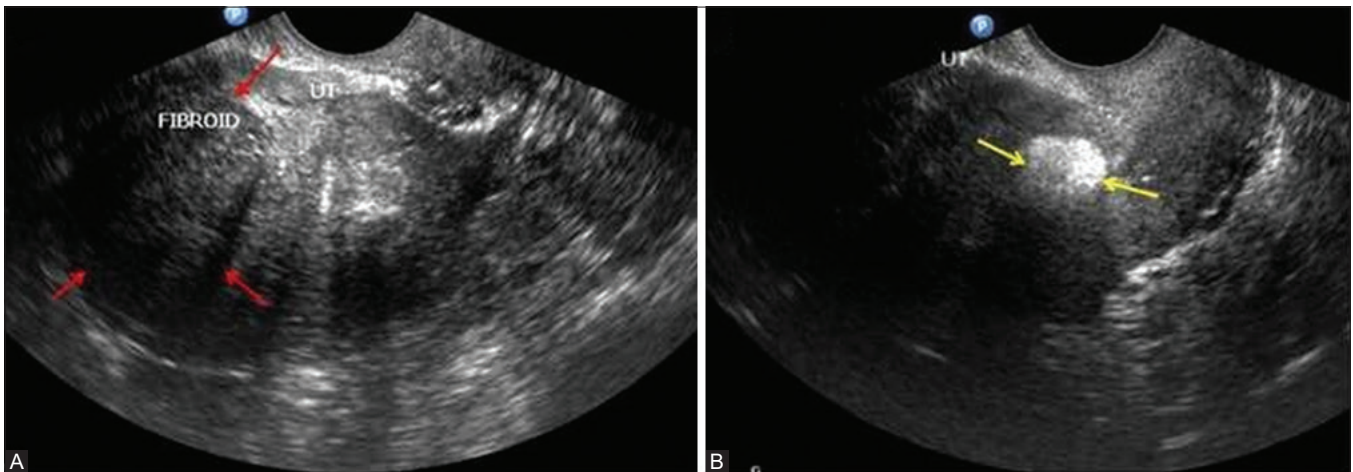


Figure 10 (A and B): Transvaginal sonography (A and B) of a 24-year-old woman with primary infertility shows a large uterine fibroid involving the uterus (red arrows) seen displacing the endometrial cavity. In addition, a well-defined echogenic lesion is seen within the endometrial cavity (yellow arrows) suggestive of endometrial polyp.

Uterine Disorders

Mullerian duct anomalies

Interruption in the Mullerian duct development results in a variety of anomalies referred to as Müllerian duct anomalies (MDAs). It has been observed that about 8% of women presenting with infertility have these anomalies.^[20,21] MDAs have varied clinical presentations which may be useful for characterizing a particular uterine anomaly. Uterine hypoplasia/agenesis presents with primary

amenorrhea. Unicornuate uterus with a connecting or non-connecting rudimentary horn with functional endometrium may present with retrograde bleeding and associated endometriosis [Figure 7]. Uterine didelphys is often associated with higher rate of reproductive complications such as recurrent pregnancy loss, prematurity and intrauterine growth restriction.^[20-23]

The primary investigation that is often requisitioned by obstetricians suspecting MDA is HSG, which allows

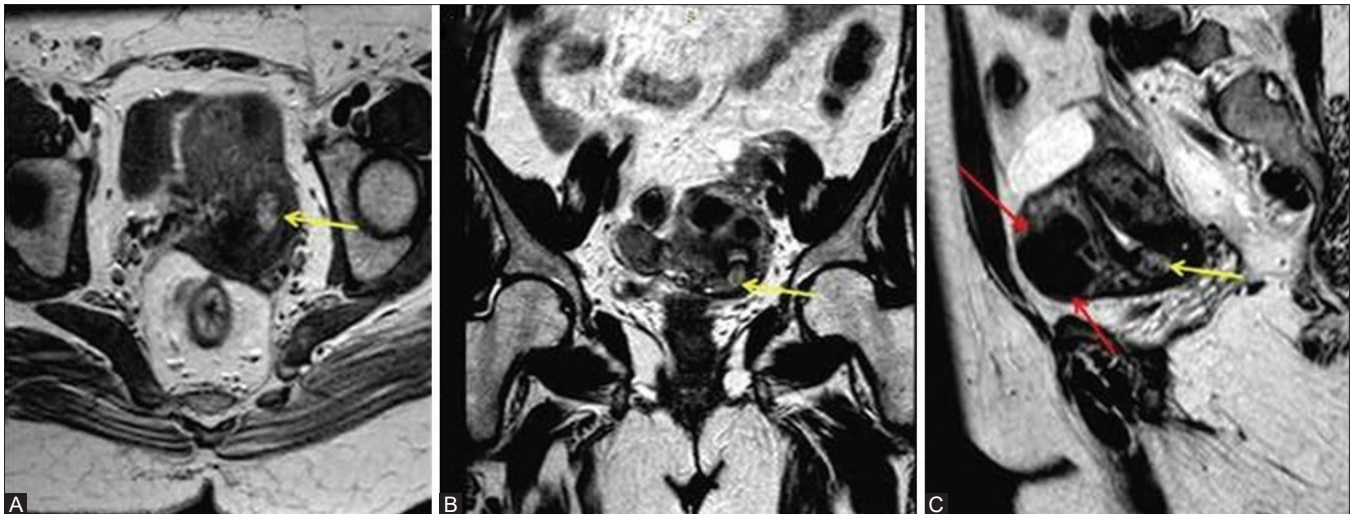


Figure 11 (A-C): MRI pelvis images (A-C) of the same patient (as Figure 10) shows a T2-weighted hyperintense lesion (yellow arrows) within the endometrial cavity in the lower uterine segment suggestive of the endometrial polyp with multiple intramural uterine fibroids (red arrows) obliterating the endometrial cavity. Findings were confirmed at hysteroscopy.

appropriate assessment of uterine cavity and fallopian tube patency, but it is limited in its capability to provide information about the fundal contour. HSG usually raises the suspicion of a uterine anomaly but MRI is required for clear delineation of internal uterine cavity as well as external fundal contour.^[22] The presence of external fundal concavity with a groove of >1 cm depth diverging the two uterine horns and an intercornual distance >4 cm suggests a diagnosis of bicornuate uterus whereas septate uterus has normal convex external fundal contour and an internal fibrous/ muscular septum, which divides uterine cavity into two [Figures 8 and 9]. A fibrous septum is thin and appears hypointense on T2-weighted images, versus a muscular septum, which is thicker and has an intermediate signal intensity on T2-weighted images. Septate and bicornuate uterus need to be differentiated from each other, owing to different therapeutic strategies required for treating these conditions. Patients with septate uterus are managed by hysteroscopic septotomy, whereas a non-surgical approach is generally applied for treating bicornuate uterus. Furthermore, characterization of the septum is equally important, as a fibrous septum is resected hysteroscopically whereas a muscular septum is treated by metroplasty.^[20-22]

Currently, MRI is the modality of choice and has a reported accuracy of up to 100% sensitivity and specificity in the evaluation and classification of MDAs.^[20-22] MR-based classification systems as proposed by all, the European Society of Human Reproduction and Embryology/ European Society for Gynaecological Endoscopy ESHRE/ESGE and those by the American Society for Reproductive Medicine (ASRM) are all currently acceptable. A detailed description of these anomalies are beyond the scope of this article. Few recent reports do cite that 3D ultrasound has similar diagnostic accuracy as MRI in the evaluation of

Mullerian ductal anomalies, but the technique however has a limitation in the lack of wide availability of expertise.^[24] The experience at our Institute shows that, MRI provides an elegant display of mullerian anomalies in all three planes and its easy to comprehend delineation of anatomical structures, makes it an unparalleled tool for radiologists and Gynecologists alike.

Leiomyoma and endometrial polyps

Uterine leiomyoma especially submucosal leiomyomas and even sub-centimetric endometrial polyp may interfere with embryo transfer and implantation leading to recurrent pregnancy loss.^[4,7] MRI can differentiate these entities based on T2-weighted sequence appearances. The diagnostic MRI findings for leiomyomas is a sharply margined mass with low signal on T2W sequences as compared to the myometrium [Figures 10 and 11]. Leiomyomas are usually of low signal intensity on T2W sequences versus endometrial polyps which are hyperintense on T2W sequences [Figures 12 and 13]. For identification of leiomyomas, transvaginal ultrasound can be a reliable method but MRI outperforms transvaginal ultrasound in preoperative evaluation of location, number, and size of leiomyomas. Furthermore, in our own experience, we have found that leiomyomas can coexist with other abnormalities responsible for female infertility and overall result in a multifactorial aetiology, as illustrated above in Figure 1 and also seen in the patients illustrated in Figures 10 and 12.

Studies by Dueholm *et al.* and Levens *et al.*, have also highlighted the role of MRI, in mapping of large volume myomas and in multiple myomas.^[25,26]

Treatment options vary with the location and characteristics of the leiomyomas, which include hysterectomy,

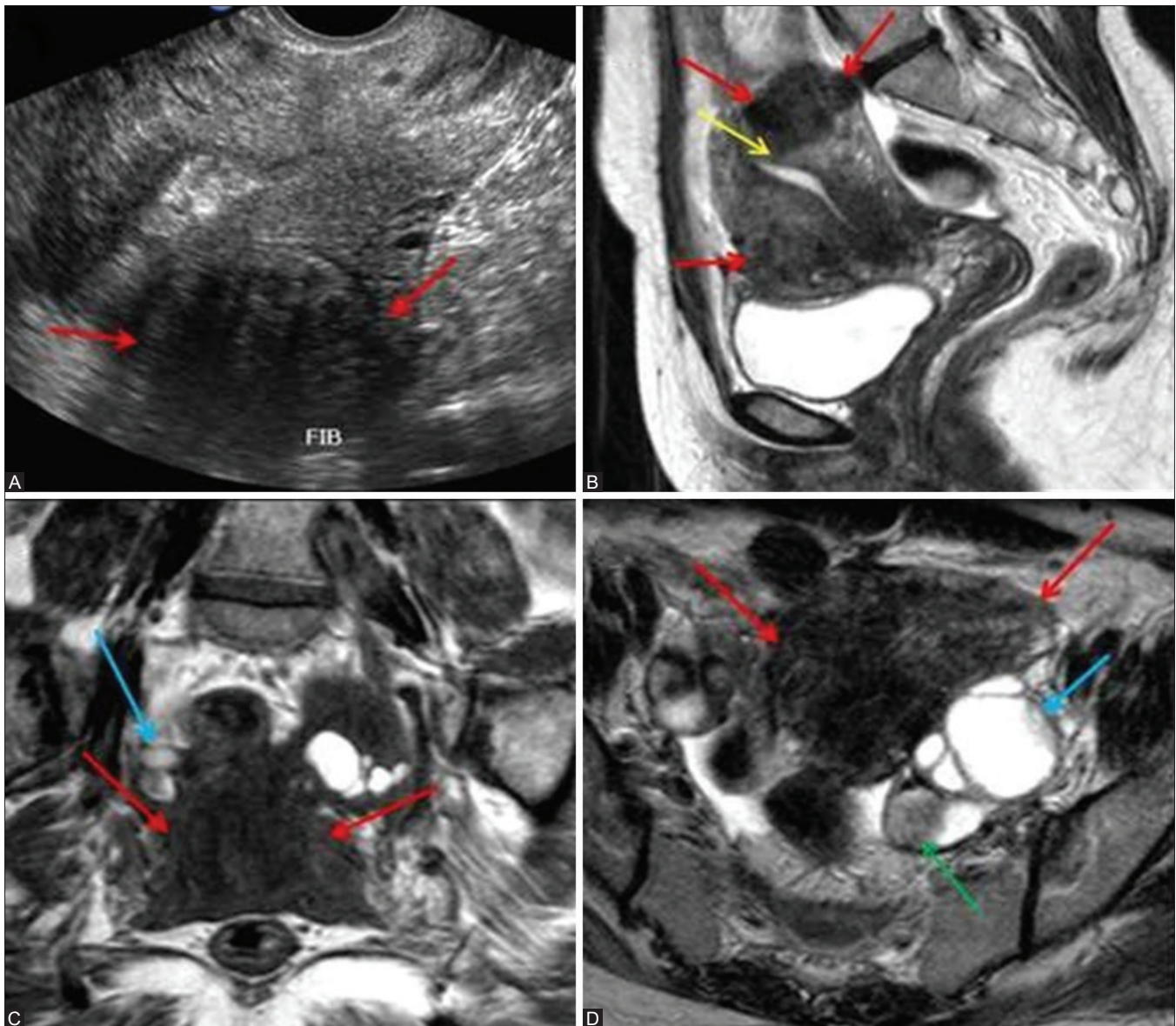


Figure 12 (A-D): Imaging studies (A-D) of a 28-year-old woman with primary infertility. Transvaginal sonography (A) shows a large leiomyoma involving the posterior myometrium. MRI pelvis (B-D) of the same patient shows multiple uterine fibroids (red arrows) which are seen to indent the endometrial cavity (yellow arrow). Multiple ovarian cysts are also seen (blue arrows) along with T2W shading seen in one of the left ovarian cyst (green arrow) suggestive of endometriosis.

myomectomy, hormonal therapy, uterine artery embolization, and laparoscopic radio frequency ablation. Uterine artery embolization can cause volume reduction of submucosal leiomyomas or leiomyomas with vascularity whereas there is no role of uterine artery embolization in leiomyomas with hemorrhagic degeneration and absence of vascularity. Recently, MR-guided focused ultrasound therapy has shown promising results in the management of uterine leiomyomas.^[27] Pedunculated leiomyomas which have an endoluminal protrusion of >50% may have to be resected with hysteroscopic myomectomy. Thus MRI is valuable, both for detection and accurate localization of leiomyomas, all towards planning individualized patient treatment.^[8]

Uterine synechiae

Intrauterine adhesions and synechiae may be the result of previous pregnancy or dilatation and curettage, surgery or infection. Such adhesions appear as irregular filling defects with a distorted endometrial cavity on HSG.^[4,7] Infertility secondary to uterine adhesion is known as Asherman's syndrome.^[4] The absence of a high T2W signal of normal endometrium, associated with luminal obstruction, suggests the diagnosis of Asherman's syndrome. Sonohysterography is currently considered the gold standard for the identification of these intrauterine adhesions.^[4] The role of MRI in the diagnosis of adhesions in Asherman's syndrome has not been widely discussed in the literature. In our experience, the MR appearance

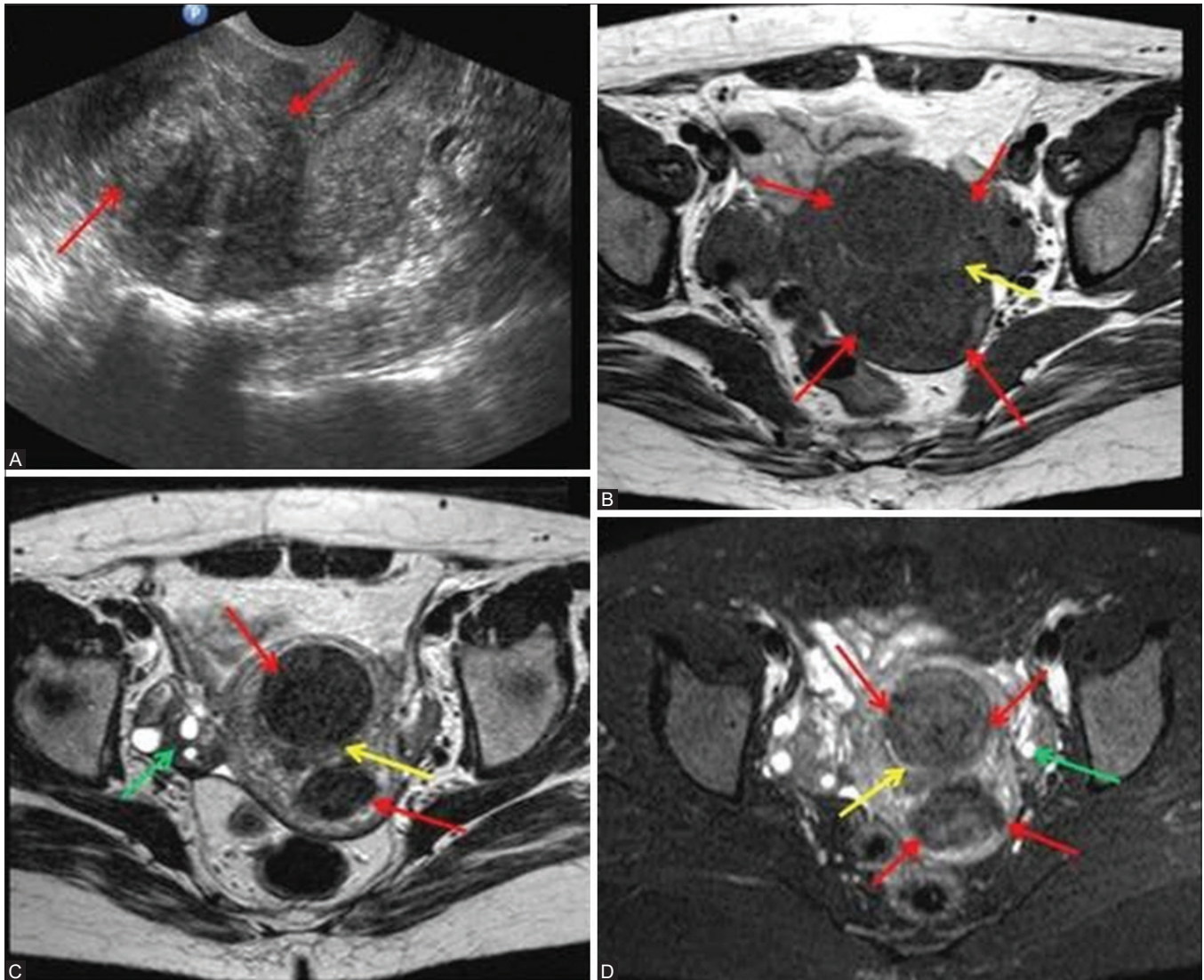


Figure 13 (A-D): Imaging studies (A-D) of a 28-year-old lady with primary infertility. Transvaginal sonography (A) shows multiple uterine fibroids (red arrows) displacing the endometrial cavity. MRI pelvis images (B-D) of the same patient reveals multiple intramural fibroids which are completely obliterating the endometrial cavity (yellow arrows). Both ovaries are normal (green arrows).

of an irregular endometrial cavity on T2W sequences, is a good indicator for the presence of synechiae. In addition, T2W hypointense bands may be seen within the endometrium.^[8] This has been unequivocally and elegantly illustrated by the clinical case examples of our patients, shown in Figures 14 and 15. The patient illustrated in Figure 14 has multiple factors for infertility: endometriosis, fibroid and uterine synechae, all elegantly demonstrated by MRI.

Adenomyosis

Adenomyosis is a benign pathological condition of the uterus, characterized by the presence of ectopic endometrial glands within the myometrium.^[4] US features of adenomyosis include globular uterine enlargement, heterogeneous myometrial echotexture, myometrial cysts, indistinct endometrial-myometrial interface, and

sub-endometrial echogenic nodules or linear striations.^[4,7] A confident US diagnosis may be limited due to the indistinct endometrial-myometrial interface. We have found that, MRI is highly accurate for the diagnosis of adenomyosis and can be used as a problem-solving tool, especially more so when ultrasound findings are equivocal. This same has also been reported in a study by Dueholm *et al.* in 2007 in which MRI was found to have a superior diagnostic performance as compared to ultrasound.^[28] MRI has an added advantage of differentiating adenomyosis from multiple intramural leiomyomas with a reported accuracy of 99%^[4,7] The diagnostic feature of adenomyosis at MRI, is the presence of T2W hypo intense (diffuse or focal) thickening of the junction zone (>12 mm thickness). Additional features are, linear or nodular high signal foci seen in the myometrium, on both T1W and T2W sequences^[4] [Figure 16].

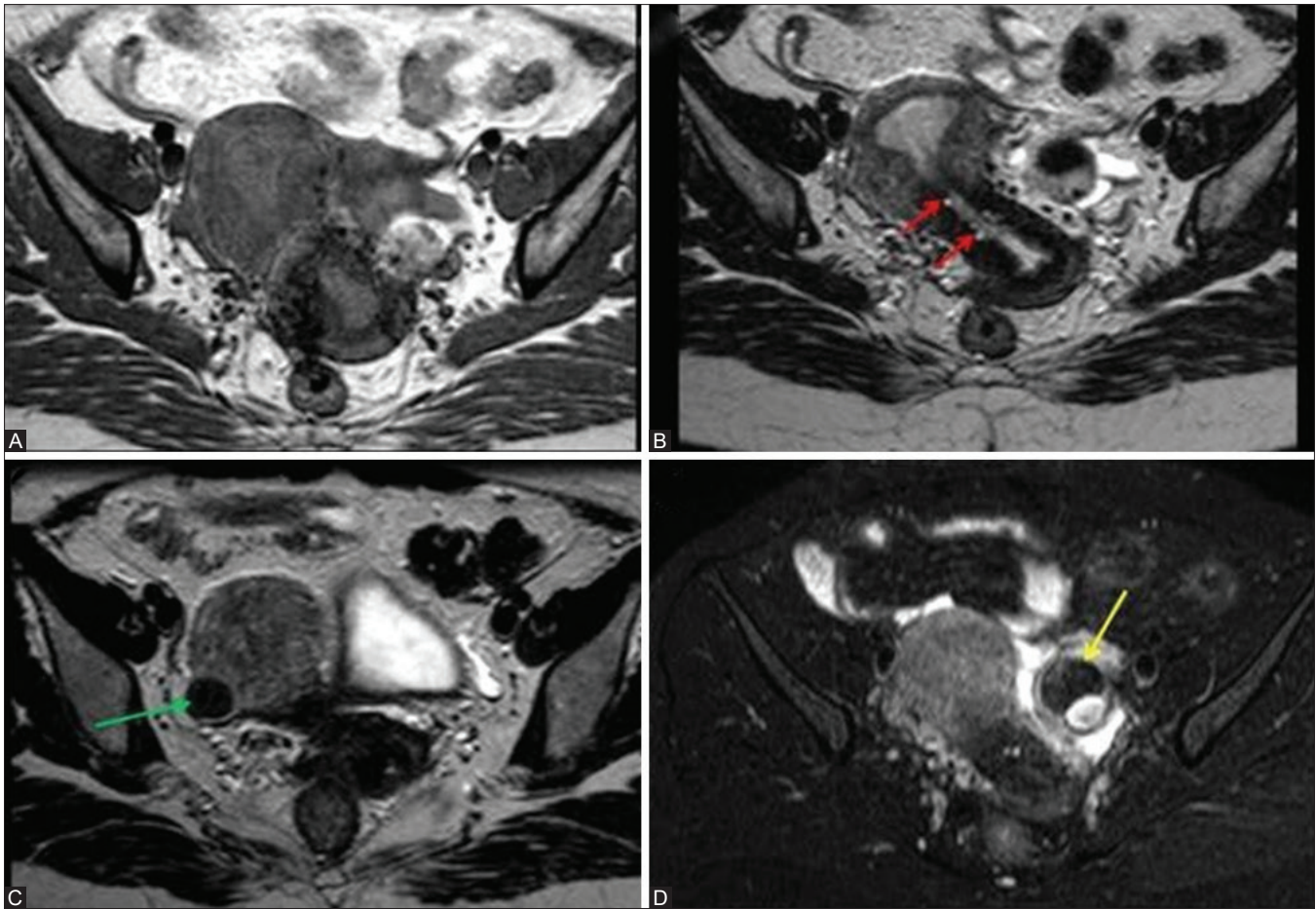


Figure 14 (A-D): MRI pelvis images (A-D) of a 24-year-old female with primary infertility shows a distorted morphology of uterus with an irregular endometrial outline with multiple cysts (red arrows) in the cervix. Multiple endometrial fibrotic bands were found at hysteroscopy. Imaging and hysteroscopic findings were consistent with Asherman's syndrome. (C) uterine fibroid (green arrow) shows characteristic T2W hypointense MRI signal. (D) An ovarian cystic lesion (yellow arrow) shows T2-weighted hypointense signal suggestive of endometrioma.

Learning points

1. MRI is the gold standard in providing anatomical details in patients of MDAs.
2. MRI is the ideal modality for the preoperative mapping of leiomyomas.
3. Uterine synechiae are well delineated by MRI and a diagnostic laparoscopy need not be the primary modality for this entity.
4. Adenomyosis and multiple intramural leiomyomas are easily distinguished by MRI.

Ovarian Disorders

Polycystic ovarian syndrome

Polycystic ovarian syndrome (PCOS) is one of the commonest causes of infertility. Ultrasound is usually sufficient for an accurate assessment of the ovarian morphological alterations in PCOS, namely enlarged ovaries, increased stromal echogenicity and multiple follicular cysts, which are more than 12 in number.^[4] However, it is now well accepted that MRI scores over ultrasound and is more accurate in the assessment of ovarian volume and follicular count.^[29] On

MRI, increased ovarian volume, reduced T2 signal intensity of the central stroma which is characteristically surrounded by small peripheral follicles is seen.^[4]

Conclusions

MRI is an excellent non-invasive, radiation-free modality for the evaluation of female infertility; its superior soft-tissue contrast resolution and multiplanar evaluation generate exquisite anatomical details. The information provided is invaluable in the assessment of tubal and peritubal pathologies, complex tubo-ovarian abscesses and masses, and for the diagnosis and localization of deep-seated endometriosis and its associated complications. In the delineation of Mullerian anomalies and the mapping of uterine leiomyomas, the capability of MRI remains unparalleled in our experience. The diagnostic accuracy of MRI approaches that of diagnostic laparoscopy and hysteroscopy for evaluation of Mullerian duct anomalies and intrauterine synechiae. Furthermore, we have often experienced, that the cause of infertility may be multifactorial and that, majority of coexisting, multiple

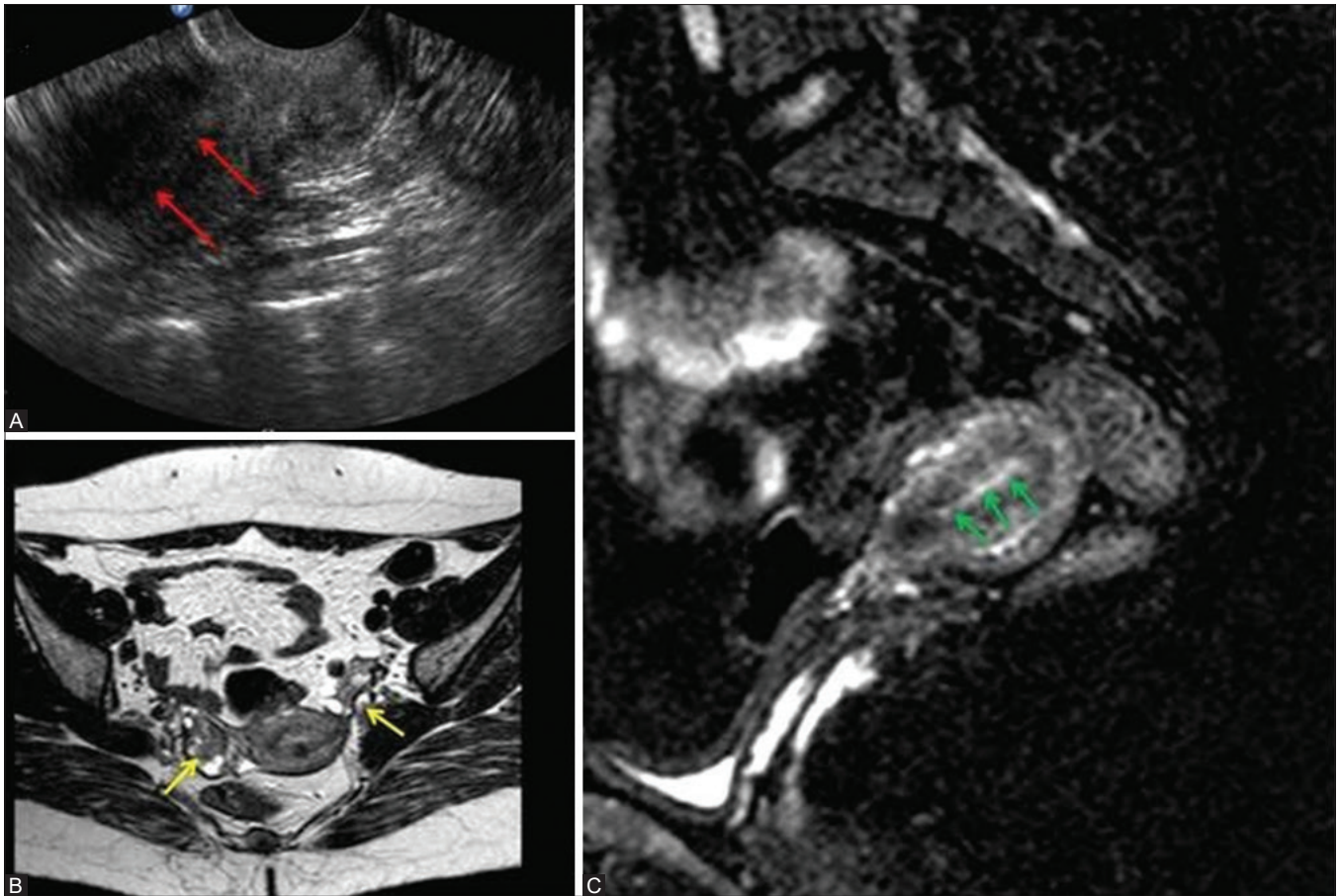


Figure 15 (A-C): Ultrasound (A) and MRI studies (B-C) of a 27-year-old woman with a history of dilatation and curettage showing (A) absent endometrial echo (red arrows) on transvaginal sonography. (C) The uterus shows markedly irregular endometrial cavity (green arrow). Hysteroscopy was performed which showed multiple intrauterine fibrotic bands suggestive of Asherman's syndrome. (C) MRI depicting normal ovaries (yellow arrows).

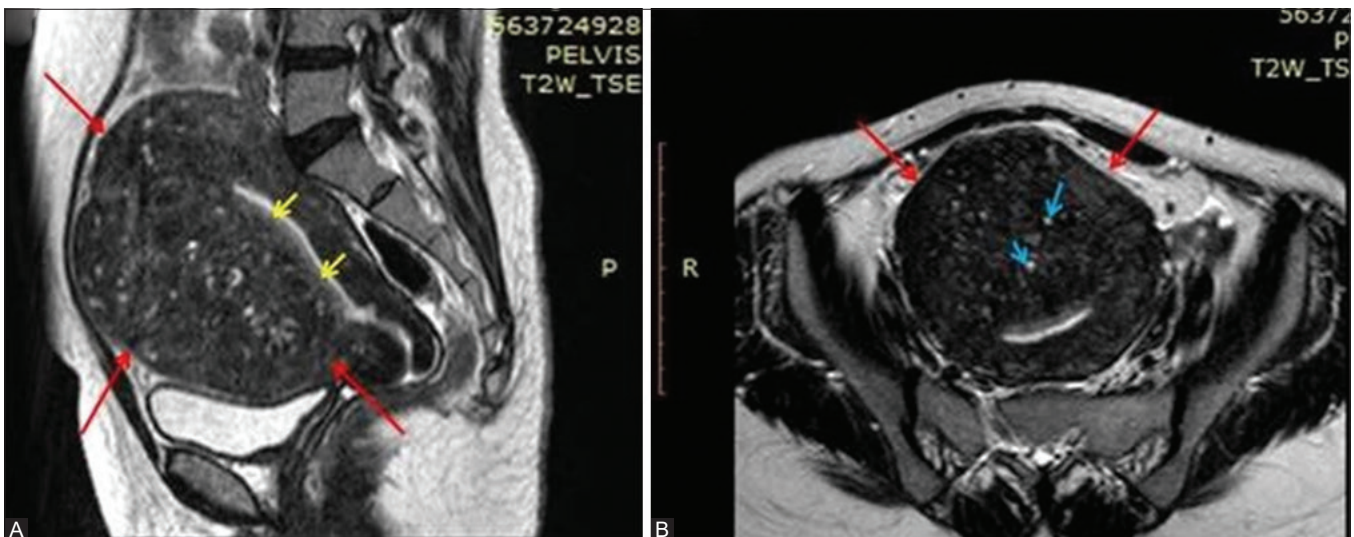


Figure 16 (A and B): Sagittal (A) and axial (B) T2-weighted MRI of a 27-year-old woman with secondary infertility showing an enlarged uterus (red arrows) with ill-defined endomyometrial junction (yellow arrows). Multiple small hyperintense foci (blue arrows) are seen within the uterus, consistent with adenomyosis.

pathologies are better detected with using MRI, as shown in a few of the illustrated cases. Understandably, the

documentation of multifactorial pathology is critical, as each of the delineated abnormalities require specific management

protocols and thereby finally impact the patient outcome. Furthermore, ongoing technological advancements and ever-improving image resolution are very soon likely to place MRI in the domain “basic stethoscope” for female infertility in future.

Financial support and sponsorship

Nil.

Conflicts of interest

There are no conflicts of interest.

References

- Kamel RM. Management of the infertile couple: An evidence-based protocol. *Reprod Biol Endocrinol* 2010;8:21.
- Kaproth-Joslin K, Dogra V. Imaging of female infertility: A pictorial guide to the hysterosalpingography, ultrasonography, and magnetic resonance imaging findings of the congenital and acquired causes of female infertility. *Radiol Clin North Am* 2013;51:967-81.
- Olpin J, Kennedy A. Secondary infertility in women: Radiologic evaluation. *Reports in Medical Imaging* 2011;4:1-14.
- Steinkeler J, Woodfield C, Lazarus E, Hillstrom M. Female infertility: A systematic approach to radiologic imaging and diagnosis. *Radiographics* 2009;29:1353-70.
- Cipolla V, Guerrieri D, Pietrangeli D, Santucci D, Argirò R, de Felice C. Role of 3.0 tesla magnetic resonance hysterosalpingography in the diagnostic work-up of female infertility. *Acta Radiol* 2016;57:1132-9.
- Rastogi R. Role of imaging in female infertility [Dr. K.M. Rai memorial oration award]. *Indian J Radiol Imaging* 2010;20:168-73.
- Imaoka I, Wada A, Matsuo M, Yoshida M, Kitagaki H, Sugimura K. MR imaging of disorders associated with female infertility: Use in diagnosis, treatment, and management. *Radiographics* 2003;23:1401-21.
- Montoliu-Fornas G, Martí-Bonmatí L. Magnetic resonance imaging structured reporting in infertility. *Fertil Steril* 2016;105:1421-31.
- Badawy ME, Elkholi DG, Sherif MF, Hefedah MA. Magnetic resonance imaging for diagnosis of pelvic lesions associated with female infertility. *Middle East Fertil Soc J* 2015;20:165-75.
- Revzin MV, Mathur M, Dave HB, Macer ML, Spektor M. Pelvic inflammatory disease: Multimodality imaging approach with clinical-pathologic correlation. *Radiographics* 2016;36:1579-96.
- Kim SH, Kim SH, Yang DM, Kim KA. Unusual causes of tubo-ovarian abscess: CT and MR imaging findings. *Radiographics* 2004;24:1575-89.
- Sweet RL. Pelvic inflammatory disease: Current concepts of diagnosis and management. *Curr Infect Dis Rep* 2012;14:194-203.
- Tukeva TA, Aronen HJ, Karjalainen PT, Molander P, Paavonen T, Paavonen J. MR imaging in pelvic inflammatory disease: comparison with laparoscopy and US. *Radiology* 1999;210:209-16.
- Wang T, Li W, Wu X, Yin B, Chu C, Ding M, *et al.* Tubo-ovarian abscess (with/without pseudotumor) mimicking ovarian malignancy: Role of diffusion weighted MR imaging with apparent diffusion coefficient values. *PLoS One* 2016;11:e0149318.
- Manganaro L, Anastasi E, Vinci V, Saldari M, Bernardo S, Sollazzo P, *et al.* Endometriosis: 10 key points for MRI. *J Endometr Pelvic Pain Disord* 2015;7:10-8.
- Wall D, Javitt M, Glanc P, Bhosale P, Harisinghani M, Harris R, *et al.* ACR appropriateness criteria® infertility. *Ultrasound Q* 2015;31:37-44.
- Lo GM, Wenger JM, Petignat P, Marci R. Role of imaging in endometriosis. *Clev Clin J Med* 2014;81:361-6.
- Kinkel K, Frei K, Balleyguier C, Chapron C. Diagnosis of endometriosis with imaging: A review. *Eur Radiol* 2005;16:285-98.
- Siegelman ES, Oliver ER. MR imaging of endometriosis: Ten imaging pearls. *Radiographics* 2012;32:1675-91.
- Troiano R, McCarthy S. Müllerian duct anomalies: Imaging and clinical issues. *Radiology* 2004;233:19-34.
- Behr S, Courtier J, Qayyum A. Imaging of müllerian duct anomalies. *Radiographics* 2012;32:E233-50.
- El Ameen NF, Ebraheem MA, El Dien NM. MR assessment of müllerian duct anomalies: Does it help? *Egypt J Radiol Nucl Med* 2014;45:561-7.
- Olpin JD, Moeni A, Willmore RJ, Heilbrun ME. MR imaging of müllerian fusion anomalies. *Magn Reson Imaging Clin* 2017;25:563-75.
- Bermejo C, Ten PM, Cantarero R, Diaz D, Pedregosa P, Barron E, *et al.* Three dimensional ultrasound in the diagnosis of müllerian duct anomalies and concordance with magnetic resonance imaging. *Ultrasound Obstet Gynecol* 2010;35:593-601.
- Dueholm M, Lundorf E, Hansen ES, Ledertoug S, Olesen F. Accuracy of magnetic resonance imaging and transvaginal ultrasonography in the diagnosis, mapping and measurement of uterine myomas. *Am J Obstet Gynecol* 2002;186:409-15.
- Levens ED, Wesley R, Premkumar A, Blocker W, Nieman LK. Magnetic resonance imaging and transvaginal ultrasound for determining fibroid burden: Implications for research and clinical care. *Am J Obstet Gynecol* 2009;200:537e1-7.
- Hindley J, Gedroyc WM, Regan L, Stewart E, Tempny C, Hynnen K, *et al.* MRI Guidance of focused ultrasound therapy of uterine fibroids: Early results. *AJR Am J Roentgenol* 2004;183:1713-9.
- Dueholm, Margit, Lundorf, Erik. Transvaginal ultrasound or MRI for diagnosis of adenomyosis. *Curr Opin Obstet Gynecol* 2007;19:505-12.
- Kenigsberg L, Agarwal C, Sin S, Shifteh K, Isasi C, Crespi R, *et al.* Clinical utility of magnetic resonance imaging and ultrasonography for diagnosis of polycystic ovary syndrome in adolescent girls. *Fertil Steril* 2015;104:1302-9.