

Effect of valproic acid on survival in glioblastoma: A prospective single-arm study

Deepthi Valiyaveetil, Monica Malik, Deepa M. Joseph, Syed Fayaz Ahmed, Syed Akram Kothwal, M. Vijayasaradhi¹

Abstract

Background: Retrospective evidence suggests that valproic acid (VPA), an antiepileptic drug, is associated with improved outcomes in glioblastoma. The exact mechanism of interaction of VPA with radiation and temozolomide (TMZ) is still unclear. Laboratory studies show that VPA can enhance tumor cell kill while at the same time protect the normal neural tissue. The aim of this study was to prospectively evaluate the benefit of VPA on outcomes in glioblastoma.

Materials and Methods: In this single-arm prospective study, patients of glioblastoma were started on seizure prophylaxis with VPA (15–20 mg/kg/day) following maximal safe resection. All patients were treated with chemoradiation to a dose of 60 Gy in 30 fractions with concurrent TMZ followed by adjuvant TMZ for 6 cycles. VPA was continued during adjuvant treatment and follow-up. Survival analysis was done using Kaplan–Meier analysis. **Results:** Twenty patients were enrolled in the study. Median age was 47 years. M:F ratio was 3:1. Treatment was well tolerated with no grade 3/4 adverse events. 8/20 patients experience seizure episodes during treatment and/or follow-up which needed additional antiepileptic drugs for control. Median progression-free survival (PFS) and overall survival (OS) were 10 months and 16 months, respectively. Younger patients (age ≤ 45 years) showed a significantly better OS (25 months) versus older patients (8 months) ($P = 0.002$). **Conclusions:** Incidence of seizures on VPA prophylaxis was 40%. Median PFS and OS were comparable to historical controls. There was no significant treatment-related toxicity. The results need validation in larger prospective randomized studies.

Key words: Chemoradiation, glioblastoma, survival, valproic acid

Introduction

Gliomas are the most common primary malignant brain tumors in adults, and they can occur anywhere in the central nervous system but primarily occur in the brain and arise in the glial tissue.^[1] Standard treatment of glioblastoma consists of maximal safe tumor resection followed by external beam radiation therapy (EBRT) with concurrent and adjuvant temozolomide (TMZ) chemotherapy. This multimodality treatment yields a median survival of 14.6 months, with 2- and 5-year survival rates of 27.2% and 9.8%, respectively.^[2] To cure or even to improve the survival of patients with glioblastoma beyond 2 years remains an elusive goal.^[3]

The pattern of recurrence following concurrent chemoradiation indicates failure in or adjacent to the initial RT treatment volume, suggesting that enhancing the effectiveness of RT could lead to an improved therapeutic response. A number of strategies for modifying the delivery of RT^[4–6] have been tried, without an improvement in survival. The use of drugs to modify radiosensitivity in patients with glioblastoma has been extensively studied.

There is evidence that malignant gliomas are driven by epigenetic aberrations.^[7] Histone acetylases and deacetylases (HDAC) are important in the epigenetic control of tumor cells and are involved in the regulation of cell growth, differentiation, and oncogenesis. Inhibition of HDAC causes tumor cell differentiation, apoptosis, and growth arrest.^[8,9] Histone deacetylase (HDAC) inhibitors have been shown to sensitize cancer cells to ionizing radiation while protecting normal cells and tissues from deleterious effects of RT.^[10]

Valproic acid (VPA), a commonly used drug for treating epilepsy, has emerged as a promising agent for cancer treatment in recent years. It has also been identified as a potent selective HDAC inhibitor (HDACI), which induces cellular

differentiation, growth arrest, and apoptosis in gliomas and other types of cancers.^[11]

VPA has been tested as an HDACI in numerous preclinical and clinical trials for solid tumors and leukemias.^[12,13] It has also been evident in recent investigations that VPA enhanced the apoptotic cell death by TMZ in human glioma cell lines.^[13]

The aim of the study was to evaluate the effect of VPA on survival in glioblastoma patients receiving adjuvant chemoradiation.

Materials and Methods

Newly diagnosed patients of glioblastoma aged 18–75 years with Eastern Cooperative Oncology Group (ECOG) performance status of 0–3 were started on VPA (15–20 mg/kg/day) for seizure prophylaxis following maximal safe resection.

All patients received EBRT to a dose of 60 Gy in 30 fractions with 3DCRT/IMRT technique, 5 fractions per week along with concurrent TMZ 75 mg/m²/day during RT. Radiation target volume was defined as T1-contrast tumor volume with a margin of 1–1.5 cm encompassing the peritumoral edema.

Baseline investigations including blood counts, liver and renal chemistries, and chest radiograph were done. Any seizure episode or any other adverse event leading to break in treatment was documented. During treatment, blood parameters were monitored using weekly blood counts, liver and renal chemistries.

Patient characteristics analyzed were age at diagnosis, ECOG performance status, radiation therapy oncology group recursive partitioning analysis (RPA) class, extent of surgery, number of cycles of adjuvant chemotherapy given, seizure episodes during and post-RT, and requirement for additional antiepileptics.

Statistical analysis of progression-free and overall survival (OS) was done using Kaplan–Meier survival curves using SPSS statistical software (Version 20) (IBM).

This is an open access journal, and articles are distributed under the terms of the Creative Commons Attribution-NonCommercial-ShareAlike 4.0 License, which allows others to remix, tweak, and build upon the work non-commercially, as long as appropriate credit is given and the new creations are licensed under the identical terms.

For reprints contact: reprints@medknow.com

How to cite this article: Valiyaveetil D, Malik M, Joseph DM, Ahmed SF, Kothwal SA, Vijayasaradhi M. Effect of valproic acid on survival in glioblastoma: A prospective single-arm study. South Asian J Cancer 2018;7:159–62.

Access this article online

Quick Response Code:



Website: www.sajc.org

DOI: 10.4103/sajc.sajc_188_17

Departments of Radiation Oncology and
¹Neurosurgery, Nizam's Institute of Medical Sciences,
Hyderabad, Telangana, India

Correspondence to: Dr. Monica Malik,
E-mail: dr_monica11@yahoo.com

Results

A total of twenty patients were enrolled for the study. The median age was 47 years (range 19–68 years). Male:female ratio was 3:1. Most common presentation is headache in 15 patients, seizures in six patients, and hemiparesis in four patients. Other symptoms were vomiting, altered sensorium, urinary incontinence, and speech disturbances. Most of the patients were evaluated at a local center by computed tomography (CT) or magnetic resonance imaging. Most of the patients showed a heterogeneously enhancing mass lesion with edema. Five patients had noncontrast-enhancing lesion. They later underwent maximum safe resection with subtotal excision being done in most of the patients (50%). Most patients had postoperative CT scan done on the day of surgery to rule out bleed. Patient characteristics have been documented in Table 1.

All patients completed the planned course of chemoradiation without any significant treatment interruptions. All patients received concurrent chemoradiation with TMZ (75 mg/m²). It was well tolerated without any grade 3/4 toxicities. Most patients received 500 mg twice daily dose. There were no significant toxicities related to VPA, namely, hepatotoxicity or hematological toxicity. Median number of cycles of adjuvant chemotherapy given was 2.8.

Eight patients experienced seizure episodes, two during the chemoradiation and six during adjuvant chemotherapy. Clobazam (5–20 mg orally once/twice daily) was added in the eight patients and subsequently tapered and stopped after control of seizures.

Median OS was 16 months [Figure 1a]. Median progression-free survival (PFS) was 10 months [Figure 1b]. Age was significantly associated with survival outcomes. Median survival of younger patients (age ≤45 years) was 25 months versus 8 months in older patients (log-rank $P = 0.002$) [Figure 1c]. Patients with RPA class III, IV, and V had median OS of 18 months, 11 months, and 6 months, respectively.

Discussion

Despite extensive research into multimodality management of glioblastoma, the outcomes have been dismal. The prognosis of glioblastoma multiforme (GBM) has not improved significantly over the last few decades despite increases in the number of treatments available.^[14]

In our study, 6 out of twenty patients presented with seizures. Approximately 30%–50% of glioblastoma patients will experience seizure episodes before surgery and 6%–45% experience seizures after diagnosis.^[15] There is evidence to suggest that these patients with a history of seizures have a better prognosis than patients without seizures, which raises questions about whether the antiepileptic drugs (AEDs), especially those with antitumor functions, play a role in this process. Many considerations support thoughtful use of AEDs in patients with gliomas, including the resistance of the seizures, drug-to-drug interactions, and side effects.^[16,17]

In our study, median OS was 16 months, and median PFS was 10 months. Age was significantly associated with survival outcomes. VPA has shown to be associated with improved

Table 1: Patient characteristics

Characteristics	Number of patients (%)
Age (year)	
Range	19-68
Median	47.1
Sex	
Ratio	3:1
Male	15 (75)
Female	5 (25)
RPA	
III	6 (30)
IV	12 (60)
V	2 (10)
Resection	
NTE	4 (20)
GTE	6 (30)
STE/biopsy	10 (50)
ECOG PS	
1	6 (30)
2	12 (60)
3	2 (10)
4	0
Presentation	
Headache	15
Seizures	6
Hemiparesis	4
Vomiting	5
Altered sensorium	1
Other	3

RPA=Recursive partitioning analysis, NTE=Near-total excision, GTE=Gross total excision, STE=Subtotal excision, ECOG PS=Eastern Cooperative Oncology Group performance status

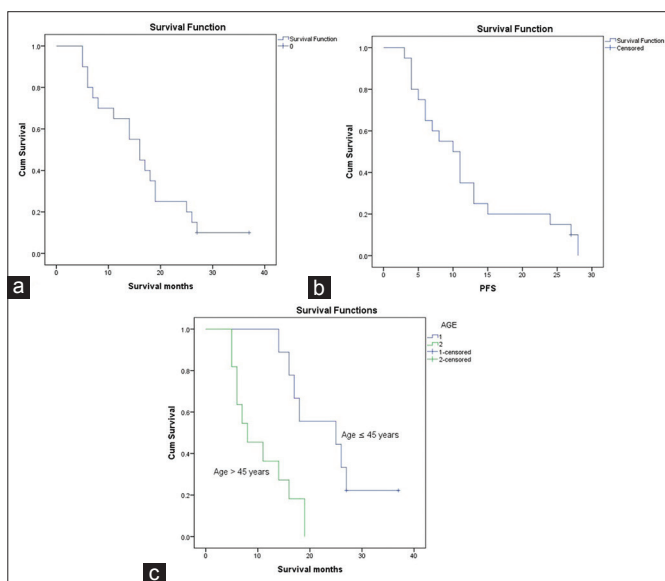


Figure 1: (a) Kaplan–Meier survival curve of median overall survival. (b) Kaplan–Meier survival curve of progression-free survival. (c) Kaplan–Meier survival curve with age as covariate

survival in glioblastoma patients in many retrospective and a few prospective studies.

An EORTC trial^[18] to study the effect of VPA on survival in glioblastoma patients treated with chemoradiation concluded that VPA-treated patients may have better outcome than patients receiving enzyme-inducing AEDs. This may be due to the interaction between VPA and TMZ along with RT, inhibition of HDAC by VPA, and VPA-induced autophagy of glioma cells.

Better acetylation of histones allows greater effectiveness of chemotherapy with TMZ during radiation.

In a study published by Barker *et al.*,^[19] patients receiving VPA and TMZ during RT had a median OS of 23.9 months compared with 15.1 months in patients not receiving VPA. There was also a greater prevalence of seizure history among the patients using VPA compared to other AEDs. There was a higher incidence of seizures in our study (40%) on prophylaxis with VPA. Seizure control was achieved by adding another antiepileptic in some patients which was later weaned off with control of seizures.

The reason that VPA use could possibly prolong the survival time of glioblastoma patients is still unclear, and many complex mechanisms have been postulated. Wen and Schiff^[20] suggested that VPA could possibly increase the bioavailability of TMZ by decreasing its clearance by 5% whereas phenytoin being an enzyme inducer will result in increased clearance of the drug.

A prospective phase 2 study by Krauze *et al.*,^[21] evaluating the effect of VPA in glioblastoma patients treated with concurrent chemoradiation, showed a median OS of 29.6 months and PFS of 10.5 months. The VPA dose in their study was 25 mg/m². There was a 32% grade 3 or 4 hematological toxicity. Our study did not reveal any grade 3/4 toxicity probably due to lower doses of VPA. Similar to our study, this study also showed that younger patients had significantly better overall and PFS.

A recent pooled analysis of survival association of AED use at the start of chemoradiation with TMZ combined patient cohort ($n = 1869$) data from four contemporary randomized clinical trials in newly diagnosed glioblastoma.^[22] Contrary to the results from the retrospective data available, they concluded that VPA use at the start of and after chemoradiotherapy was not associated with improved PFS or OS compared to all other patients pooled. Based on their results, the use of VPA or levetiracetam for reasons other than seizure control is not justified outside of clinical trials.

Fay *et al.*,^[23] in a subsequent correspondence, suggested caution against drawing firm conclusions from the pooled analysis, as the trials included were not equipped to answer the question of whether VPA improves survival in GBM. Dose of VPA was not controlled or reported for in these trials. There is emerging data that higher doses may be required for potential anticancer benefit with VPA.

Limitations of our study include the small sample size, no randomization, and the lack of information regarding MGMT promoter methylation, IDH1 mutational status, and other potential prognostic factors.

The indication and choice of AED in the perioperative period depended on the local practice. The duration of use of AEDs before RT was not recorded.

Conclusions

Median survival of the patients in this study was 16 months with younger patients showing a significantly better median OS of 25 months. VPA was well tolerated with concurrent and adjuvant chemoradiotherapy with no grade 3/4 toxicities. Further large prospective randomized trials should be conducted taking into account all the prognostic factors for validating South Asian Journal of Cancer ♦ Volume 7 ♦ Issue 3 ♦ July-September 2018

the benefits of VPA on survival in glioblastoma. Dose for the maximum anticancer benefit of VPA needs to be further investigated.

Financial support and sponsorship

Nil.

Conflicts of interest

There are no conflicts of interest.

References

- Ostrom QT, Gittleman H, Farah P, Ondracek A, Chen Y, Wolinsky Y, *et al.* CBTRUS statistical report: Primary brain and central nervous system tumors diagnosed in the United States in 2006-2010. *Neuro Oncol* 2013;15 Suppl 2:ii1-56.
- Stupp R, Hegi ME, Mason WP, van den Bent MJ, Taphoorn MJ, Janzer RC, *et al.* Effects of radiotherapy with concomitant and adjuvant temozolomide versus radiotherapy alone on survival in glioblastoma in a randomised phase III study: 5-year analysis of the EORTC-NCIC trial. *Lancet Oncol* 2009;10:459-66.
- Guthrie GD, Eljamel S. Impact of particular antiepileptic drugs on the survival of patients with glioblastoma multiforme. *J Neurosurg* 2013;118:859-65.
- Binello E, Green S, Germano IM. Radiosurgery for high-grade glioma. *Surg Neurol Int* 2012;3:S118-26.
- Nieder C, Andratschke N, Wiedenmann N, Busch R, Grosu AL, Molls M, *et al.* Radiotherapy for high-grade gliomas. Does altered fractionation improve the outcome? *Strahlenther Onkol* 2004;180:401-7.
- Waters JD, Rose B, Gonda DD, Scanderbeg DJ, Russell M, Alksne JF, *et al.* Immediate post-operative brachytherapy prior to irradiation and temozolomide for newly diagnosed glioblastoma. *J Neurooncol* 2013;113:467-77.
- Cancer Genome Atlas Research Network. Comprehensive genomic characterization defines human glioblastoma genes and core pathways. *Nature* 2008;455:1061-8.
- Knüpfner MM, Pulzer F, Schindler I, Hernaiz Driever P, Knüpfner H, Keller E, *et al.* Different effects of valproic acid on proliferation and migration of malignant glioma cells *in vitro*. *Anticancer Res* 2001;21:347-51.
- Shao Y, Gao Z, Marks PA, Jiang X. Apoptotic and autophagic cell death induced by histone deacetylase inhibitors. *Proc Natl Acad Sci U S A* 2004;101:18030-5.
- Munshi A, Kurland JF, Nishikawa T, Tanaka T, Hobbs ML, Tucker SL, *et al.* Histone deacetylase inhibitors radiosensitize human melanoma cells by suppressing DNA repair activity. *Clin Cancer Res* 2005;11:4912-22.
- Michaelis M, Doerr HW, Cinatl J Jr. Valproic acid as anti-cancer drug. *Curr Pharm Des* 2007;13:3378-93.
- Kuendgen A, Gattermann N. Valproic acid for the treatment of myeloid malignancies. *Cancer* 2007;110:943-54.
- Duenas-Gonzalez A, Candelaria M, Perez-Plascencia C, Perez-Cardenas E, de la Cruz-Hernandez E, Herrera LA, *et al.* Valproic acid as epigenetic cancer drug: Preclinical, clinical and transcriptional effects on solid tumors. *Cancer Treat Rev* 2008;34:206-22.
- Huang Z, Cheng L, Guryanova OA, Wu Q, Bao S. Cancer stem cells in glioblastoma – Molecular signaling and therapeutic targeting. *Protein Cell* 2010;1:638-55.
- van Breemen MS, Wilms EB, Vecht CJ. Epilepsy in patients with brain tumours: Epidemiology, mechanisms, and management. *Lancet Neurol* 2007;6:421-30.
- Wick W, Menn O, Meisner C, Steinbach J, Hermisson M, Tatagiba M, *et al.* Pharmacotherapy of epileptic seizures in glioma patients: Who, when, why and how long? *Onkologie* 2005;28:391-6.
- Glantz MJ, Cole BF, Forsyth PA, Recht LD, Wen PY, Chamberlain MC, *et al.* Practice parameter: Anticonvulsant prophylaxis in patients with newly diagnosed brain tumors. Report of the Quality Standards Subcommittee of the American Academy of Neurology. *Neurology* 2000;54:1886-93.
- Weller M, Gorlia T, Cairncross JG, van den Bent MJ, Mason W, Belanger K, *et al.* Prolonged survival with valproic acid use in the EORTC/NCIC temozolomide trial for glioblastoma. *Neurology* 2011;77:1156-64.
- Barker CA, Bishop AJ, Chang M, Beal K, Chan TA. Valproic acid use during radiation therapy for glioblastoma associated with improved survival. *Int J Radiat Oncol Biol Phys* 2013;86:504-9.
- Wen PY, Schiff D. Valproic acid as the AED of choice for patients with glioblastoma? The jury is out. *Neurology* 2011;77:1114-5.
- Krauze AV, Myrehaug SD, Chang MG, Holdford DJ, Smith S, Shih J, *et al.* A phase 2 study of concurrent radiation therapy, temozolomide, and the

- histone deacetylase inhibitor valproic acid for patients with glioblastoma. *Int J Radiat Oncol Biol Phys* 2015;92:986-92.
22. Hapold C, Gorlia T, Chinot O, Gilbert MR, Nabors LB, Wick W, *et al.* Does valproic acid or levetiracetam improve survival in glioblastoma? A Pooled analysis of prospective clinical trials in newly diagnosed glioblastoma. *J Clin Oncol* 2016;34:731-9.
23. Fay MF, Head R, Sminia P, Dowson N, Cosgrove L, Rose SE, *et al.* Valproate in adjuvant glioblastoma treatment. *J Clin Oncol* 2016;34:3105-7.