

## Letter to the Editor

### Metastasizing Pleomorphic Adenoma - Case reports and review of literature

DOI: 10.4103/sajc.sajc\_19\_19

Dear Editor,

Pleomorphic adenoma (PA) is the most common tumor of salivary glands. Among all salivary gland tumors, benign Metastasizing Pleomorphic Adenoma (MPA) constitutes an extremely rare group of tumors. Histologically, MPA cannot be differentiated from a benign PA as it consists of both epithelial and mesenchymal benign elements. The malignant, aggressive entity of MPA can manifest as local or distant metastasis or both. The WHO defines MPA as a “Histologically benign pleomorphic adenoma that inexplicably manifests local or distant metastasis.”<sup>[1]</sup> The most common site of metastasis was bone (45%), followed by head and neck (43%), lungs (36%),

and abdominal viscera (10%). Within the head-and-neck area, only 17% of the cases metastasized to regional lymph nodes.<sup>[2]</sup>

We had two cases of MPA at our hospital which we have studied in detail. One case was a recurrent palatal PA with lymph nodal metastasis. The second case was a long-standing PA (10 years) of submandibular gland with metastasis to nasopharynx and infratemporal fossa. We believe this is the first case of PA with metastasis to nasopharynx and infratemporal fossa. This case also presented with papillary carcinoma thyroid. There are no prior cases reported in which MPA is found to be synchronous with papillary carcinoma thyroid. We managed these cases surgically and advised for postoperative radiotherapy only in recurrence case.

A 60-year-old female presented to the Outpatient Department with a large left-sided submandibular swelling measuring 17 cm × 10 cm × 8 cm for 10 years. To begin with, the onset was insidious, and the swelling was small like a lemon as

*(Continue on page 133...)*

(Letter to the editor continue from page 126...)

described by the patient and it progressed gradually without causing any discomfort to attain the present size [Figure 1]. In contrast-enhanced computed tomography, we could see further swellings in the thyroid and in the nasopharynx [Figure 2]. Positron-emission tomography (PET) scan was advised, which showed multiple uptakes in the neck [Figure 3]. Fine-needle aspiration cytology from the submandibular swelling and thyroid swelling was done which showed mixed salivary gland tumor and papillary carcinoma, respectively. Nasal endoscopy showed a mucosa-covered bulge present in the left lateral wall of the nasopharynx, and the lesion was biopsied. Biopsy showed mixed salivary gland tumor similar to the submandibular swelling. She was diagnosed as MPA of the submandibular salivary gland with papillary carcinoma of the thyroid [Figure 4].

All the lesions were accessible, and the patient was treated surgically. Total thyroidectomy was performed for papillary carcinoma thyroid. Submandibular gland excision was done with nodal clearance. The metastatic lesion in the nasopharynx and in the infratemporal fossa was excised by the maxillary swing approach. Histopathology findings correlated with preoperative diagnosis. Radioactive iodine isotope scan was performed after 1 month which showed no uptake. She was disease free at 1-year follow-up.

A 63-year-old male presented to the outpatient department with swelling inside the left side of the oral cavity for 1 year which was gradually increasing in size [Figure 1]. The patient also had swelling on the left side of the neck for the past 8 months. Wide local excision of the palatal mass was done 10 years before for benign PA.

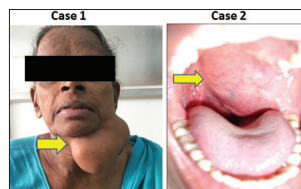

Figure 1: Clinical photograph of both the cases

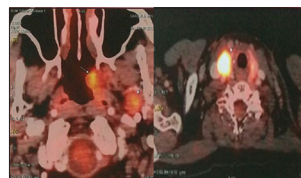


Figure 3: Positron-emission tomography-computed tomography showing uptake in the left nasopharynx, left infratemporal fossa, and right thyroid lobe

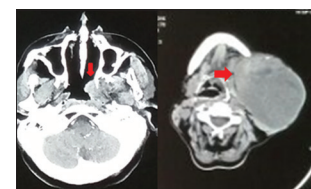


Figure 2: Computed tomography images showing mass in the nasopharynx and submandibular region

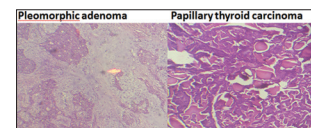


Figure 4: Histopathology of pleomorphic adenoma and papillary carcinoma of thyroid

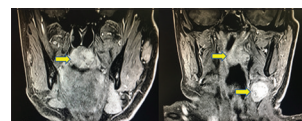


Figure 5: Magnetic resonance T1-weighted imaging with Gadolinium Contrast Media (GADO) contrast coronal view showing heterogeneous soft tissue in the left soft palate and submandibular region

(Continue on page 134...)

On examination, there was a 4 cm × 3 cm, mucosa-covered bulge seen on the left side of the soft palate and a 2 cm × 2 cm, mobile, firm, nontender mass on the left submandibular region [Figure 5].

He underwent transoral excision of the palatal mass and left selective neck dissection (Levels 1, 2, and 3). Frozen section done from the left submandibular region's lymph node came as a benign tumor. Histopathology was suggestive of MPA. He was advised for postoperative radiotherapy and was disease free at the end of 6-month follow-up.

Malignant transformation of PA can occur in three forms namely carcinoma ex-PA, carcinosarcoma, and MPA. The occurrence of MPA is extremely rare, accounting for 1% of all malignant PAs.<sup>[3,4]</sup> Knight and Ratnasingham's review found that the mean age at presentation of PA is before the fifth decade with slight female predominance, and presentation at a younger age could be a risk factor for developing MPA. In contrast, our both cases of MPA presented at their sixth decades.<sup>[5]</sup> Approximately 70% of MPA arise from primary parotid adenoma,<sup>[5]</sup> but both the cases reported here are of nonparotid origin. The parotid gland is the most common site for PA, so this could be related with the high occurrence of MPA in the parotid gland.

Recurrent disease, incomplete surgical excision, tumor spillage, and enucleation are considered the predisposing factors for developing MPA. Almost 73% of the reported cases of MPA had a history of local recurrence, with 37% of them demonstrating multiple relapses. It is strongly believed that surgical manipulation may permeate the tumor cells through lymphatic or venous access, promoting the hematogenous spread of a cytologically benign tumor.<sup>[5-7]</sup> At present, there are no well-established pathological parameters that may predict metastatic potential for PA. Nouraei *et al.* analyzed the histological features of malignancy, including increased mitotic activity, areas of necrosis, infiltrative pattern, and cellular atypia, but not identified in any of the primary lesions or distant metastases.<sup>[2]</sup>

Many studies have been reported to identify the genetic rearrangement in MPA by karyotypic chromosomal analysis and fluorescent *in situ* hybridization, but none of the studies showed positive results.<sup>[8,9]</sup> Even as of date, the pathological changes in PA are enigmatic and challenging to pathologists.

Surgical excision with clear margins is the treatment of choice, but overall survival depends on the metastasis. The percentage of patients dying of metastatic disease is quite high and stands at 22%.<sup>[2,5,10]</sup> As per literature, primary radiotherapy and chemotherapy has no role in treating MPA but could be tried in unresectable diseases. We have not advised radiotherapy for our primary case in view of complete tumor excision. Still, the role of radiotherapy in primary cases without previous surgery is controversial and can be reserved if they develop recurrence in future. Adjuvant radiotherapy was given for revision case to prevent the local recurrence after surgery.

Some studies showed the role of postoperative radiotherapy in order to prevent possible distant spread with positive results, but limitation is the follow-up. Long-term follow-up is required to assess the role of radiotherapy in primary as well as revision MPA cases.<sup>[11,12]</sup> The presence of metastases in multiple locations and

the occurrence of metastasis within 10 years of initial presentation are the poor prognostic factors. The 5-year disease-specific and disease-free survivals were 58% and 50%, respectively.<sup>[2,13]</sup>

One of our cases had papillary carcinoma of thyroid synchronously which was picked up in PET scan. Onitsuka studied that papillary carcinoma of the thyroid gland and PA of the parotid gland were positive for estradiol but not for testosterone or dihydrotestosterone receptors. He hypothesized that estradiol may exert an influence on the development of papillary carcinoma of the thyroid gland and PA of the parotid gland.<sup>[14]</sup> Glas *et al.*'s study showed that the expression of progesterone receptor may be a prognostic factor for PA recurrence.<sup>[15]</sup> We need further studies about the role of hormonal receptors in tumor occurrence.

Metastatic PA is a very rare tumor of salivary glands. We have reported the first case of nasopharyngeal and infratemporal fossa metastasis. There are no pathological criteria to diagnose the disease, and incomplete surgical excision is a strong risk factor. Metastasectomy plays a major role in the treatment outcome. The role of radiotherapy as an adjuvant in primary cases needs to be evaluated. The role of hormonal receptors needs to be studied to improve the prognosis of the disease. In view of rarity, tumor behavior and follow-up have to be documented to form a treatment protocol.

#### Declaration of patient consent

The authors certify that they have obtained all appropriate patient consent forms. In the form the patient(s) has/have given his/her/their consent for his/her/their images and other clinical information to be reported in the journal. The patients understand that their names and initials will not be published and due efforts will be made to conceal their identity, but anonymity cannot be guaranteed.

#### Financial support and sponsorship

Nil.

#### Conflicts of interest

There are no conflicts of interest.

**Suresh Mani, Sukamal Das<sup>1</sup>, Regi Thomas<sup>1</sup>, Rajiv C. Michael**

Departments of Head and Neck Surgery and <sup>1</sup>ENT, Christian Medical College Hospital, Vellore, Tamil Nadu, India

Correspondence to: Dr. Suresh Mani,  
E-mail: msuresh.doc@gmail.com

#### References

1. Barnes L, Eveson JW, Reichart P, Sidransky D. Tumours of the salivary gland. In: Pathology and Genetics: Head and Neck Tumours. World Health Organization Classification of Tumours. Lyon, France: IARC; 2005. p. 209-81.
2. Nouraei SA, Ferguson MS, Clarke PM, Sandison A, Sandhu GS, Michaels L, *et al.* Metastasizing pleomorphic salivary adenoma. Arch Otolaryngol Head Neck Surg 2006;132:788-93.
3. Auclair PL, Langloss JM, Weiss SW, Corio RL. Sarcomas and sarcomatoid neoplasms of the major salivary gland regions. A clinicopathologic and immunohistochemical study of 67 cases and review of the literature. Cancer 1986;58:1305-15.
4. Ghosh A, Arundhati, Asthana AK. Pleomorphic adenoma of the parotid gland metastasizing to the scapular region: A case report. Acta Cytol 2008;52:733-5.
5. Knight J, Ratnasingham K. Metastasizing pleomorphic adenoma: Systematic review. Int J Surg 2015;19:137-45.
6. Reiland MD, Koutlas IG, Gopalakrishnan R, Pearson AG, Basi DL. Metastasizing pleomorphic adenoma presents intraorally: A case report and review of the literature. J Oral Maxillofac Surg 2012;70:e531-40.
7. Yamaguchi T, Ashizawa K, Nagaoki K, Abiru H, Uetani M, Tagawa T, *et al.* Metastasizing pleomorphic adenoma of the submandibular gland with

- metastasis to the lung and sternum: CT and MR imaging findings. *Eur J Radiol Extra* 2009;72:69-72.
8. Jin Y, Jin C, Arheden K, Larsson O, Bauer HF, Mandahl N, *et al.* Unbalanced chromosomal rearrangements in a metastasizing salivary gland tumor with benign histology. *Cancer Genet Cytogenet* 1998;102:59-64.
  9. Akiba J, Harada H, Kawahara A, Todoroki K, Nagata S, Yano H, *et al.* A case of metastasizing pleomorphic adenoma in the maxillary bone appearing twenty years after initial resection of pleomorphic adenoma of the hard palate. *Pathol Int* 2013;63:463-8.
  10. Batsakis JG. Malignant mixed tumor. *Ann Otol Rhinol Laryngol* 1982;91 (3Pt 1):342-3.
  11. Czader M, Eberhart CG, Bhatti N, Cummings C, Westra WH. Metastasizing mixed tumor of the parotid: Initial presentation as a solitary kidney tumor and ultimate carcinomatous transformation at the primary site. *Am J Surg Pathol* 2000;24:1159-64.
  12. Rodríguez-Fernández J, Mateos-Micas M, Martínez-Tello FJ, Berjón J, Montalvo JJ, Forteza-González G, *et al.* Metastatic benign pleomorphic adenoma. Report of a case and review of the literature. *Med Oral Patol Oral Cir Bucal* 2008;13:E193-6.
  13. Alshagroud R, Kamoh A, Popat SR, Brandwein-Weber M, Aguirre A. Metastasizing pleomorphic adenoma case report and review of the literature. *Head Neck Pathol* 2017;11:487-93.
  14. Onitsuka T. Sex hormones in papillary carcinoma of thyroid gland and pleomorphic adenoma of parotid gland. *Acta Otolaryngol* 1994;114:218-22.
  15. Glas AS, Hollema H, Nap RE, Plukker JT. Expression of estrogen receptor, progesterone receptor, and insulin-like growth factor receptor-1 and of MIB-1 in patients with recurrent pleomorphic adenoma of the parotid gland. *Cancer* 2002;94:2211-6.

---

This is an open access journal, and articles are distributed under the terms of the Creative Commons Attribution-NonCommercial-ShareAlike 4.0 License, which allows others to remix, tweak, and build upon the work non-commercially, as long as appropriate credit is given and the new creations are licensed under the identical terms.

**How to cite this article:** Mani S, Das S, Thomas R, Michael RC. Metastasizing Pleomorphic Adenoma - Case reports and review of literature. *South Asian J Cancer* 2019;8:126-35.

© 2019 The South Asian Journal of Cancer | Published by Wolters Kluwer - Medknow