J. Fetal Med. (September 2017) 4:139–148
DOI 10.1007/s40556-017-0132-4

REVIEW ARTICLE

Current Strategy of Fetal Therapy II: Invasive Fetal Interventions

Katika Nawapun[1] · Nisarat Phithakwatchara[1] · Tacharee Panchalee[1] · Sommai Viboonchart[1] · Nadda Mongkolchat[1] · Tuangsit Wataganara[1]

Received: 16 March 2017 / Accepted: 12 July 2017 / Published online: 2 August 2017

Abstract Invasive fetal intervention provides potential benefits to the fetus, but risks to the mother and the fetus are not negligible. Large congenital pulmonary airway malformation (CPAM) may cause fetal hydrops. Shunt placement in macrocystic type or steroids administration in microcystic type CPAM have been reported to reverse the hydrops in a small case series. In selected cases of fetal congenital diaphragmatic hernia (CDH), tracheal plugging may prevent egress of the lung fluid, promote lung proliferation, and maturation of pulmonary vasculature, which favor survival in isolated right-sided CDH fetuses or those with a lung-to-head ratio of $\leq$1.0. Fetoscopic cystoscopy with laser fulguration of the posterior urethral valve improves the 6-month survival and renal function. A randomized controlled trial to validate the real benefits of this procedure is still underway. Laser photocoagulation of anastomosing vessels is the standard of care for severe mid-trimester twin-to-twin transfusion syndrome. The principle of equipoise is likely to be reached on the issue of optimal treatment for Quintero stage I disease. Open fetal surgery has been offered in some cases of fetal tumor and myelomeningocele (MMC). Alternatively, endoscopic approach is being investigated to minimize procedure-related maternal morbidity. Only when procedure-related complications are properly prevented and managed, it is expected that invasive therapeutic innovation will then improve perinatal outcomes of selected fetal conditions.

Keywords Fetal therapy · In-utero intervention · Twin-to-twin transfusion syndrome · Congenital diaphragmatic hernia · Posterior urethral valve · Myelomeningocele

Introduction

Prenatal invasive interventions are offered only in selected fetal conditions, because of substantial risks to the mother and fetus. While there is potential benefit to the fetus, there is no direct benefit to the mother. Minimally invasive procedures include needle-based (and shunting) and fetoscopic interventions. Open fetal surgery requires hysterotomy approach, which carries the risk of maternal morbidity. Ex utero intrapartum treatment (EXIT) is an intervention provided at the time of delivery with the baby remaining on placental bypass. Viewpoints of stakeholders to invasive fetal intervention vs. termination of pregnancy are shown in Table 1. This review article describes the concepts of strategic treatment approach for selected fetal conditions amenable for invasive prenatal treatment.

Minimally Invasive Fetal Interventions

Congenital Pulmonary Airway Malformation

Congenital pulmonary airway malformation (CPAM) is a common fetal lung tumor typically emerging from a single lobe. The original Stocker pathological classification

✉ Tuangsit Wataganara
twataganara@yahoo.com

[1] Division of Maternal–Fetal Medicine, Department of Obstetrics and Gynecology, Faculty of Medicine Siriraj Hospital, 2 Prannok Road, Bangkoknoi, Bangkok 10700, Thailand

Table 1 Viewpoints of stakeholders to invasive fetal intervention vs. early (undocumented) and late termination of pregnancy

Parents	Obstetricians	Fetal medicine specialists	Fetal medicine specialist
Quest for a perfect child	Defensive medicine	Professionalism	Professionalism
Early termination	Early termination	Early termination	Late termination
Early diagnosis	Early diagnosis	Early diagnosis	Late diagnosis in the disease that is either (1) difficult to diagnose, (2) progressive, or (3) uncertain prognosis. Informed choice is based on objective risk assessment. Fetal therapy supports late termination
Early uncertainty on the prognosis	Early uncertainty on the prognosis	Early uncertainty on the prognosis	
Social pressure	Medico-legal atmosphere	Social termination of pregnancy	
		Smaller common denominator	

system is not clinically relevant [1]. Ultrasound classification [as macrocystic (≥5 mm cystic spaces), or microcystic (<5 mm cystic spaces), or hybrid lesion] and CPAM volume ratio (CVR; an estimation of tumor volume standardized by gestational age [(length × height × width) × 0.52/head circumference] are more predictive for perinatal outcomes [2]. If CVR is >1.6, there is an 80% chance of fetal hydrops [3]. The growth pattern of CPAM is variable during 18–26 weeks of gestation, but spontaneous regression is common afterwards [2]. Twice weekly ultrasound surveillance is recommended in cases with CVR > 1.6 and weekly surveillance in those with smaller CVR [3].

Early delivery after steroid administration, followed by postnatal resection, may be suitable for CPAM with hydrops at >32 gestational weeks [4, 5]. Ex utero intrapartum treatment to extracorporeal membrane oxygenation (EXIT to ECMO) can also be considered. Thoracocentesis (needle tapping) is an option for macrocystic CPAM at <21 gestational weeks'. Fetal loss rate from thoracocentesis is <1% [6]. Re-accumulation of fluid at 21–32 weeks' gestation may be best treated with thoraco-amniotic shunting. Earlier shunt placement may cause deformity of the chest wall [7]. The overall survival rate of macrocystic CPAM after in-utero shunting is 82% (90 of 110); with the survival of hydropic and non-hydropic fetuses of 77% (53 of 68) and 90% (37 of 41), respectively [8].

For symptomatic microcystic CPAM, medical treatment may be the first option. Maternal administration of betamethasone could reduce CPAM size, but the data from case series are still conflicting [9–11]. Meta-analysis from these published reports suggested 80% resolution of hydrops and 87.1% overall survival to discharge in symptomatic microcystic CPAM treated prenatally with steroids [10]. Open fetal resection may be offered in cases where steroid therapy fails [12]. Even with technical limitations and lack of approved clinical trials, minimally invasive surgery for fetal CPAM is conceivable in the future [13, 14].

Pleural Effusion

Initial investigations should include maternal serology studies for toxoplasmosis, syphilis, varicella-zoster, parvovirus B19, rubella, cytomegalovirus (CMV), and herpes infection, detailed fetal anatomy scan, and echocardiography. Chromosome study, cell count and protein quantitation can help in identifying the etiology, i.e., effusion caused by isolated chylothorax has lymphocyte predomination (>80%) [15]. Massive pleural effusion can be managed with thoracocentesis, which may be followed by thoraco-amniotic shunting or medical pleurodesis in case of rapid re-accumulation [16]. The overall survival rate after in-utero thoraco-amniotic shunting was 35 and 58% in fetuses with and without hydrops, respectively [16, 17]. The techniques used by authors for in-utero thoraco-amniotic shunting are shown in Fig. 1.

Congenital Diaphragmatic Hernia

Congenital diaphragmatic hernia (CDH) can cause pulmonary hypoplasia and pulmonary hypertension. Approximately 40% of prenatally diagnosed CDH are associated with cardiac, urogenital, and central nervous system anomalies. Data from a large (n = 78,639) multicenter ultrasound screening study at 10–14 weeks' suggests a 1:4000 prevalence of CDH in chromosomally normal fetuses, of which 40% have increased nuchal translucency [18]. Left-sided defect is more common (85%) than right-sided (13%) and bilateral (2%). Overall survival rates for isolated left- and right-sided CDH with severe lung hypoplasia are approximately 24% and 0%, respectively [19, 20]. Hospital survival is lower for liver-up (61%) compared to liver-down (95%), even with ECMO and

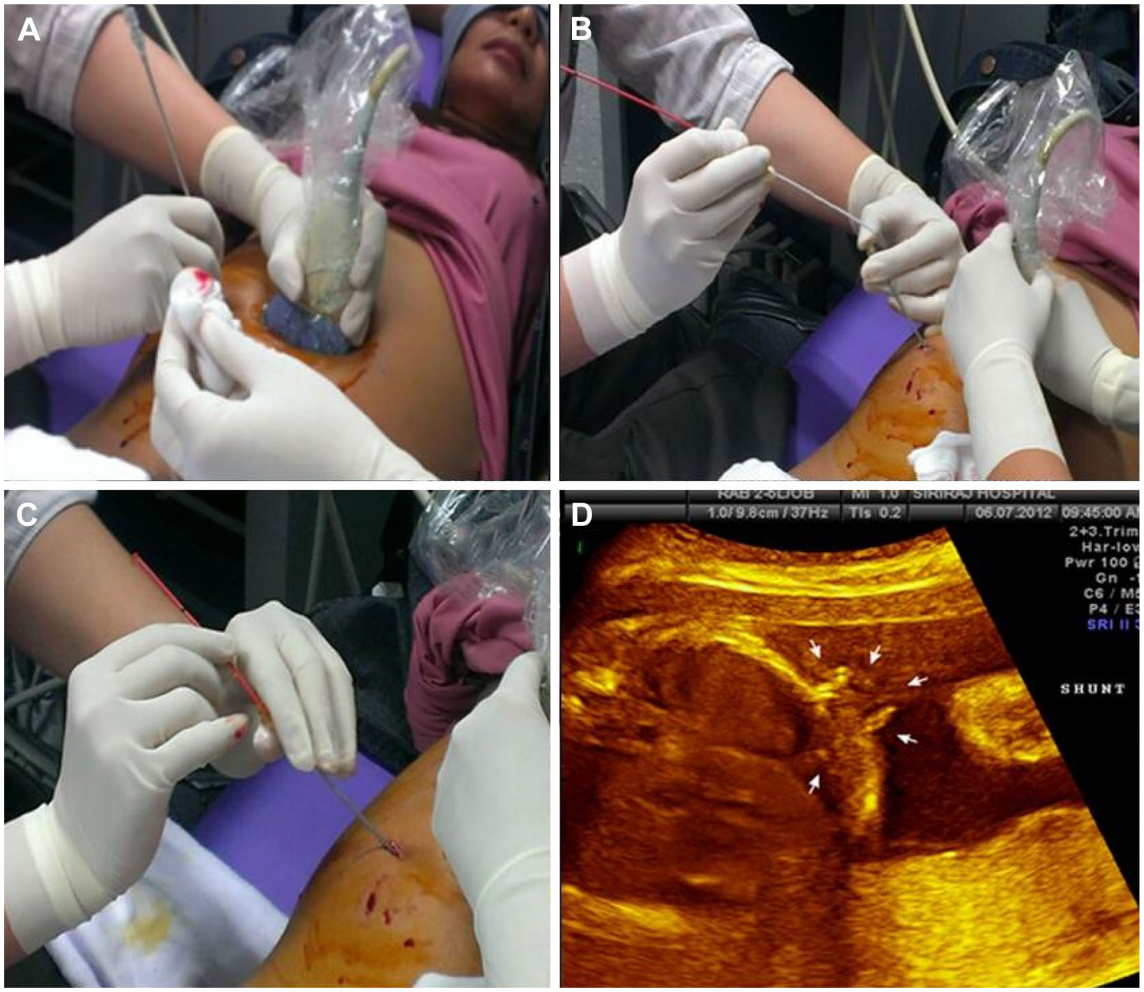

Fig. 1 In-utero thoraco-amniotic shunting. **a** The procedure is performed under local anesthesia with maternal intravenous sedation (i.e, with meperidine 50 mg). Under a continuous ultrasound guidance, a 13G Echotip trocar needle 18 cm long is inserted into fetal thoracic cavity; **b** A double pigtail stent (Harrison Fetal Bladder Stent; Performa, Cook, Strombeek, Bever, Belgium) with an outer diameter of 5 French and a length of 3.5 cm is loaded onto a 0.97 mm stainless steel wire guide 40 cm long, along with the 5 French positioner 24 cm long (*orange*); **c** The stent is loaded so that the proximal double pigtail coil is oriented perpendicularly to the stent to allow the pigtail to lie flat along the fetal thorax. The distal pigtail is a single coil, and it is oriented perpendicular to the stent in order to enhance retention; **d** After shunting, the fetus is followed with serial ultrasound examinations every 1–2 weeks for the amount of effusion, lung size, degree of mediastinal shift, and resolution of hydrops

postnatal surgery [21]. The ECMO survivors may suffer from major chronic pulmonary and gastrointestinal disorders, failure to thrive, and neurodevelopmental delay.

Fetoscopic endoluminal tracheal occlusion (FETO) prevents egress of the lung fluid. Data from animal studies suggested that it may promote lung proliferation and maturation of pulmonary vasculature. A historical non-interventional controls study demonstrated a significant improvement of perinatal survival rate in a group undergoing FETO from 24 to 49% in left-sided CDH and from 0 to 35% in right-sided CDH. Lung proliferation and morphologic advancement may be better achieved if the procedure is offered early [19]. Ruano and colleagues have reported a successful series of early tracheal occlusion as early as 22–24 weeks' [22]. The lung seems to expand effectively up until 35 to 45 days post-occlusion [23]. The techniques used by authors for FETO are depicted in Fig. 2.

The data from small case series were so encouraging that a randomized controlled trial (RCT), the Tracheal Occlusion To Accelerate Lung growth (TOTAL) trial for moderate and severe pulmonary hypoplasia, a collaboration between the Eurofoetus and the North American Fetal Therapy Network (NAFTNet), was established. Candidates are selected according to residual capacity of the contralateral lung estimated by ultrasound (observed/expected lung-to-head ratio; o/e LHR) or magnetic resonance imaging (observed/expected total fetal lung volume; o/e TFLV), and fetuses with moderate to severe lung hypoplasia (o/e LHR $\leq$1.0)are randomized for expectant

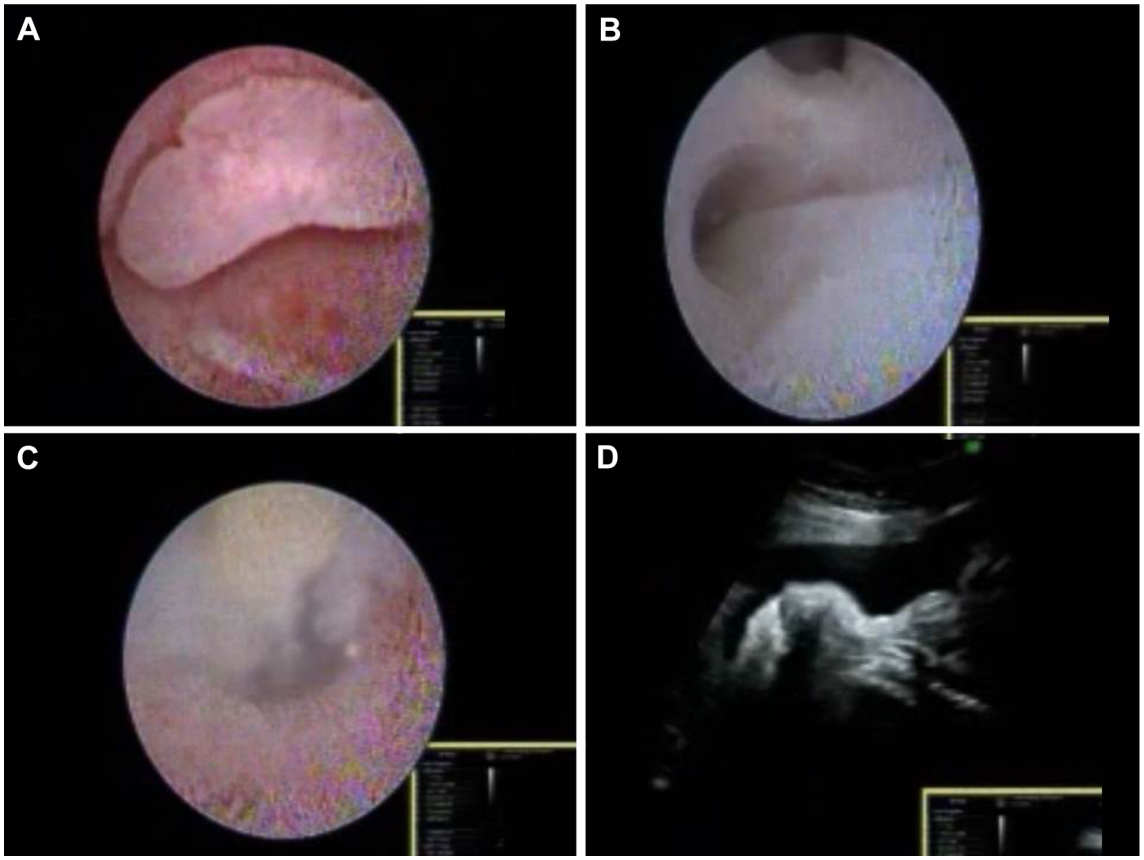

Fig. 2 Fetoscopic endoluminal tracheal occlusion (FETO). **a** The procedure is performed under general anesthesia or combined spinal–epidural anesthesia. When necessary, the fetus is gently positioned to achieve better access to the trachea and to allow for trocar insertion in the upper half of the uterus. Fetal analgesia is administered by ultrasound-guided intramuscular injection of fentanyl (15 μg/kg), pancuronium (0.2 mg/kg), and atropine (20 μg/kg) through a 22G needle. A 10 French thin-walled flexible Teflon® cannula (Performa, Cook, Strombeek, Bever, Belgium) is inserted into the amniotic cavity and directed towards the fetal mouth. The trocar is then withdrawn and a slightly bent sheath of 10F sheath loaded with a 1.2 mm fiber endoscope (Karl Storz, Tuttlingen, Germany) and the balloon occlusion system, consisting of a catheter loaded with a detachable gold valve balloon (GVB 16, Cathnet Science, Paris, France) are inserted. The endoscope is introduced into the fetal mouth and directed over the tongue in the midline by visualizing the epiglottis as a landmark; **b** The endoscope is then advanced through the vocal cords to the trachea to identify the carina; **c** The catheter is positioned to deliver the balloon just above it. The balloon is inflated with normal saline solution and left in situ to occlude the trachea just above the carina; **d** The position of balloon is checked by ultrasound examination. Normalization of amniotic fluid is accomplished before the trocar is removed

management and FETO. Oxygen dependency, need for medication for pulmonary hypertension, need to heart–lung machine, days requiring a ventilator until normal feeding and in the hospital, day of the surgery and requirement of a patch to close the defect, occurrence of brain problems, infections, prematurity sequelae, and reflux are among the short-term outcomes being evaluated. Long term evaluation for lung function and neurologic development are made at 1 and 2 year after birth [24]. Although the trial is still ongoing, a recent meta-analysis showed that FETO favored survival outcome in isolated severe CDH fetuses [25].

Lower Urinary Tract Obstruction

Lower urinary tract obstruction (LUTO) of the fetus can be readily diagnosed on ultrasound examination. The key findings include the presence of a distended bladder, bilateral hydronephrosis, and severe oligohydramnios [26]. There is high perinatal morbidity due to pulmonary hypoplasia and renal damage (fibrocystic dysplasia).

Clark and colleagues [27] analyzed perinatal outcomes of 342 fetuses with severe LUTO treated in-utero with bladder drainage procedures [serial vesicocentesis, vesicoamniotic shunting (VAS), and open fetal vesicostomy] from 7 controlled studies and 9 case series without controls, and found an improved overall neonatal survival, particularly in poor prognosis group [OR 26.19 (95% CI 4.39–156.2)] compared to the good prognosis group [OR 2.25 (95% CI 0.65–7.81)]. Based on data from small case series without control groups, VAS was a standard of care for a fetus with LUTO, until the results from Percutaneous vesicoamniotic shunting in Lower Urinary Tract Obstruction (PLUTO) trial were published in

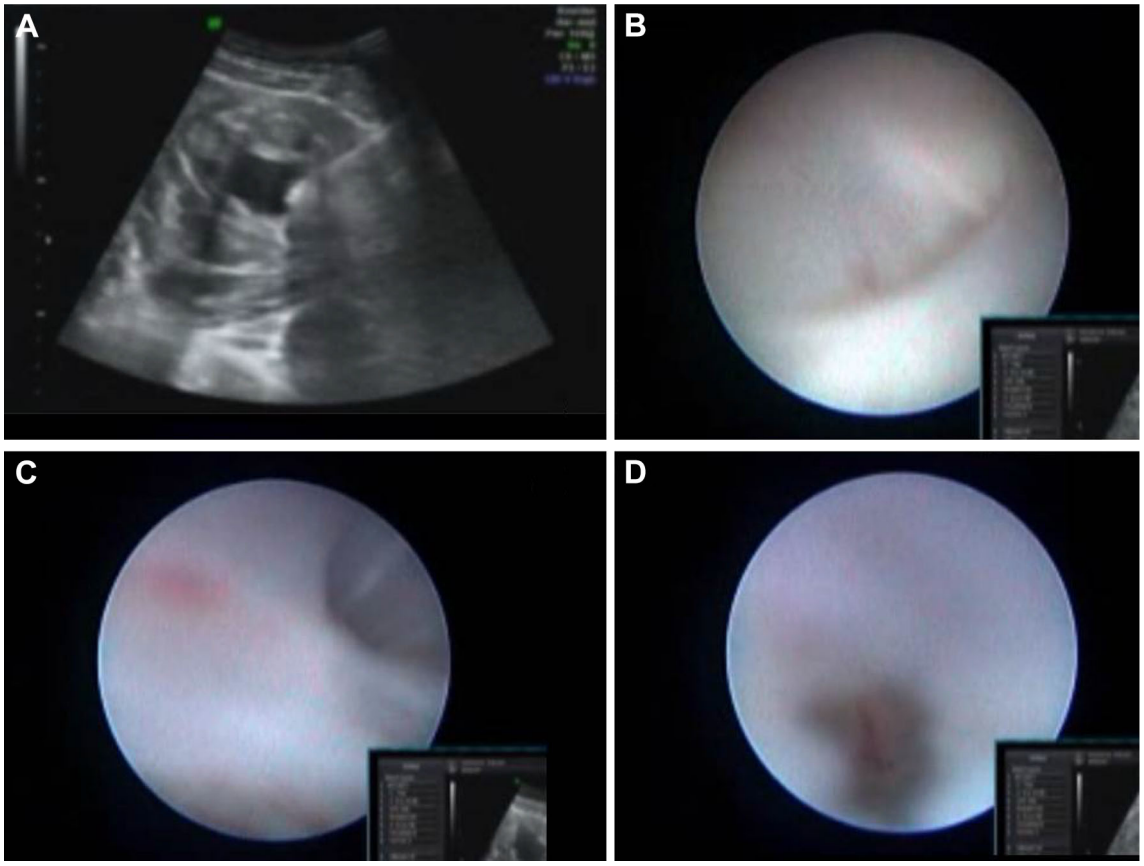

Fig. 3 Fetoscopic cystoscopy with laser fulguration of posterior urethral valve (PUV). **a** The procedure is performed under local anesthesia with maternal intravenous sedation (i.e., with meperidine 50 mg) or combined spinal–epidural anesthesia. Fetal analgesia is administered by ultrasound-guided intramuscular injection of fentanyl (15 µg/kg) and pancuronium (0.2 mg/kg) through a 22G needle. A slightly bent 10F sheath is inserted into the dilated urinary bladder of the fetus, followed by an insertion of a 1.2 mm fiber endoscope (Karl Storz, Tuttlingen, Germany); **b** and **c** The PUV is identified and fulgurated by pulsed shots of an Nd:YAG laser through 400 µm laser fiber starting at 10 Watts, with maximal setting at 30 W (Multibeam, Dornier Medtech, Kennesaw, GA, USA); **d** Patency of the urethra is confirmed under direct visualization. Normalization of amniotic fluid is accomplished before the trocar is removed

2013 [28]. This RCT showed a borderline increased survival rate in VAS group (n = 31), compared to expectant management group (intention-to-treat RR 1.88, 95% CI 0.71–4.96; $p = 0.27$), but most babies had impaired renal function irrespective of VAS. Recent perinatal outcome data from fetoscopic cystoscopy with laser fulguration of posterior urethral valve (PUV) are more encouraging. Laser ablation of PUV can improve both the 6-month survival rate [adjusted RR 4.10 (95% CI 1.75–9.62; $p < 0.01$)] and renal function [adjusted RR 2.66 (95% CI 1.25–5.70; $p = 0.01$)] [29]. The techniques used by authors for fetoscopic cystoscopy with laser fulguration of PUV are described in Fig. 3.

Complicated Monochorionic Twins

Monozygotic diamniotic twinning occurs after the division between day 4 and day 8 post-conception, especially with in vitro fertilization [30]. The incidence of monochorionic twins following single embryo transfer is 2–2.3%, and the chance is increased to 3–6% for day 5 transfer. Younger egg age (<35-year-old) is associated with 3% chance of monochorionic twinning [31]. Clinical implications of monochorionic twinning are secondary to vascular anastomoses in the placenta. Pathology associated to these include twin-to-twin transfusion syndrome (TTTS), twin anemia polycythemia sequence (TAPS), and twin reversed arterial perfusion sequence (TRAPS). Management of complications is challenged by the size and number of chorionic anastomoses.

Approximately 1 in 10 monochorionic twin pairs have TTTS. It is advisable to scan monochorionic twins every 2 week between 16 and 26 weeks of gestation to detect this serious complication. Early prediction of TTTS with the first and the second trimester ultrasound markers has been proposed, as summarized in Table 2 [32–34]. Combination

Table 2 Proposed first and second trimester markers for early prediction of twin-to-twin transfusion syndrome

Parameters	Performance	References
First trimester markers		
Discordant NT >20%	Sen 52%, SPR 25%, PPV 24%	Kagan et al. [32]
Abnormal DV ≥1	Sen 38%, SPR 18%, PPV 24%	Maiz et al. [33]
Different CRL >6 mm	Sen 52%, SPR 26%, PPV 19%	Matias et al. [34]
Second trimester markers		
Absence AA anastomosis	Sen 76%, SPR 43%, PPV 60%	Taylor et al. [35]
Membrane folding	Sen 91%, SPR 32%, PPV 43%	Sebire et al. [36]
Discordant cord insertion	N/A	Hack et al. [37]

AA Arterio-arterial, *AF* Amniotic fluid, *CRL* Crown-rump length, *DV* Ductus venosus, *N/A* Not available, *NT* Nuchal translucency, *PPV* Positive predictive value, *Sen* Sensitivity, *SPR* Screen positive rate

Table 3 Principle of equipoise on the laser treatment as the first line for stage I twin-to-twin transfusion syndrome

	Equipoise
Case selection	Technical difficulties
	Cervix
Ability	Learning curve
	Technique
Perioperative risk	Staging
Selectivity	Learning curve
	Technique

of these markers could also be used to predict a broader spectrum of complicated monochorionic twins [38]. Amniotic deepest vertical pool (DVP) >8 cm is used for diagnosis throughout the gestation in the United States. For Eurofoetus, a more conservative DVP >10 cm is used for gestational age >20 weeks'.

It remains unclear whether laser or amnioreduction yield better risk–benefit ratio for the treatment of early TTTS. The principle of equipoise is likely to be reached on the issue of optimal treatment for stage I disease, as shown in Table 3, and hence it is envisaged that laser may be the first-line treatment for all stages of TTTS. If selective feticide is unavoidable, choosing the right energy source with the right power is crucial [39].

Retrospective analysis of the outcomes of laser surgery for TTTS performed at Faculty of Medicine Siriraj Hospital was conducted. The protocol was approved by Siriraj Institutional Review Board [number SIRB 704/2559 (EC3)]. The first 103 laser procedures from January 2008 to April 2014 resulted in at least 1 survivor rate of 87% with the median gestational age at delivery of 31 weeks'. This outcome figures are comparable to the reports from other experienced fetal care centers in Europe, North America, Australia, and Japan [40–44]. Non-selective photocoagulation was used initially (21%); then selective photocoagulation (72%) was used until April 2014 before the team switched to equatorial (Solomon) technique [45]. Of noted, approximately 7% of the procedures in this cohort of authors' early experience started out using selective technique then converted to non-selective photocoagulation for a faster dichorionization to finish the procedure due to untoward problems such as profound fetal bradycardia or uncontrollable bleeding from chorionic plate vessels. Analysis of authors' institutional outcomes after an adoption of equatorial laser photocoagulation is currently underway.

Open Fetal Surgery

Sacrococcygeal Teratoma

Sacrococcygeal teratoma (SCT) can cause intrauterine demise from rapid growth, large arteriovenous shuntings, tumor necrosis or cystic degeneration with rupture or hemorrhage, high-output cardiac failure, and secondary hydrops [46, 47]. American Academy of Pediatrics Surgical Section categorizes SCT into 4 types by the relative amount of intrapelvic and extrapelvic tumor consistent with the ease of prenatal diagnosis and surgical resection, the risk of malignancy, and survival [48]. Type I SCT, completely external, can be recognized easily on prenatal ultrasound examination with low potential of malignancy. On the contrary, type IV is difficult to diagnose by the reason of completely internal component with high incidence of malignancy. The majority of cases are type I or II. Intrafetal growth of the tumor can cause either oligohydramnios (bladder invasion) or polyhydramnios (gastrointestinal tract obstruction).

Open fetal surgery is an option in isolated type I SCT at ≤32 gestational weeks with high-output cardiac failure and normal karyotype [48–50]. Minimally invasive procedures, i.e., fetoscopic laser coagulation of feeding vessels or radiofrequency ablation, have limited clinical data of the safety and efficacy [51, 52]. Early delivery, preferably by

Cesarean section, after steroid administration, followed by postnatal resection, may be suitable for SCT with hydrops at >32 gestational weeks.

Myelomeningocele

In-utero surgery for myelomeningocele (MMC) is an example of fetal surgery for a non-lethal malformation. Secondary hydrocephalus from a herniation of the hindbrain increases neonatal morbidity and long-term handicap. The principle of prenatal MMC repair is based on the premise that the defect should be corrected to obviate neurological damage. The Management of Myelomeningocele Study (MOMS) trial, an RCT supported by the National Institutes of Health (NIH), showed a significant reduction of Arnold Chiari malformation in prenatal (64%) compared to postnatal (96%) treatment group ($p < 0.001$) [53]. Fetal or neonatal death and the need for cerebrospinal fluid shunt were significantly lower in prenatal surgery group than postnatal surgery group (68% vs. 98% and 40% vs. 82% respectively; $p < 0.001$). Mental development and motor function at 30 months of age were better in the prenatal surgery group compared with the postnatal surgery group ($p = 0.007$). Children in the prenatal surgery group had a higher chance of walking independently than those in the postnatal surgery group (42% vs. 21%; $p = 0.01$).

There are downsides of prenatal MMC repair. Fetuses with MMC whose ventricles are ≥15 mm at 19–25 weeks of gestation seem to gain no benefit from prenatal repair on the subject of postnatal shunting [54]. There was no improvement in motor function, bowel, or bladder control. All (100%) of the patients needed to be delivered by Cesarean section, and all (100%) of them were delivered prematurely, with 10% delivered at less than 30 weeks' [55]. Chorioamniotic membrane separation, spontaneous rupture of membranes, and spontaneous preterm labor were reported to occur more often in prenatal MMC repair than postnatal MMC repair (26% vs. 0%, 46 vs. 8%, and 38 vs. 14%, respectively; $p < 0.001$) [53]. There is a 6% chance of maternal pulmonary edema after prenatal MMC repair [53]. Oligohydramnios (20%) and uterine dehiscence (11%) were reported after prenatal MMC repair [56]. Until now, no maternal death has occurred after prenatal MMC repair. Despite the fact that there is no prospective long-term study, maternal fertility seems to be uninfluenced by open fetal surgery, as reported in two small studies [57, 58].

MOMS trial has generated as many questions as it has brought answers. The controversies include [1] the reduction in ventriculo-peritoneal shunting vs. the sequelae of prematurity, [2] an impact of prenatal surgery on the very severe forms of MMC, [3] worsening of purely sacral types of MMC, and [4] loss of women's right to termination of the pregnancy.

Fetoscopic MMC repair is a less invasive alternative to reduce maternal morbidity, however longer operation time, increased risk of preterm premature rupture of membranes, earlier gestational age at birth, and higher incidence of incomplete closure of the defect leading to additional postnatal surgery have been reported with this approach [59]. Further translational researches are needed to develop the appropriate surgical repair to make the fetoscopic approach more effective. Regional, rather than institutional, approach, in addition to protocol standardization and transparency of outcome assessment is crucial when a novel invasive procedure is being adopted [60].

At this moment in time, according to a Committee Opinion from the American College of Obstetricians and Gynecologists (ACOG), there are three options for patients with MMC diagnosed prenatally, including standard postnatal repair, prenatal repair, or termination of pregnancy [61]. A candidate for prenatal repair should be selected with reference to the appropriate criteria. The outcomes, risk of obstetric complications, as well as the requirement of Cesarean delivery in subsequent pregnancies are major counseling issues prior to the operation. Even though it is not completely recovered, prenatal MMC repair may ameliorate outcomes for a better quality of life. Several studies regarding this perspective remain ongoing.

Prevention and Management of Complications from Invasive Fetal Therapy

Procedure-related complications can be shown from experiences with laser surgery for TTTS. It can either be direct [i.e., preterm premature rupture of the membrane (PPROM), maternal or fetal injury from trocar insertion, iatrogenic septostomy, and infection] or indirect (i.e., anesthetic complications). It may also be categorized as fetal and maternal complications (Table 4).

Approximately 11% (33/306) monochorionic twin pairs developed TAPS after laser surgery for TTTS. Survival of post-laser TAPS is 80% (53/66), with 9% (4/47) incidence of neurodevelopmental impairment in either donor or recipient twin. Low cognitive scoring was detected in 17% (8/47) of children, and is associated with low gestational age at birth and low birth weight. Rescue transfusion for post-laser TAPS does not seem to yield additional benefit on childhood cognitive score. It is more ideal to prevent this complication by using equatorial (or Solomon) technique for coagulation of chorionic anastomoses [45]. With improvement of prenatal and neonatal cares, post-laser TAPS may not necessary be associated with significantly worse outcome [62].

Table 4 Potential complications from fetoscopic laser surgery

Fetal	Maternal
Incomplete occlusion, leading to cerebral damages	Myometrial bleeding
Exsanguination	Placental abruption
Preterm labor	Amniotic fluid leakage
Preterm premature rupture of the membrane	Infection
Iatrogenic septostomy	

Iatrogenic rupture of intertwin membranes may occur in 20% of pregnancies following laser therapy and was associated with a lower gestational age at birth and increased neonatal morbidity [63]. Risk of limb amputation from amniotic band sequence must be weighed against the risk of fetoscopic release. Based on data obtained from experiments in animal model, one should consider fetoscopic band release to salvage fetal limb only when (1) distal edema decreases more than 25% and (2) distal artery peak velocity decreases more than 30% [64].

Conclusions and Future Directions for Invasive Fetal Therapy

It is expected that therapeutic innovation will improve perinatal outcomes of selected fetal conditions. Although the maternal morbidity associated with fetoscopy is low, preterm rupture of membranes and preterm delivery remain an important problem. Long-term evaluation of those neonates remains mandatory. The world is now globalized. Fetal therapeutic technique developed at one center can quickly be communicated and adopted by the others. Effective communication has made the greatest impact in quality health care. Ability to intervene in certain fetal diseases prenatally has significantly reduced neonatal and maternal morbidity. Maternal traumatic delivery, such as vaginal delivery of a baby with hydrocephalus, can sometimes be averted with in utero intervention. Quality medical care is a basic service in most developed nations. Dissemination of technology and funding are crucial to bring down the boundary of fetal care throughout the world.

Compliance with Ethical Standards

Conflict of Interest None.

Source of Funding Funding was provided by Mahidol University.

References

1. Stocker JT, Madewell JE, Drake RM. Congenital cystic adenomatoid malformation of the lung. Classification and morphologic spectrum. Hum Pathol. 1977;8:155–71.
2. Crombleholme TM, Coleman B, Hedrick H, et al. Cystic adenomatoid malformation volume ratio predicts outcome in prenatally diagnosed cystic adenomatoid malformation of the lung. J Pediatr Surg. 2002;37:331–8.
3. Adzick NS. Open fetal surgery for life-threatening fetal anomalies. Semin Fetal Neonatal Med. 2010;15:1–8.
4. Adzick NS, Flake AW, Crombleholme TM. Management of congenital lung lesions. Semin Pediatr Surg. 2003;12:10–6.
5. Wilson RD. In-utero therapy for fetal thoracic abnormalities. Prenat Diagn. 2008;28:619–25.
6. Wilson RD, Johnson MP. Prenatal ultrasound guided percutaneous shunts for obstructive uropathy and thoracic disease. Semin Pediatr Surg. 2003;12:182–9.
7. Merchant AM, Peranteau W, Wilson RD, et al. Postnatal chest wall deformities after fetal thoracoamniotic shunting for congenital cystic adenomatoid malformation. Fetal Diagn Ther. 2007;22:435–9.
8. Litwinska M, Litwinska E, Janiak K, Piaseczna-Piotrowska A, Gulczynska E, Szaflik K. Thoracoamniotic shunts in macrocystic lung lesions: case series and review of the literature. Fetal Diagn Ther. 2017;41:179–83.
9. Peranteau WH, Wilson RD, Liechty KW, et al. Effect of maternal betamethasone administration on prenatal congenital cystic adenomatoid malformation growth and fetal survival. Fetal Diagn Ther. 2007;22:365–71.
10. Curran PF, Jelin EB, Rand L, et al. Prenatal steroids for microcystic congenital cystic adenomatoid malformations. J Pediatr Surg. 2010;45:145–50.
11. Morris LM, Lim FY, Livingston JC, Polzin WJ, Crombleholme TM. High-risk fetal congenital pulmonary airway malformations have a variable response to steroids. J Pediatr Surg. 2009;44:60–5.
12. Grethel EJ, Wagner AJ, Clifton MS, et al. Fetal intervention for mass lesions and hydrops improves outcome: a 15-year experience. J Pediatr Surg. 2007;42:117–23.
13. Bruner JP, Jarnagin BK, Reinisch L. Percutaneous laser ablation of fetal congenital cystic adenomatoid malformation: too little, too late? Fetal Diagn Ther. 2000;15:359–63.
14. Milner R, Kitano Y, Olutoye O, Flake AW, Adzick NS. Radiofrequency thermal ablation: a potential treatment for hydropic fetuses with a large chest mass. J Pediatr Surg. 2000;35:386–9.
15. Peranteau WH, Adzick NS, Boelig MM, et al. Thoracoamniotic shunts for the management of fetal lung lesions and pleural effusions: a single-institution review and predictors of survival in 75 cases. J Pediatr Surg. 2015;50:301–5.
16. Rustico MA, Lanna M, Coviello D, Smoleniec J, Nicolini U. Fetal pleural effusion. Prenat Diagn. 2007;27:793–9.
17. Yinon Y, Grisaru-Granovsky S, Chaddha V, et al. Perinatal outcome following fetal chest shunt insertion for pleural effusion. Ultrasound Obstet Gynecol. 2010;36:58–64.
18. Sebire NJ, Snijders RJ, Davenport M, Greenough A, Nicolaides KH. Fetal nuchal translucency thickness at 10–14 weeks' gestation and congenital diaphragmatic hernia. Obstet Gynecol. 1997;90:943–6.

19. Jani J, Nicolaides KH, Keller RL, et al. Observed to expected lung area to head circumference ratio in the prediction of survival in fetuses with isolated diaphragmatic hernia. Ultrasound Obstet Gynecol. 2007;30:67–71.
20. DeKoninck P, Gomez O, Sandaite I, et al. Right-sided congenital diaphragmatic hernia in a decade of fetal surgery. BJOG. 2015;122:940–6.
21. Bojanic K, Woodbury JM, Cavalcante AN, et al. Congenital diaphragmatic hernia: outcomes of neonates treated at Mayo Clinic with and without extracorporeal membrane oxygenation. Paediatr Anaesth. 2017;27:314–21.
22. Ruano R, Peiro JL, da Silva MM, et al. Early fetoscopic tracheal occlusion for extremely severe pulmonary hypoplasia in isolated congenital diaphragmatic hernia: preliminary results. Ultrasound Obstet Gynecol. 2013;42:70–6.
23. Nawapun K, Eastwood MP, Diaz-Cobos D, et al. In vivo evidence by magnetic resonance volumetry of a gestational age dependent response to tracheal occlusion for congenital diaphragmatic hernia. Prenat Diagn. 2015;35:1048–56.
24. Deprest J, De Coppi P. Antenatal management of isolated congenital diaphragmatic hernia today and tomorrow: ongoing collaborative research and development. J Pediatr Surg. 2012;47:282–90.
25. Al-Maary J, Eastwood MP, Russo FM, Deprest JA, Keijzer R. Fetal tracheal occlusion for severe pulmonary hypoplasia in isolated congenital diaphragmatic hernia: a systematic review and meta-analysis of survival. Ann Surg. 2016;264:929–33.
26. Anumba DO, Scott JE, Plant ND, Robson SC. Diagnosis and outcome of fetal lower urinary tract obstruction in the northern region of England. Prenat Diagn. 2005;25:7–13.
27. Clark TJ, Martin WL, Divakaran TG, Whittle MJ, Kilby MD, Khan KS. Prenatal bladder drainage in the management of fetal lower urinary tract obstruction: a systematic review and meta-analysis. Obstet Gynecol. 2003;102:367–82.
28. Morris RK, Malin GL, Quinlan-Jones E, et al. Percutaneous vesicoamniotic shunting versus conservative management for fetal lower urinary tract obstruction (PLUTO): a randomised trial. Lancet. 2013;382:1496–506.
29. Ruano R, Sananes N, Sangi-Haghpeykar H, et al. Fetal intervention for severe lower urinary tract obstruction: a multicenter case-control study comparing fetal cystoscopy with vesicoamniotic shunting. Ultrasound Obstet Gynecol. 2015;45:452–8.
30. Blickstein I, Jones C, Keith LG. Zygotic-splitting rates after single-embryo transfers in in vitro fertilization. N Engl J Med. 2003;348:2366–7.
31. Knopman J, Krey LC, Lee J, Fino ME, Novetsky AP, Noyes N. Monozygotic twinning: an eight-year experience at a large IVF center. Fertil Steril. 2010;94:502–10.
32. Kagan KO, Gazzoni A, Sepulveda-Gonzalez G, Sotiriadis A, Nicolaides KH. Discordance in nuchal translucency thickness in the prediction of severe twin-to-twin transfusion syndrome. Ultrasound Obstet Gynecol. 2007;29:527–32.
33. Maiz N, Staboulidou I, Leal AM, Minekawa R, Nicolaides KH. Ductus venosus Doppler at 11 to 13 weeks of gestation in the prediction of outcome in twin pregnancies. Obstet Gynecol. 2009;113:860–5.
34. Matias A, Montenegro N, Loureiro T, et al. Screening for twin-twin transfusion syndrome at 11–14 weeks of pregnancy: the key role of ductus venosus blood flow assessment. Ultrasound Obstet Gynecol. 2010;35:142–8.
35. Taylor MJ, Denbow ML, Tanawattanacharoen S, Gannon C, Cox PM, Fisk NM. Doppler detection of arterio-arterial anastomoses in monochorionic twins: feasibility and clinical application. Hum Reprod. 2000;15:1632–6.
36. Sebire NJ, Souka A, Skentou H, Geerts L, Nicolaides KH. Early prediction of severe twin-to-twin transfusion syndrome. Hum Reprod. 2000;15:2008–10.
37. Hack KE, Nikkels PG, Koopman-Esseboom C, et al. Placental characteristics of monochorionic diamniotic twin pregnancies in relation to perinatal outcome. Placenta. 2008;29:976–81.
38. Lewi L, Lewi P, Diemert A, et al. The role of ultrasound examination in the first trimester and at 16 weeks' gestation to predict fetal complications in monochorionic diamniotic twin pregnancies. Am J Obstet Gynecol. 2008;199:493.e1–7.
39. Satapornteera P, Raveesunthornkiat M, Sukpanichnant S, Tongdee T, Homsud S, Wataganara T. Effects of power and time on ablation size produced by radiofrequency ablation: in vitro study in fresh human placenta. Fetal Diagn Ther. 2015;38:41–7.
40. Huber A, Diehl W, Bregenzer T, Hackeloer BJ, Hecher K. Stage-related outcome in twin-twin transfusion syndrome treated by fetoscopic laser coagulation. Obstet Gynecol. 2006;108:333–7.
41. Middeldorp JM, Sueters M, Lopriore E, et al. Fetoscopic laser surgery in 100 pregnancies with severe twin-to-twin transfusion syndrome in the Netherlands. Fetal Diagn Ther. 2007;22:190–4.
42. Cincotta RB, Gray PH, Gardener G, Soong B, Chan FY. Selective fetoscopic laser ablation in 100 consecutive pregnancies with severe twin-twin transfusion syndrome. Aust N Z J Obstet Gynaecol. 2009;49:22–7.
43. Sago H, Hayashi S, Saito M, et al. The outcome and prognostic factors of twin-twin transfusion syndrome following fetoscopic laser surgery. Prenat Diagn. 2010;30:1185–91.
44. Chmait RH, Kontopoulos EV, Korst LM, Llanes A, Petisco I, Quintero RA. Stage-based outcomes of 682 consecutive cases of twin-twin transfusion syndrome treated with laser surgery: the US fetus experience. Am J Obstet Gynecol. 2011;204:393.e1–6.
45. Slaghekke F, Favre R, Peeters SH, et al. Laser surgery as a management option for twin anemia-polycythemia sequence. Ultrasound Obstet Gynecol. 2014;44:304–10.
46. Bond SJ, Harrison MR, Schmidt KG, et al. Death due to high-output cardiac failure in fetal sacrococcygeal teratoma. J Pediatr Surg. 1990;25:1287–91.
47. Wilson RD, Hedrick H, Flake AW, et al. Sacrococcygeal teratomas: prenatal surveillance, growth and pregnancy outcome. Fetal Diagn Ther. 2009;25:15–20.
48. Altman RP, Randolph JG, Lilly JR. Sacrococcygeal teratoma: American Academy of Pediatrics surgical section survey-1973. J Pediatr Surg. 1974;9:389–98.
49. Adzick NS, Crombleholme TM, Morgan MA, Quinn TM. A rapidly growing fetal teratoma. Lancet. 1997;349:538.
50. Makin EC, Hyett J, Ade-Ajayi N, Patel S, Nicolaides K, Davenport M. Outcome of antenatally diagnosed sacrococcygeal teratomas: single-center experience (1993–2004). J Pediatr Surg. 2006;41:388–93.
51. Hecher K, Hackeloer BJ. Intrauterine endoscopic laser surgery for fetal sacrococcygeal teratoma. Lancet. 1996;347:470.
52. Lam YH, Tang MH, Shek TW. Thermocoagulation of fetal sacrococcygeal teratoma. Prenat Diagn. 2002;22:99–101.
53. Adzick NS, Thom EA, Spong CY, et al. A randomized trial of prenatal versus postnatal repair of myelomeningocele. N Engl J Med. 2011;364:993–1004.
54. Tulipan N, Wellons JC 3rd, Thom EA, et al. Prenatal surgery for myelomeningocele and the need for cerebrospinal fluid shunt placement. J Neurosurg Pediatr. 2015;16:613–20.
55. Bruner JP. Intrauterine surgery in myelomeningocele. Semin Fetal Neonatal Med. 2007;12:471–6.
56. Johnson MP, Bennett KA, Rand L, et al. The management of myelomeningocele study: obstetrical outcomes and risk factors for obstetrical complications following prenatal surgery. Am J Obstet Gynecol. 2016;215:778.e1–9.
57. Farrell JA, Albanese CT, Jennings RW, Kilpatrick SJ, Bratton BJ, Harrison MR. Maternal fertility is not affected by fetal surgery. Fetal Diagn Ther. 1999;14:190–2.

58. Longaker MT, Golbus MS, Filly RA, Rosen MA, Chang SW, Harrison MR. Maternal outcome after open fetal surgery: a review of the first 17 human cases. JAMA. 1991;265:737–41.
59. Joyeux L, Engels AC, Russo FM, et al. Fetoscopic versus open repair for spina bifida aperta: a systematic review of outcomes. Fetal Diagn Ther. 2016;39:161–71.
60. Wataganara T, Seshadri S, Leung TY, et al. Establishing prenatal surgery for myelomeningocele in Asia: the Singapore consensus. Fetal Diagn Ther. 2017;41:167–78.
61. American College of Obstetricians and Gynecologists. ACOG Committee opinion no. 550: maternal–fetal surgery for myelomeningocele. Obstet Gynecol. 2013;121:218–9.
62. Donepudi R, Papanna R, Snowise S, Johnson A, Bebbington M, Moise KJ Jr. Does anemia-polycythemia complicating twin-twin transfusion syndrome affect outcome after fetoscopic laser surgery? Ultrasound Obstet Gynecol. 2016;47:340–4.
63. Peeters SH, Stolk TT, Slaghekke F, et al. Iatrogenic perforation of intertwin membrane after laser surgery for twin-to-twin transfusion syndrome. Ultrasound Obstet Gynecol. 2014;44:550–6.
64. Galvan A, Alvarez E, Parraguirre S, Suarez ML, Perez A. Development of a fetal rabbit model to study amniotic band syndrome. Fetal Pediatr Pathol. 2012;31:300–8.