



Cystic Lesion in the Fetal Scalp: A Systematic Approach

Divya Singh¹ · Ladbans Kaur¹

Received: 22 April 2019/Revised: 3 July 2019/Accepted: 5 July 2019/Published online: 11 July 2019
© Society of Fetal Medicine 2019

Abstract During an anomaly scan, cystic lesion in the scalp may be encountered while examining the fetal head. Some of these originate from the scalp tissue and can be dealt with postnatally by simple excision. Others may be more than just scalp cysts and have an intracranial communication. The objective of this communication is to illustrate a few cystic lesions in the fetal scalp and suggest a systematic approach in arriving at a diagnosis.

Keywords Cystic lesion · Scalp · Calvarial defect · Meningocele

Introduction

A cystic lesion in the fetal scalp is occasionally encountered during an anomaly scan. Correct diagnosis is paramount for prenatal counselling. It may be an innocuous cyst confined to the scalp or may have an intracranial communication. The calvarial defect through which the cyst has an intracranial communication may be very minute. Detection of such small bony defects can pose a challenge. Optimal use of ultrasound can make tiny defects more evident. This involves use of high frequency transducers, switching off the harmonics to decrease image contrast, multi-planar imaging and three-dimensional (3D) surface rendering [1, 2]. False positive diagnosis of a calvarial defect is also possible when a suture line is mistaken for a defect or when the ultrasound beam is tangential to

the vault surface. Knowledge of suture anatomy, use of 3D surface rendering in skeleton mode and ensuring that sound beam is perpendicular to the surface where the calvarial defect is suspected obviates such false positive diagnosis.

Different Cystic Lesions

Occipital Meningocele

Figure 1a–c show a cystic lesion in the scalp in the occipital region which had an intracranial communication and was an occipital meningocele. The challenge here was to demonstrate the 2 mm sized calvarial defect through which the ‘scalp cyst’ was communicating with subarachnoid space. This was made easier by using a higher frequency linear transducer and switching off the harmonics. The factors favoring good outcome of an occipital meningocele are its small size (< 5 cm), lack of herniating brain tissue and absence of ventriculomegaly or any other abnormality [3].

Dermoid cyst

Figure 1d,e show another cystic lesion in the fetal scalp seen in the region of anterior fontanelle without an intracranial communication. This lesion lacked internal vascularity and was confirmed to be a dermoid cyst postnatally. It is important to ensure that scalp cysts are avascular. Presence of vascularity in a cystic scalp lesion with an intracranial communication steers the diagnostic algorithm in a different direction (Fig. 2). Sinus pericranii is a venous malformation of the scalp communicating with a dural venous sinus through a trans-osseous emissary vein

✉ Divya Singh
docdivyas@yahoo.co.in

¹ Prime Imaging and Prenatal Diagnostics, Sector 24 D, Chandigarh, India

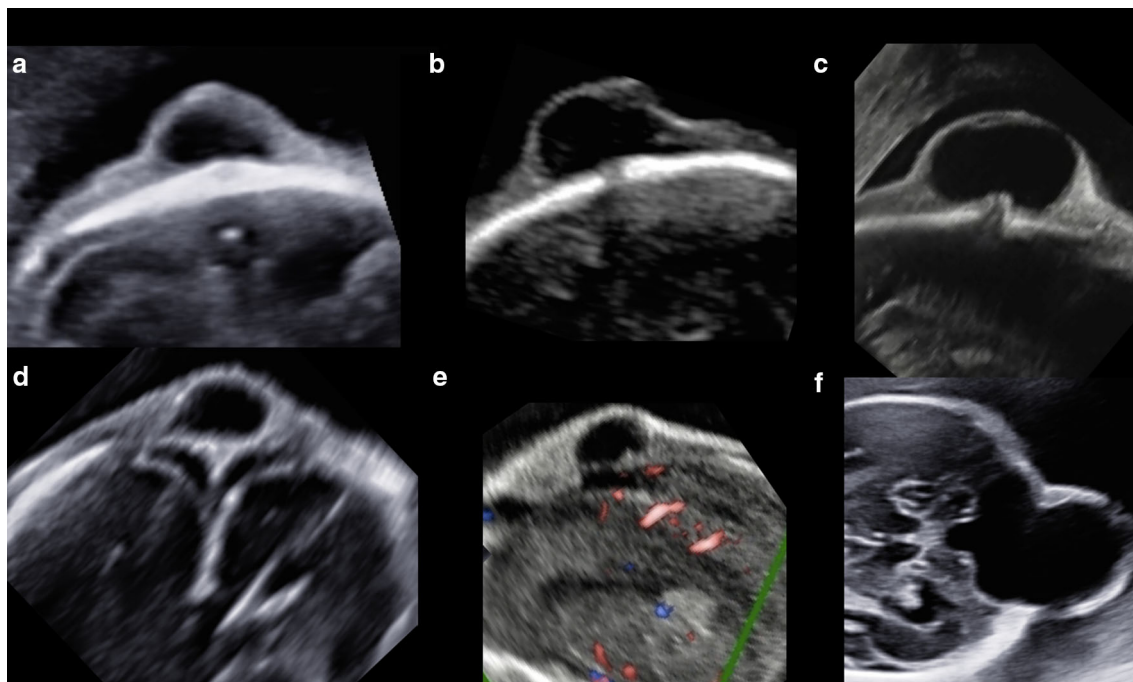
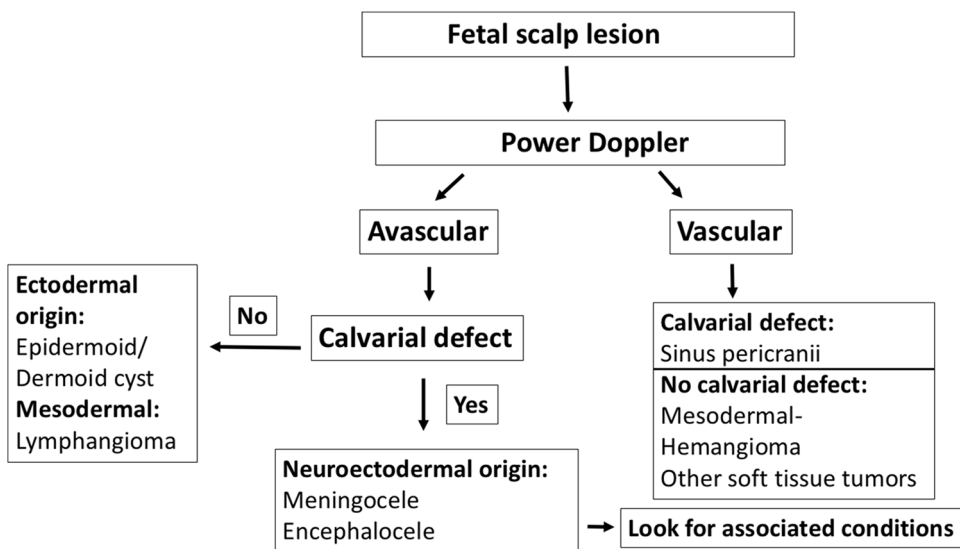


Fig. 1 Cystic lesions in the fetal scalp **a** Anechoic lesion of size 2.4×1.5 cm is seen in the midline in the occipital region of the scalp with suggestion of an underlying calvarial defect. **b** 2 mm sized calvarial defect under the cystic lesion (occipital meningocele) becomes more evident on switching off the harmonic mode. **c** Small calvarial defect in an occipital meningocele seen clearly using a high frequency transducer. **d** 1.7×1.4 cm anechoic lesion seen in the

midline in the region of anterior fontanelle. No underlying calvarial defect seen. **e** Absence of vascularity on power Doppler in the midline cystic lesion (dermoid) lacking intracranial communication. **f** Anechoic lesion of size 4.3×2.4 cm is seen in the occipital region of scalp which is communicating with a posterior fossa fluid collection in continuity with the fourth ventricle. Case of herniated Dandy Walker cyst

Fig. 2 Algorithm. Systematic approach for arriving at a diagnosis in a cystic lesion in the fetal scalp



[4]. This is treated by an endovascular or surgical approach.

Dandy Walker Malformation

Figure 1f shows another cystic lesion in the scalp in the occipital region with an obvious intracranial extension.

However, it is not just another meningocele which can be dealt with by excision. It is part of a large posterior fossa cyst in a case of Dandy Walker malformation which is herniating out through a calvarial defect. Such extracranial herniation of Dandy Walker cysts has been described previously [5]. It may occur through a defect in the occipital region or through the foramen magnum.

MR Imaging

Magnetic resonance imaging (MRI) has an excellent contrast resolution with multi-planar imaging capabilities. It may be particularly useful when sonographic assessment of a scalp cyst is suboptimal e.g., at an advanced period of gestation or in obese patients. MRI has an added advantage of detailed anatomic evaluation of the fetus in these situations to rule out associated intracranial and extracranial abnormalities [6]. This is beneficial in providing more accurate counselling regarding postnatal outcome. Use of various MR sequences can be useful in characterizing the scalp lesions by identifying presence of fat, blood or fluid within them. MRI has its limitations of cost, availability and spatial resolution.

Diagnostic Algorithm

We propose a diagnostic algorithm which may be useful in arriving at a diagnosis whenever one comes across a lesion in the fetal scalp (Fig. 2). This is based on initial identification of the presence or absence of vascularity in the scalp lesion. The next step is to look for an underlying calvarial defect suggesting an intracranial communication. If the lesion lacks vascularity and intracranial communication, the diagnostic algorithm is directed towards cystic scalp masses of ectodermal (dermoid/epidermoid cyst) or mesodermal (lymphangioma) origin. Presence of intracranial communication in an avascular cystic scalp lesion points towards neuro-ectodermal lesions like meningocele (lacking neural elements) or encephalocele (containing brain parenchyma). Presence of an encephalocele should prompt a thorough search for associated abnormalities which may suggest a possible syndrome. For instance, polycystic kidneys and polydactyly in Meckel Gruber syndrome. The presence of vascularity in a cystic scalp

lesion with an intracranial communication leads to a diagnosis of sinus pericranii. Whereas lack of intracranial communication in a vascular scalp mass suggests a mesodermal lesion of the scalp like hemangioma.

In conclusion, presence of a cystic lesion in the fetal scalp warrants a step-wise approach to arrive at a diagnosis which is imperative for antenatal counselling and management.

Compliance with Ethical Standards

Conflict of interest The authors declare that they have no conflict of interest.

References

1. Sepulveda W, Wong AE, Sepulveda S, Corral E. Fetal scalp cyst or small meningocele: differential diagnosis with three-dimensional ultrasound. *Fetal Diagn Ther*. 2011;30(1):77–80. <https://doi.org/10.1159/000322918>.
2. Timor-Tritsch IE, Monteagudo A, Santos R. Fine-tuning the diagnosis of fetal scalp cysts: the value of high-frequency sonography. *J Ultrasound Med*. 2008;27:1363–8.
3. Guthkelch AN. Occipital cranium bifidum. *Arch Dis Child*. 1970;45:104.
4. Weissmann-Brenner A, Kassif E, Katorza E, Achiron R, Gilboa Y. Soft-tissue mass of fetal scalp with abnormal course of dural sinuses. *Ultrasound Obstet Gynecol*. 2018;52:126–7. <https://doi.org/10.1002/uog.18817>.
5. Lee W, Vettraino IM, Comstock CH, Lal N, Kazmierczak C, Shetty A, Raff G, Zakalik K, Romero R. Prenatal diagnosis of herniated dandy-walker cysts. *J Ultrasound Med*. 2005;24:841–8. <https://doi.org/10.7863/jum.2005.24.6.841>.
6. Okaro E, Broussin B, Ville Y. Prenatal diagnosis of atypical cystic lesions of the fetal scalp. *Ultrasound Obstet Gynecol*. 1998;12:442–4. <https://doi.org/10.1046/j.1469-0705.1998.12060442.x>.

Publisher's Note Springer Nature remains neutral with regard to jurisdictional claims in published maps and institutional affiliations.