



# Exome Sequencing Identifies *RET* Associated Hirschsprung Disease in a Fetus with Echogenic Bowel

Gayatri Nerakh<sup>1,2</sup> · Ashwani Tandon<sup>3</sup> · Ashwin Dalal<sup>2</sup> · Shagun Aggarwal<sup>1,2</sup>

Received: 9 June 2019 / Accepted: 31 July 2019 / Published online: 23 August 2019  
© Society of Fetal Medicine 2019

**Abstract** This is report of a case of *RET* associated Hirschsprung disease in a fetus diagnosed using exome sequencing. The fetus initially presented with echogenic bowel at 16 weeks with maternal first trimester serum screen showing increased risk for Trisomy 21. Amniotic fluid karyotype,  $\Delta F508$  *CFTR* genotype and maternal TORCH serology were normal. Subsequent ultrasonograms showed dilated bowel loops, predominantly large bowel. Following delivery at 24 weeks, a post-mortem examination was performed. Dilated bowel was confirmed with no structural gut abnormality and no other dysmorphic finding. Histopathology revealed agangliosis confirming a diagnosis of Hirschsprung disease. Exome sequencing done on fetal DNA from amniotic fluid revealed a putative pathogenic heterozygous c.1438G > A variant in exon 7 of *RET* gene, which was inherited from the asymptomatic mother. This enabled genetic counseling and prenatal diagnosis in subsequent pregnancy.

**Keywords** Exome sequencing · *RET* · Hirschsprung disease · Fetal autopsy · Prenatal diagnosis

## Introduction

Hirschsprung disease is a congenital intestinal aganglionosis characterized by complete absence of neuronal ganglion cells from a variable length of the intestinal tract with an incidence of 1/50,000 live births. It may occur as an isolated finding or as part of a genetic syndrome [1]. Antenatal diagnosis of this condition is not possible as there are no specific sonographic findings except for increased bowel echogenicity or gut dilatation in rare cases. Genetic testing is also not straightforward in view of genetic heterogeneity and complex inheritance patterns. This is report of a fetus with echogenic bowel, which was subsequently found to have *RET* mutation associated Hirschsprung disease.

## Case Report

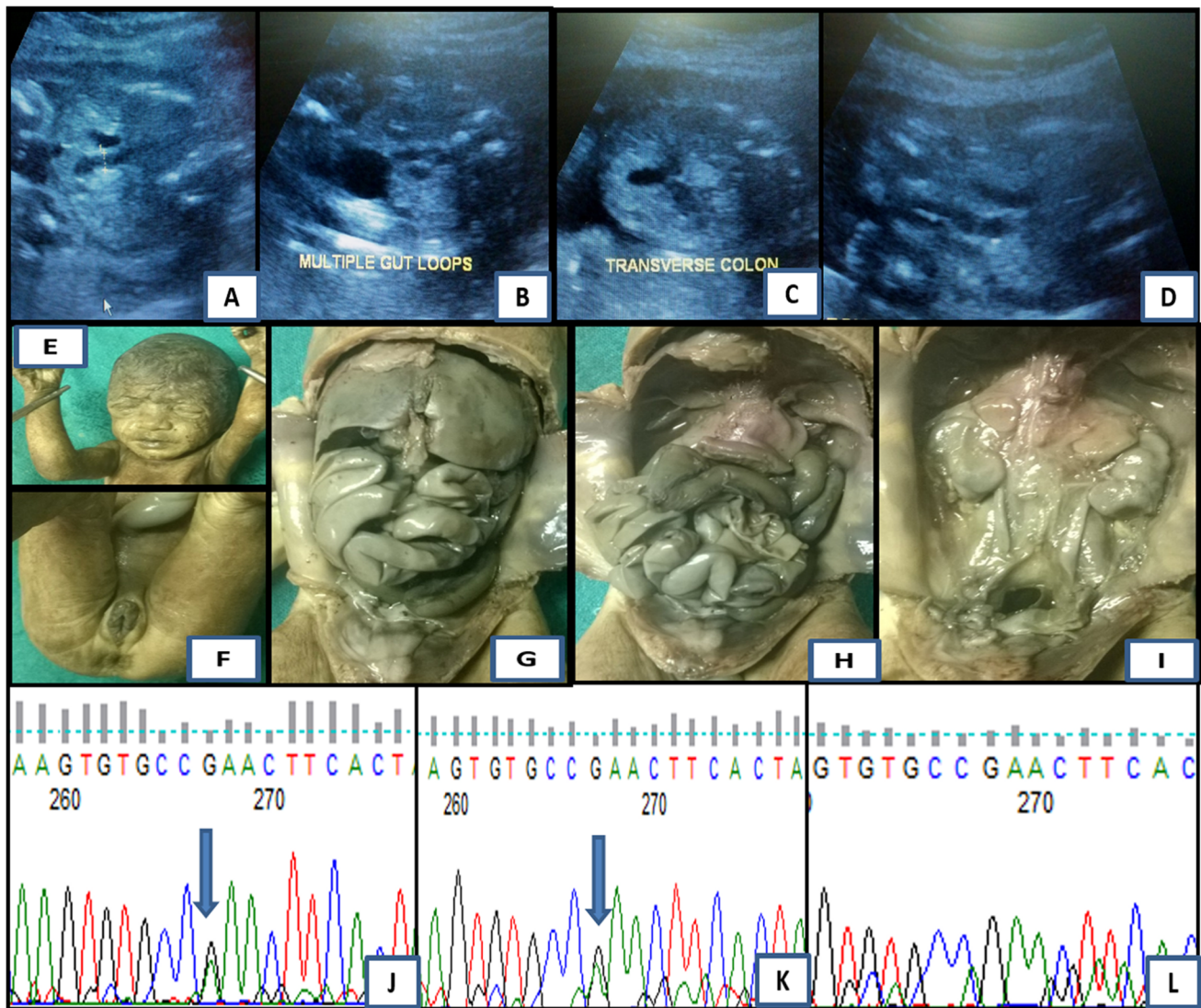
A 26 years old second gravida was referred for genetic counselling and testing in view of positive double marker for trisomy 21 at 14 weeks of gestation. The previous pregnancy had resulted in a blighted ovum. There were no other co-morbidities except for hypothyroidism in the present pregnancy. There was no history of constipation in the consultand and other family members. Past medical and family history was unremarkable. Ultrasonography at 16 weeks gestation revealed grade 3 echogenic bowel with no other obvious abnormality. Amniocentesis was done and fetal karyotype as well as targeted testing of  $\Delta F508$  variant of *CFTR* was normal. Maternal TORCH serology was normal. Couple was reassured and advised for follow up scan. At 20 weeks gestation, grade 3 echogenic bowel persisted. Subsequent ultrasound at 24 weeks revealed dilated large bowel loops extending right up to the pelvis

✉ Shagun Aggarwal  
shagun.genetics@gmail.com

<sup>1</sup> Department of Medical Genetics, Nizam's Institute of Medical Sciences, Punjagutta, Hyderabad, Telangana 500082, India

<sup>2</sup> Diagnostics Division, Centre for DNA Fingerprinting and Diagnostics, Hyderabad, Telangana, India

<sup>3</sup> Department of Pathology, Nizam's Institute of Medical Sciences, Hyderabad, Telangana, India



**Fig. 1** a–d Depict the ultrasound findings: a Transverse view of fetal abdomen showing dilated bowel loop with diameter measuring 5.3 mm which is more than the mean value 3.98 mm (95% CI for 24 weeks of gestation). b Transverse view of fetal abdomen with multiple dilated bowel loops. c Transverse view of fetal abdomen with dilated transverse colon. d Coronal view of fetal abdomen with dilated descending colon extending into pelvis. e–i Depict autopsy

findings: e subtle facial dysmorphism, f patent anal opening, g small bowel loops dilatation, h large bowel loops dilatation, i anorectal continuity. j–l Show variant in *RET* gene in the family: j heterozygous variant NM\_020975: c.1438G > A in exon 7 of *RET* gene in the fetus. k Heterozygous variant NM\_020975: c.1438G > A in exon 7 of *RET* gene in the mother. l Normal sequence in the father

(Fig. 1a–d). No other sonographic abnormality was detected. Paediatric gastroenterology opinion was taken and the couple counselled regarding the uncertain prognosis of this finding. Following delivery of a stillborn at 24 weeks, autopsy was performed.

On autopsy evaluation, external examination of fetus showed subtle nonspecific dysmorphism in the form of wrinkled forehead, excessive skin folds on the eye lids and periorbital region, mild low set ears, underfolded ear helices, prominent antitragus, and wide, depressed nasal bridge (Fig. 1e). No external malformations were present. External genitalia were normal female and a patent anal

opening was present. Anthropometric parameters were within normal limits. Fetal radiographs were unremarkable. On intra-abdominal examination, distended and dilated large and small bowel loops were seen with no obvious stricture or atresia with recto-anal continuity suggestive of total intestinal aganglionosis. No meconium inspissation was appreciated (Fig. 1f–i). Other abdominal organs and intrathoracic examination was unremarkable. A provisional diagnosis of Hirschsprung disease was considered on basis of these findings. Histopathological examination of the dilated bowel loop specimen revealed scanty ganglion cells

and immunohistochemistry with calretinin confirmed agangliosis.

A targeted exome sequencing of known disease causing OMIM genes was performed on fetal DNA extracted from amniocytes. A heterozygous c.1438G > A variant was identified in exon 7 of *RET* gene. This variant is classified as likely pathogenic using ACMG variant classification criteria as it has previously been reported in Hirschsprung disease [2, 3], is consistent with disease phenotype, has low population allele frequency (0.21%), is predicted to be damaging by mutation taster and is conserved across mammalian species. The variant was validated by Sanger sequencing in the family, and the asymptomatic mother was also found to be heterozygous for the same variant (Fig. 1j–l). The family was counselled regarding the recurrence risk of 50% in subsequent conceptions and surveillance for MEN2 associated cancers advised for the mother.

## Discussion

Exome sequencing has enabled detection of single gene disorders in 20–30% of fetuses with antenatally detected structural malformations in various case series [4]. However, the utility of this technology for other fetal sonographic abnormalities is yet to be evaluated. The present case demonstrates the use of exome sequencing in a fetus with antenatal findings of echogenic bowel evolving into gut dilatation, and subsequent autopsy finding of Hirschsprung disease. This fetus was found to have a maternally inherited *RET* variant, which was non-penetrant in the mother.

HD is an etiologically heterogeneous disorder which can present as a component of various genetic syndromes or as a non-syndromic isolated abnormality. Many of these syndromes are associated with other postnatal co-morbidities [1]. The syndromic HDs cannot usually be distinguished antenatally from non-syndromic forms on basis of ultrasound findings alone. Antenatal genetic testing remains the only modality to distinguish these.

Non-syndromic HD shows *RET* variants in 50% familial cases and 15–35% simplex cases. Variants in other genes involved in the *RET* activation pathways, *EDNRB* pathways and *RET/EDNRB* pathways are also reported in HD [5]. *RET* mutations are known to show incomplete penetrance for HD, with 65–72% males and 45–51% females showing phenotypic manifestation [1]. *RET* mutations are also causative for other phenotypes like Multiple Endocrine Neoplasia type 2A, Medullary thyroid carcinoma (MTC) and Central hypoventilation syndrome. In a study of 44 families with MEN2A, 7 families showed co-segregation of HD and MEN2A. All these families had exon 10

mutations at specific positions. This has important implications for introducing surveillance measures for MEN2A related cancers in patients with *RET* associated HD, especially individuals with exon 10 variants [6]. The surveillance for MEN2A should start at the age of 8 years in those with variants in codons 630 and 634 and for the individuals with other *RET* pathogenic variants by 20 years of age. Surveillance includes annual calcitonin to monitor for MTC and annual plasma free metanephrins and normetanephrins or 24 h urine collection for metanephrins and normetanephrins for pheochromocytoma.

Echogenic bowel is a sonographic soft marker which is associated with a favourable outcome in majority of cases [7]. However, in up to 3% fetuses it is representative of a gut malformation, which may become evident antenatally at later gestation as dilated bowel or may be a postnatal diagnosis [8]. Hirschsprung disease has been reported to present with echogenic bowel in antenatal period in 2/22 cases in one retrospective study [9]. There is one prospective case report of fetal echogenic bowel that evolved into gut dilatation in third trimester and was subsequently diagnosed to be HD in neonatal period [10] and another case report of antenatal detection of dilated bowel loops at 36 weeks of gestation in a baby subsequently diagnosed to have HD in neonatal period [11]. None of these cases were investigated for underlying molecular defects.

The present family was counselled regarding the need for MEN2A surveillance in the mother. In view of incomplete penetrance of *RET* variants, they were informed that although there is 50% risk of subsequent offsprings inheriting the *RET* variant, the exact disease affection status could not be predicted antenatally with certainty.

As antenatal ultrasonography based diagnosis of gut malformations remains challenging, it is interesting to contemplate the relevance of genetic testing including karyotyping followed by exome sequencing for single gene disorders in such a setting. The detection of a mutation associated with a syndromic presentation would have important prognostic implications for the family and enable decision making regarding the pregnancy. In addition, molecular diagnosis also has implications for MEN2A surveillance in *RET* mutation carriers and raises counseling difficulties for subsequent pregnancies due to incomplete penetrance of these variants.

## Conclusion

The case reported here highlights the relevance of antenatal monitoring of unexplained echogenic bowel for possible gut abnormalities and the importance of postnatal

evaluation and histopathological examination in such scenarios for definitive diagnosis. The report also describes an antenatally diagnosed case with *RET* associated HD and suggests the potential for application of exome sequencing as a prenatal diagnostic technique for non-structural antenatal sonographic abnormalities. In addition, this report illustrates the importance of molecular diagnosis on the subsequent genetic counseling of the family with wider impact with regards to cancer surveillance in asymptomatic *RET* variant carriers, and the challenges in prenatal prognostication due to incomplete penetrance of these variants.

#### Compliance with Ethical Standards

**Conflict of interest** The authors declare that they have no conflict of interests.

#### References

1. Amiel J, Sproat-Emison E, Garcia-Barcelo M, Lantieri F, Burzynski G, Borrego S, et al. Hirschsprung disease consortium: hirschsprung disease, associated syndromes and genetics: a review. *J Med Genet*. 2008;45(1):1–14.
2. Julies MG, Moore SW, Kotze MJ, du Plessis L. Novel *RET* mutations in Hirschsprung's disease patients from the diverse South African population. *Eur J Hum Genet*. 2001;9(6):419–23.
3. So MT, Leon TY, Cheng G, Tang CS, Miao XP, Cornes BK. *RET* mutational spectrum in Hirschsprung disease: evaluation of 601 Chinese patients. *PLoS ONE*. 2011;6(12):e28986.
4. Drury S, Trump N, Williams H, Boustred C, GOSGene, Lench N, et al. Exome sequencing for prenatal diagnosis of fetuses with sonographic abnormalities. *Prenat Diagn*. 2015;35(10):1010–7.
5. Bahrami A, Joodi M, Moetamani-Ahmadi M, Maftouh M, Hassanian SM, Ferns GA, et al. Genetic background of hirschsprung disease: a bridge between basic science and clinical application. *J Cell Biochem*. 2018;119(1):28–33.
6. Sam WM, Monique Z. The Hirschsprung's-multiple endocrine neoplasia connection. *Clinics*. 2012;67(suppl 1):63–7.
7. Buitter HD, Holswilder-Older Scholtenhuis MA, Bouman K, Baren RV, Bilardo CM, Bos AF, et al. Outcome of infants presenting with echogenic bowel in the second trimester of pregnancy. *Arch Dis Child Fetal Neonatal Ed*. 2013;98(3):256–9.
8. Kesrouani AK, Guibourdenche J, Muller F, Denamur E, Vuillard E, Garel C, et al. Etiology and outcome of fetal echogenic bowel. Ten years experience. *Fetal Diagn Ther*. 2003;18(4):240–6.
9. Jakobson-Setton A, Weissmann-Brenner A, Achiron R, Kuint J, Gindes L, et al. Retrospective analysis of prenatal ultrasound of children with Hirschsprung disease. *Prenat Diagn*. 2015;35(7):699–702.
10. Bashiri A, Burstein E, Hershkowitz R, Maor E, Landau D, Mazor M, et al. Fetal echogenic bowel at 17 weeks gestational age as the early and only sign of a very long segment of Hirschsprung disease. *J Ultrasound Med*. 2008;27(7):1125–6.
11. Gupta A, Aneja A, Mehta S, Fazal TS. Antenatal diagnosis of hirschsprung disease. *J Fetal Med*. 2014;1:99–101.

**Publisher's Note** Springer Nature remains neutral with regard to jurisdictional claims in published maps and institutional affiliations.