



Prenatal Diagnosis of Fetal Immature Oropharyngeal Teratoma in the First Trimester: A Case Report

Shaheen Banu¹ · Hafiz Mohamad² · Aditi Dubey² · Nithya Elango³ · Seneesh Kumar Vikraman^{2,4} 

Received: 23 December 2020 / Accepted: 6 February 2021 / Published online: 6 March 2021
© Society of Fetal Medicine 2021

Abstract Epignathus or oro-pharyngeal teratoma is an extremely rare, benign congenital tumor, occurring in 1 in 35,000–200,000 live births. They usually arise from the sphenoid region of the hard palate, posterior nasopharynx, upper lip and nose, soft palate, tonsil or tongue. The typical appearance is that of a solid irregular mass containing both cystic and solid elements, protruding from the oral cavity. Their occurrence in the first trimester is extremely rare. We report a case of fetal immature orofacial teratoma detected in the first trimester and confirmed with histopathological diagnosis. The index pregnancy presented at 13 1/7 weeks of gestation. Ultrasound examination demonstrated an irregular, mixed echogenic mass with solid and cystic components protruding from the fetal mouth, between the tongue and the palate. Following extensive counselling, the couple opted for termination of the pregnancy. Histopathological examination confirmed the tumor to be an immature oral teratoma.

Keywords Epignathus · Oropharyngeal teratoma · Fetal immature teratoma · Fetal tumors · Early target scan

Introduction

Oropharyngeal teratoma or epignathus is an extremely rare, benign congenital tumor, occurring in 1 in 35,000–200,000 live births [1]. The incidence of congenital teratomas at all sites is 1 in 4000 live births with less than 2% of these being oropharyngeal. Advances in fetal imaging techniques has facilitated early diagnosis and detailed characterization of these fetal tumors [2]. Their presentations in the first trimester is, however, extremely rare [3]. We report a case of prenatal diagnosis of immature oral teratoma in the first trimester with its ultrasound and histopathological findings.

Case Report

A 28 years old Indian woman, second gravida with a previous healthy child, was referred to our fetal medicine unit at 13 1/7 weeks of gestation for an early target scan. Detailed questioning revealed nothing relevant. The ultrasound examination demonstrated a single viable intrauterine fetus with a crown rump length of 66.9 mm, appropriate for the gestational age of 13 1/7 weeks. A 21 × 18 × 16 mm irregular, mixed echogenic mass with solid and cystic areas was noted protruding from the fetal face between the tongue and the palate (Fig. 1). Three-dimensional ultrasonography confirmed the origin of mass from the orofacial region probably from the floor of the mouth. There was no vascular signal in the Doppler examination of the lesion. Detailed anatomical survey did not reveal any extra-facial abnormalities. Based on these observations, a presumptive diagnosis of oropharyngeal teratoma was made.

The couple were informed about the condition and its prognosis. They denied the offer of prenatal invasive

✉ Seneesh Kumar Vikraman
drseneeshkv@gmail.com

¹ ARMC Kannur, Kannur, Kerala, India

² ARMC AEGIS Hospital, Perinthalmanna, Kerala, India

³ ARMC Salem, Salem, Tamil Nadu, India

⁴ Lakshmi Bhavan, Pallipuram PO, Via Pattambi, Palakkad, Kerala 679305, India

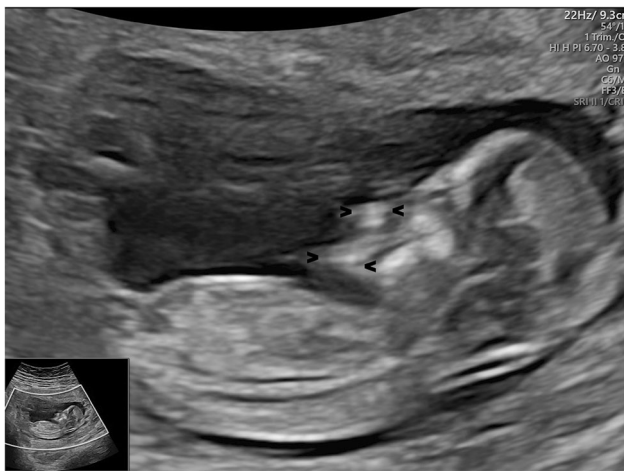


Fig. 1 Sagittal image of the fetus at 13 + 1 weeks showing an irregular solid-cystic mass (arrow heads) arising from the fetal mouth

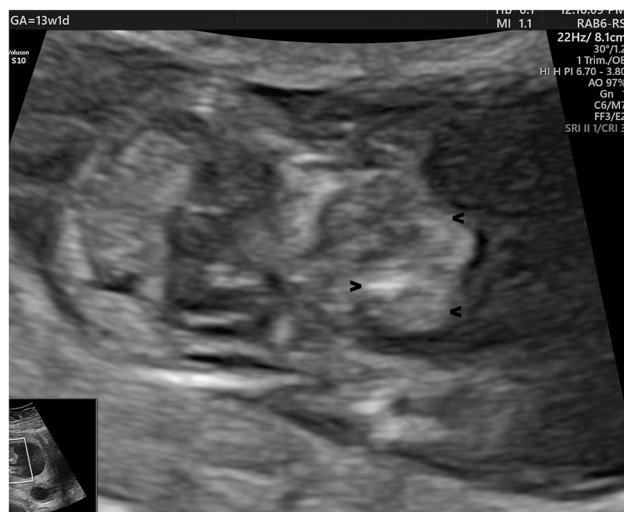

Fig. 2 Zoomed sagittal image of the facial profile showing the irregular solid-cystic mass arising from fetal oral cavity (black arrow heads)

genetic testing and opted for termination of the pregnancy. A fresh stillborn fetus was delivered showing an irregular mass emanating from the floor of the mouth. Histopathological examination of the tumor confirmed the diagnosis of immature teratoma (Fig. 1).

Discussion

Congenital epignathus is rare and accounts for 2–9% of all teratomas [4]. The most common theory proposes growth of pluripotential cells in Rathke's pouch in a disorganized fashion [5]. Mature teratomas are composed of tissues derived from the three germ layers. Immature teratomas, in

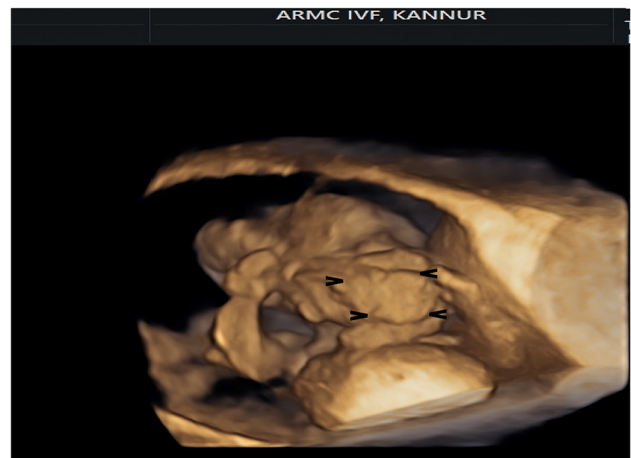


Fig. 3 Three dimensional surface rendering of oro-pharyngeal teratoma

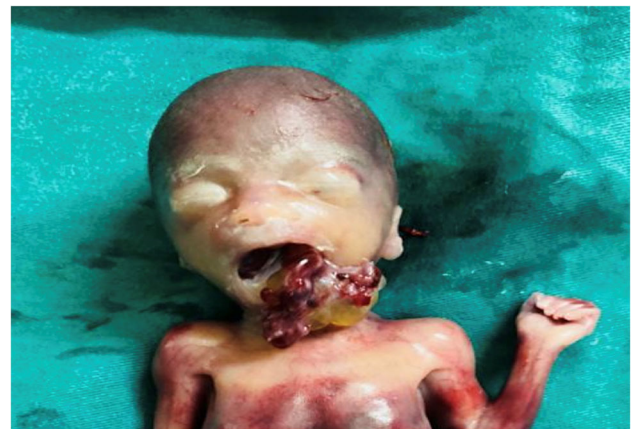

Fig. 4 Magnified post-abortal image of the fetus showing the oro-pharyngeal teratoma

addition, also have a prominent neuroectodermal component [6].

They usually arise from the sphenoid region of the hard palate, but other sites include posterior nasopharynx, upper lip and nose, soft palate, tonsil or tongue. Epignathus is associated with additional malformations in 6% of cases. A cleft palate is the most common associated malformation, as the tumor interrupts closure of the palate. Epignathus protrudes from the skull base through the palate into the oral cavity. A few of these tumors extend bidirectionally involving the brain tissues as well. Other associated malformations include bifid tongue or nose, glossoptosis, diaphragmatic hernia, nasopharyngeal teratoma and inguinal hernia [1]. The association with chromosomal abnormalities or monogenic syndromes is extremely rare. Most cases of epignathus are sporadic with no increased risk of recurrence in the subsequent pregnancies [7].

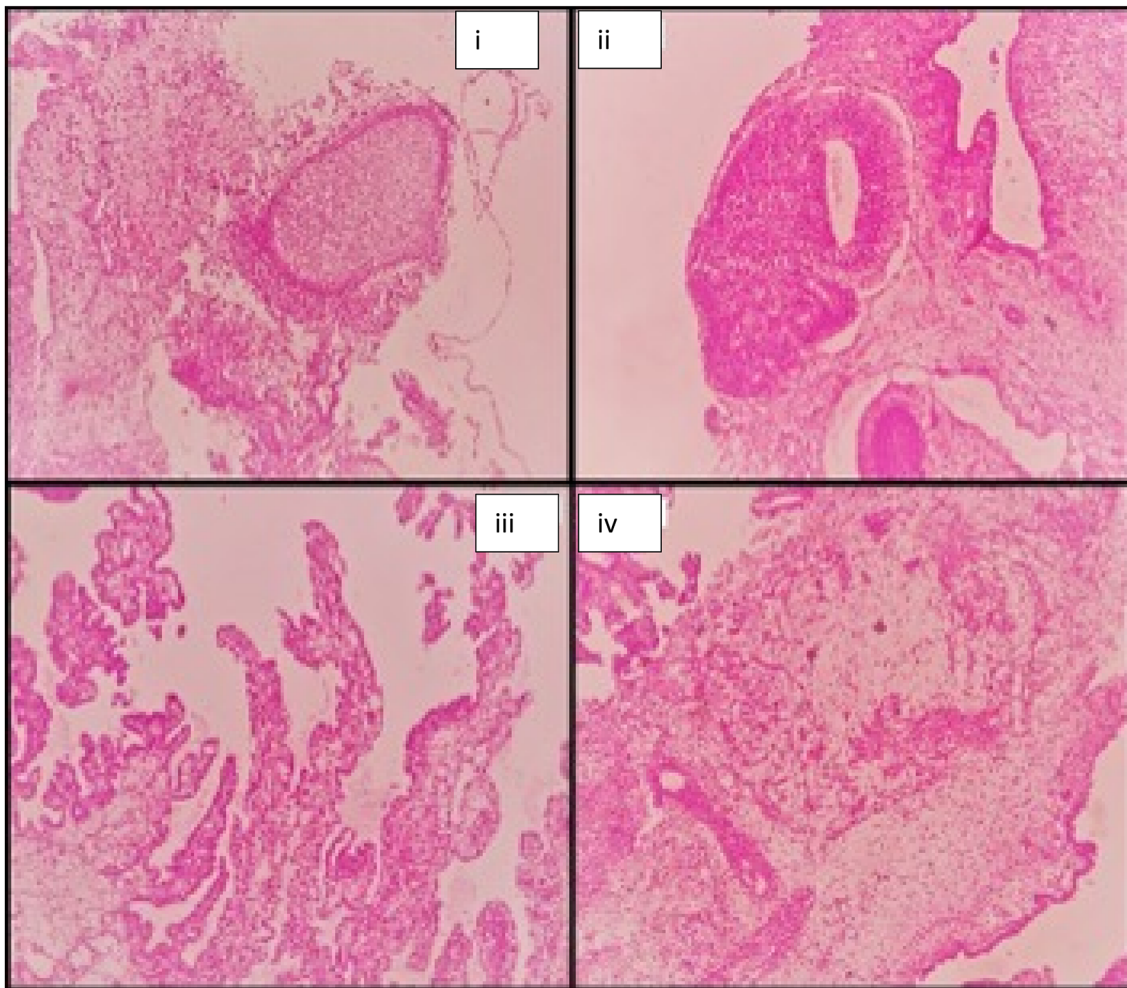


Fig. 5 Key histopathological features of immature teratoma, i: mature cartilage, ii: immature neuroepithelium forming rosettes, iii: choroid plexus and iv: glial tissue

Table 1 The differential diagnosis for oro-pharyngeal tumors [15]

Type	Key ultrasound Imaging features
Foregut duplication cyst	Hypoechoic lesion with a heterogenous internal echotexture and regular margins
Frontal encephalocele	Pure cystic mass or may contain internal echoes from herniated brain tissues. A cystic mass indicates the predominant component as meningocele
Myoblastoma	Cystic mass with internal echoes; Colour Doppler shows marked vascularity within the tumor
Cystic hygroma	Complex cystic mass with septations and may present as a nuchal cyst; associated with fetal hydrops and anasarca
Haemangioma	Well-defined echogenic mass with prominent internal vascularity on Colour Doppler imaging
Ranula	Thin-walled cystic lesion. Infected cysts have thicker wall and internal echoes
Neurofibroma	Well defined round to oval shape mass with homogenous hypoechoic appearance and through transmission and internal vascularity
Rhabdomyosarcoma	Heterogenous well defined irregular mass of low to medium echogenicity

Three dimensional ultrasonography with surface shaded display and volume rendering has limitations in the first trimester due to increased fetal movements and inadequate volume rendering. Fetal magnetic resonance imaging

(MRI) is a complementary diagnostic tool for epignathus diagnosed in later gestation, especially in deciding for an ex-utero intrapartum (EXIT) therapy procedure [8]. Additionally, it aids in the assessment of the intracranial

invasion of the tumor which is an important prognostic factor [9, 10].

The detection of a fetal oral mass is a management dilemma [11, 12]. The important prognostic factors are size and location of the tumor, the rate of growth, associated polyhydramnios, and the degree of intracranial spread. Polyhydramnios indicates the severity of airway obstruction and the extent of tumor invasion; it is also associated with an increased risk of preterm labor, preterm premature rupture of membranes and neonatal respiratory distress [1]. Intracranial extension of the mass is not uncommon and the prognosis is not good in such cases [13]. Malignant transformation occurs rarely and is difficult to predict antenatally (Figs. 2, 3, 4, 5).

In fetuses with prenatally suspected tracheal-oro-pharyngeal obstruction, cesarean delivery and subsequent intubation by tracheostomy before the umbilical cord is clamped, as prescribed in the EXIT procedure, or resection of the tumor mass while the neonate is on placental support should be considered [10]. However large tumors may preclude immediate intubation and oxygenation and surgical removal may prove tedious owing to modification of the anatomical landmarks [14]. Alternatively, a short EXIT procedure limited to secure the airway of the fetus followed by early surgery is preferable. Confirmative resection under placental support has also been recommended [1].

The differential diagnosis of fetal oro-pharyngeal tumors is described in Table 1 [15].

Conclusion

Fetal teratomas are rare congenital tumors which differ in their histology, anatomic distribution and biologic behaviour compared to their paediatric counterparts. As routine antenatal ultrasound examinations have increased their detection, it is important to be familiar with their imaging and pathophysiological characteristics, which determines their management and prognosis.

Compliance with ethical standards

Conflict of interest The author declare that he has no conflict of interest.

Informed Consent Informed consent is not required as it is a review article.

Human and Animal Rights Statement It is not a research involving Human participants and/or animals.

References

1. Moon NR, Min JY, Kim YH, Choi SK, Shin JC, Park IY. Prenatal diagnosis of epignathus with multiple malformations in one fetus of a twin pregnancy using three-dimensional ultrasonography and magnetic resonance imaging. *ObstetGynecolSci*. 2015;58(1):65–8.
2. Chervenak FA, Tortora M, Moya FR, Hobbins JC. Antenatal sonographic diagnosis of epignathus. *J Ultrasound Med*. 1984;3:235–7.
3. Dar P, Rosenthal J, Factor S, Dubiosso R, Murthy AS. First-trimester diagnosis of fetal epignathus with 2- and 3-dimensional sonography. *J Ultrasound Med*. 2009;28(12):1743–6.
4. Takagi MM, Bussamra LC, Araujo Júnior E, Drummond CL, Herbst SR, Nardoza LM, et al. Prenatal diagnosis of a large epignathusteratoma using two-dimensional and three-dimensional ultrasound: correlation with pathological findings. *Cleft Palate Craniofac J*. 2014;51(3):350–3.
5. Haghighi K, Milles M, Cleveland D, Ziccardi V. Epignathusteratoma with bifid tongue and median glossal salivary mass: report of a case. *J Oral MaxillofacSurg*. 2004;62:379–83.
6. Noguchi T, Jinbu Y, Itoh H, Matsumoto K, Sakai O, Kusama M. Epignathus combined with cleft palate, lobulated tongue, and lingual hamartoma: report of a case. *Oral Surg Oral Med Oral Pathol Oral RadiolEndod*. 2006;101:481–6.
7. Huang Y, Pan H. A fetus with a mass in the oral cavity: a rare case of oral immature teratoma. *Int J ClinExpPathol*. 2017;10(7):7890–2.
8. Tonni G, De Felice C, Centini G, Ginanneschi C. Cervical and oral teratoma in the fetus: a systematic review of etiology, pathology, diagnosis, treatment and prognosis. *Arch GynecolObstet*. 2010;282:355–61.
9. Sichel JY, Eliashar R, Yatsiv I, Moshe Gomori J, Nadjari M, Springer C, et al. A multidisciplinary team approach for management of a giant congenital cervical teratoma. *Int J PediatrOtorhinolaryngol*. 2002;65:241–7.
10. Noah MM, Norton ME, Sandberg P, Esakoff T, Farrell J, Albanese CT. Short-term maternal outcomes that are associated with the EXIT procedure, as compared with cesarean delivery. *Am J ObstetGynecol*. 2002;186:773–7.
11. Borsellino A, Zaccara A, Nahom A, Trucchi A, Aite L, Girolandino C, et al. False-positive rate in prenatal diagnosis of surgical anomalies. *J PediatrSurg*. 2006;41(4):826–9.
12. Thilaganathan B, Sairam SH, Papageorgiou AT, Bhide A. Problem-based obstetric ultrasound. London: Informa UK Ltd.; 2007. p. 43–50.
13. Kamil D, Tepelmann J, Berg C, Heep A, Axt-Flidner R, Gembruch U, et al. Spectrum and outcome of prenatally diagnosed fetal tumors. *Ultrasound ObstetGynecol*. 2008;31:296–302.
14. Clement K, Chamberlain P, Boyd P, Molyneux A. Prenatal diagnosis of an epignathus: a case report and review of the literature. *Ultrasound ObstetGynecol*. 2001;18:178–81.
15. Auffant J, Carlan SJ. Fetal oral mass. *J Diagn Med Sonogr*. 2012;28(4):183–6.

Publisher's Note Springer Nature remains neutral with regard to jurisdictional claims in published maps and institutional affiliations.