J. Fetal Med. (June 2022) 9:29–33
https://doi.org/10.1007/s40556-022-00338-6

REVIEW ARTICLE

Fetal 3D Imaging and HDlive Silhouette in Unraveling a Rare Case of Gall Bladder Anomaly with Fetal MRI Correlation

Purvi Agrawal[1] · T. P. Suman[1] · Sudhakar Banakar[1] · Adinarayana Makam[1]

Received: 28 October 2021 / Accepted: 1 February 2022 / Published online: 1 June 2022

Abstract Current technology and rapidly evolving Three-dimensional (3D) and Four-dimensional (4D) ultrasound techniques with advanced High Definition live (HD live) application has made Fetal medicine accomplishable. The introduction of high-frequency probes and evolution from hand swept slice acquisition to mechanically oscillating to electronically oscillating transducers with complex post-processing algorithms has led to the visualization of 3D view or real-time 3D view (4D) of fetal structures. In this review, we present a rare antenatal case of duplication of the gall bladder, highlight the utility of 3D/4D imaging and HD live Silhouette aiding in better understanding anatomical relationships, diagnosis, and implication in counseling.

Keywords Fetal gall bladder duplication · 3D silhouette · HD live Silhouette · Fetal liver and gall bladder

Introduction

Fetal ultrasound plays a vital role in the early detection of various anomalies in the late first and in the second trimester. In this era of rapidly evolving technology, there are many significant of advances in fetal medicine with improved diagnostic accuracy, leading to a positive impact on patient care. The novel technology of 3D ultrasound with volume acquisitions and introduction of HDlive Silhouette rendering has been a non-invasive problem-solving tool in detecting anomalies even at early stages and offers a virtual view of fetal structures which can be used to counsel the patients. In this review, we discuss 3D ultrasound imaging and newly developed rendering application HDlive Silhouette. Furthermore, we present and discuss a review of literature about a rare prenatal case of Gall bladder duplication in the 24th week of gestational age with fetal MRI correlation highlighting the role of 3D Ultrasound and HDlive Silhouette in diagnosis, counseling and its clinical impact. This technique has been employed for the first time in this condition and is extremely precise.

✉ Purvi Agrawal
agrawalpurvi0@gmail.com

[1] ADI's Advanced Centre for Fetal Care, Sparsh Hospital, Yeshwanthpur, Bangalore 560022, India

Discussion

3D Ultrasound Imaging, HDlive AND HDlive Silhouette

Over the last few decades, there have been significant technical improvements in 3D imaging with better volume acquisitions of fetal structures. 3D imaging is a three-dimensional view of structures that are acquired from two-dimensional data sets and volume acquisitions. Baba et al. first described 3D ultrasound imaging in 1989 using a mechanical 2D probe which was time-consuming [1]. A year later National Cheng Kung University, Taiwan demonstrated its first clinical utility on fetal face and spine using a convex volumetric probe [2]. This led to significant interest in its utilization in the assessment of various fetal anomalies and its rapid development worldwide.

The main principle behind 3D ultrasound images is the volume (voxel) acquisition by the movement of integrated transducers to acquire a series of slices at different orientations. First 2D greyscale data sets at any orientation are acquired which are combined by the computer program to

form a 3D image based on distance and angulation of ultrasound beams in 2D which can be stored and retrospectively viewed as required [3, 4]. There has been significant development in transducers starting from mechanical scanners to the present electronically oscillating transducers, improving assessment of complex anatomical structures along with surface and volume rendering. There has been evidence that visualization of the 3D virtual images of a fetus by the mother has triggered maternal–fetal bonding [5].

Improved image quality is the main determining factor in the assessment of congenital anomalies in pregnancy and better assessment of complex anatomical structures. The introduction of the novel technique "HDlive" has improved 3D/4D images to a great extent and has offered virtual viewing. Further addition of HDlive silhouette, an inner fluid-filled structures can be assessed through a transparent outer surface. With this so-called 'see-through fashion' images provide detailed anatomical visualization and depth perception of structures inside the morphological structure. The algorithm creates a gradient at organ boundaries, fluid-filled cavities, and vessel walls, where an abrupt change in the acoustic impedance exists within tissues [6]. The images are dependant on the degree of gain, threshold, and silhouette [7]. This new method exploits the superb image quality provided by the latest generation of beamforming technology, speckle reduction algorithms, and compound resolution imaging technology.

The main limitation of 3D ultrasound is a geometrical distortion which is dependent on 2D image acquisition [8]. HDlive silhouette technique is limited by decrease in quality of the rendered image by fetal or maternal movement and amount of amniotic fluid around the fetus [9].

A Case Report with Review of Literature

A 38 year of primipara presented at 24 weeks of gestational age with an uneventful pregnancy and with a suspicion of biliary anomaly of the fetus. On Ultrasound examination fetal biometric parameters were normal. On anatomical survey there were two separate anechoic pear-shaped parallel cystic structures just below the liver surface and right lateral to the umbilical vein of the fetus (Fig. 1). There was no color uptake or intrahepatic cystic structures. Otherwise, liver and other anatomical surveys were normal. With these imaging findings, we concluded it to be a duplicated or double gall bladder. We then performed 3D imaging with HDlive Silhouette to better assess the anatomy with which we could see the relationship of these structures with the liver and that each of these two cystic structures was connected by two ducts to form a common confluence and forming a "Y shape" (Fig. 2). We concluded with a diagnosis of "Y shaped" duplication of the gall bladder with no other associated anomalies. To confirm and further evaluate the biliary tree the patient underwent MRI which showed two gall bladders with two separate ducts connecting to the common cystic duct (Fig. 3). A diagnosis of Type 1 "Y-shaped" duplication of the gallbladder was then confirmed.

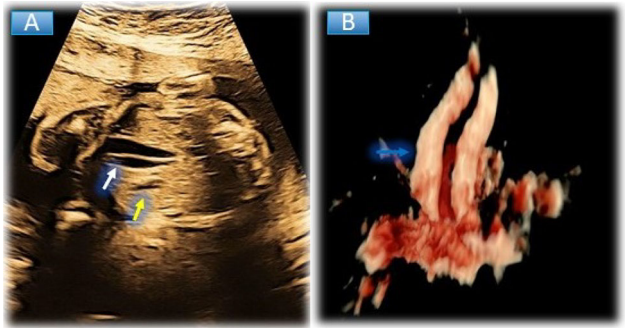

Fig. 1 Antenatal Ultrasound, **A** 2D Greyscale image at the level of the fetal upper abdomen and **B** HDlive rendered image, demonstrating two pear-shaped parallel anechoic structures in the gall bladder fossa (white arrow), right lateral to the umbilical vein (yellow arrow), HDlive rendered image showing the same with no clear delineation of the cystic duct

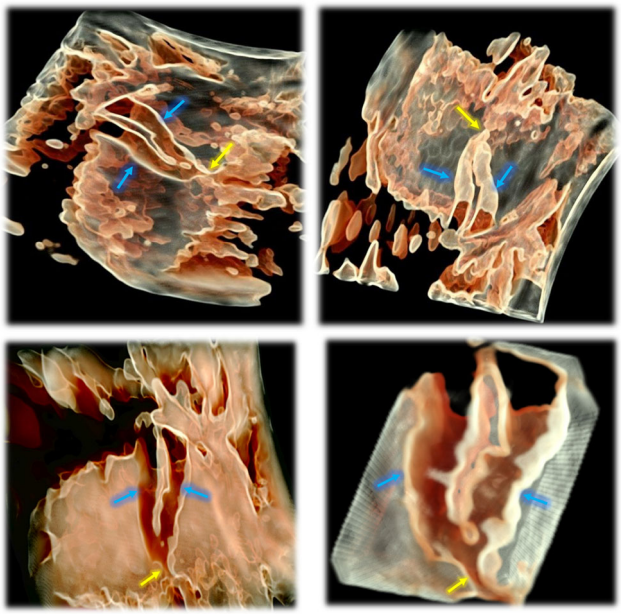

Fig. 2 HDlive SILHOUETTE images demonstrating two gall bladders (blue arrows) with separate cystic ducts fusing to form a confluence, and, common cystic duct (yellow arrows) – Type 1 Y-shape Duplication of Gall Bladder

Duplication of the gallbladder is a rare congenital anomaly of the biliary system with an incidence of approximately 1 in 4000 individuals [10]. It has equal sex predilection. It occurs during the 5th to 6th week of embryogenesis during which a single primordium bifurcates and is due to exuberant budding of the developing

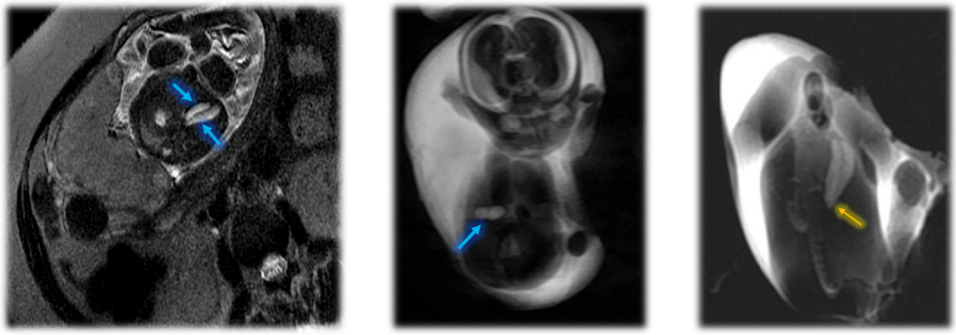

Fig. 3 Fetal MRI—Axial T2 and Heavily T2 weighted images showing two separate gall bladders in the GB fossa (blue arrows) forming a common confluence (yellow arrow) proximally comparable with HDlive Silhouette images above – Type 1 Y-shape Duplication of Gall Bladder

biliary tree when the caudal bud of the hepatic diverticulum divides. The type of duplication is dependent on the time that bifurcation occurs [11]. This anomaly was first described in 1674 by Blasius and the first report of surgical removal of a double gallbladder was by Sherren in 1911. Various variations in gallbladder duplication have been proposed. According to Boyden, Gall bladder duplication are classified into 1. Vesica fellea divisa which is bilobed gallbladder with one cystic duct and 2.Vesica fellea duplex which is true gallbladder duplication, subclassified into "Y-shaped type" (two cystic ducts uniting before entering the common bile duct), and "H-shaped or ductular type" (two cystic ducts enter separately into the common bile duct) [11]. Later Harlaftis et al. classified into three main types based on morphology and embryogenesis (Fig. 4a–c) which is now most commonly accepted classification [12].

Concomitance with other congenital anatomic variations in the biliary tree and hepatic artery has been described. Tracking biliary tree for anomalies is essential not only for diagnosis/classification but also for future surgical outcomes if any [13]. A very rare case of the duplicated fetal gallbladder with a novel chromosomal mutation (46, XX, t(X;10) (p11.2;q24.3) has been reported [14]. There has been no association with fatal fetal anomalies, however, foregut malformations, aberrant hepatic and mesenteric vessels associations are seen [15, 16].

There are only a few case reports on the prenatal diagnosis of Duplicated Gall Bladder. According to our research, we have found only 7 case reports. In antenatal ultrasound imaging, the unique location of parallel anechoic cystic structures in the gallbladder fossa is helpful in differentiating from other closely related pathologies such as choledochal cyst, duodenal duplication cysts.

To the best of our knowledge, we did not find any resource in which HDlive Silhouette was utilized to diagnose the type of gall bladder duplication. In most cases, the prenatal or postnatal diagnosis was made by MRCP. In our patient, we used this method to trace the cystic duct to classify, the exact site of cystic duct insertion and to rule out other biliary variants which are difficult to visualize in conventional 2D ultrasound. Our findings correlated with Fetal MRI findings suggesting that good expertise in 3D ultrasound imaging and HDlive Silhouette is on par with cross-sectional imaging which has not been demonstrated in medical literature to date. Henceforth this technique not only helps in antenatal diagnosis and thus preparing for future possible outcomes but also helps in avoiding MRI which is costly, time-consuming, and technically challenging as compared to antenatal ultrasound.

The differential diagnosis includes hepatic cyst (common in anterior right lobe), GB fold (commonly transverse), Phrygian cap, and diverticulum (communicating with GB) [17, 18]. Also, an increased risk of acute and chronic cholecystitis, carcinoma, biliary cirrhosis, and torsion and postoperative complications have been reported [19].

When gallbladder duplication is detected in utero, the patient can be reassured of the benignity of the finding and advised standard obstetric care.

Conclusion

Recent advances in ultrasound imaging with 3D/4D Ultrasound and HDlive Silhouette have revolutionized fetal medicine and enabled a most sophisticated yet detailed evaluation of the fetus. It has provided excellent non-invasive modes of evaluating complex anatomy and anomalies even in early gestation. HDlive also plays an important role in strengthening the feto-maternal relationship. Duplication of the gall bladder is a rare anomaly with very few reports on antenatal diagnosis. There is no literature on the utility of 3D Ultrasound and HDlive Silhouette in an accurate anatomical diagnosis which we prove essential in tracing and classifying duplication of gall bladder with MRI correlation. This anomaly is not associated with other fetal anomalies and has favorable outcomes. However, future outcomes rest on the increased risk of common complications of the acquired disease and postoperative complications.

a : Type 1 – Primordial Gallbladders. A: Normal, B: V-shaped, C: Y-shaped, D- Triple Primordial, E: Septate A

b : Type 2 – Accessory Gallbladders. A: Ductular, B: Right trabecular, C: Left trabecular, D- Triple Ductular, E: Direct Right Trabecular



c : Type 3 – Combined Gallbladders. A: Septate B, B: Triple

Fig. 4 **a** Type 1 – Primordial Gallbladders. A: Normal, B: V-shaped, C: Y-shaped, D- Triple Primordial, E: Septate A. **b** Type 2 – Accessory Gallbladders. A: Ductular, B: Right trabecular, C: Left trabecular, D- Triple Ductular, E: Direct Right Trabecular. **c** Type 3—Combined Gallbladders. A: Septate B, B: Triple

References

1. Baba K, Satoh K, Sakamoto S, Okai T, Ishii S. Development of an ultrasonic system for three-dimensional reconstruction of the fetus. J Perinat Med. 1989;17:19–24.
2. Kuo HC, Chang FM, Wu CH, Yao BL, Liu CH. The primary application of three-dimensional ultrasonography in obstetrics. AmJ Obstet Gynecol. 1992;166:880–6.
3. Nelson TR, Pretorius DH. Three-dimensional ultrasound imaging. Ultrasound Med Biol. 1998;24:1243–70.
4. Fenster A, Downey DB. 3-D ultrasound imaging: a review. IEEE Eng Med Biol. 1996;15:41–51.
5. Goncalves L, Lee W, Espinoza J, Romero J. Three- and four-dimensional ultrasound in obstetric practice: does it help? J Ultrasound Med. 2005;24:1599–624.
6. Pooh RK. See-through fashion in prenatal diagnostic imaging. Donald School J Ultrasound Obstet Gynecol. 2015;9(2):111.
7. Cömert EH, Guven G, Seda E, Guven S, Kart C. Prenatal diagnosis of fetal gallbladder duplication associated with uncommon chromosomal anomaly (46, XX, t(X;10) (p11.2;q24.3) [20]). Clin Exp Obstet Gynecol. 2019;45:980–1. https://doi.org/10.12891/ceog4757.2019.
8. Pooh RK. First trimester scan by 3D, 3D HDlive and HDlive silhouette/flow ultrasound imaging. Donald School J Ultrasound Obstet Gynecol. 2015;9(4):361–71.
9. Udelsman R, Sugarbaker PH. Congenital duplication of gallbladder associated with an anomalous right hepatic artery. Am J Surg. 1985;149:812–5.
10. Nichols DM. Superior mesentric vein rotation: a CT sign of midgut malrotation. AJR Am J Roentgenol. 1983;141:707–8.
11. Kinoshita LL, Callen PW, Filly RA, Hill LM. Sonographic detection of gallbladder duplication: two cases discovered in utero. J Ultrasound Med. 2002;21:1417–21.
12. Sifakis S, Mantas N, Koumantakis G, Koukoura O. Prenatal diagnosis of gallbladder duplication. Ultrasound Obstet Gynecol. 2007;30:362–3.
13. Udelsman R, Sugarbaker PH. Congenital duplication of gallbladder associated with an anomalous right hepatic artery. Am J Surg. 1985;149(812–815):10.
14. Granot E, Deckelbaum RJ, Gordon R, Okon E, Sherman Y, Schiller M. Duplication of the gallbladder associated with childhood obstructive biliary disease and biliary cirrhosis. Gastroenterology. 1983;85:946–50.

15. Gigot J, Van Beers B, Goncette L, Etienne J, Collard A, et al. Laparoscopic treatment of gallbladder duplication: a plea for removal of both gallbladders. Surg Endosc. 1997;11:479–82.
16. Botsford A, McKay K, Hartery A, Hapgood C. Mrcp imaging of duplicate gallbladder: a case report and review of the literature. Surg Radiol Anat. 2015;37:425–9.
17. Boyden EA. The accessory gallbladder- an embryological and comprarative study of aberrant biliary vesicles occurring in man and the domestic mammals. Am J Anat. 1926;38:177–231.
18. Harlaftis N, Gray SW, Skandalakis JE. Multiple gallbladders. Surg Gynecol Obstet. 1977;145:928–34.
19. Benoit B, Hafner T, Kurjak A, Kupesic S, Bekavac I, Bozek T. Three-dimensional sonoembryology. J Perinatal Med. 2002;30:63–73.