

## Bilateral vertex extradural hematomas: A case report

SGS Datta M Ch

Department of Neurosurgery  
Command Hospital (Northern Command), C/o 56 APO

**Abstract :** Bilateral vertex extra dural hematomas (EDH) are a rare form of extra dural hematomas with many unique features. We report one such case of bilateral vertex extra dural hematoma. A young house wife had a fall in the bathroom and sustained head injury. She showed clinical features of progressive raised intra cranial pressure. Neuroimaging revealed bilateral vertex EDH. The larger left sided hematoma was evacuated surgically while the smaller right sided hematoma was managed non operatively, with excellent outcome. This case report presents this rare case and briefly reviews the literature. Vertex EDH has a special uniqueness as to their etiopathology, clinical presentation, diagnosis & management principles.

**Keywords:** Head injury, Vertex EDH

### INTRODUCTION

Cases of vertex EDH are rare. When these lesions occur, they frequently cause a diagnostic dilemma, both clinically and radiologically. Characteristic of vertex EDH are clinical findings indicating elevated intracranial pressure which may not contribute to the establishment of a specific diagnosis. The onset can be acute or can be significantly delayed. In general, the neurological examination results are both non-localizing and non-lateralizing.

### CASE REPORT

A 45 year old house wife presented to the Emergency Services on 25 Dec 07. She had apparently slipped and fallen the previous day in her bathroom. She had loss of consciousness for about 10 mins, followed by complete recovery. However a continuous, progressive headache persisted along with some difficulty in walking, necessitating support. General examination was unremarkable. Neurological evaluation revealed a conscious patient, drowsy but arousable and irritable with GCS of E3 M6 V4. Her right plantar reflex was extensor, and there was no other deficit. Non-contrast CT head showed a large left heterogeneous density lesion (central hypodensity and peripheral hyperdensity) in the left fronto parietal region with another smaller hyperdense lesion on the right frontal region (Fig 1). MRI

brain was done for better delineation & showed a bilateral vertex extra dural hematoma, left side larger than the right, with inferior displacement of the superior sagittal sinus, bilateral fronto parietal lobes and quashing of the left lateral ventricle (Fig 2). She underwent a left frontoparietal craniotomy (square flap) and evacuation of the larger left sided EDH on 25 Dec 07. At surgery a linear parietal bone fracture going across the midline was seen along with an underlying thick EDH (Fig 3). No tear of the superior sagittal sinus or any other bleeding vessel was noticed. She was closely monitored postoperatively as the right side EDH had not been evacuated. Post operative recovery was uneventful, and postoperative non-contrast CT head showed full evacuation of the left sided EDH with resolution of the mass effect. There was no increase in the size of the right sided EDH. At discharge a week later, she was alert, ambulant and with no neurological deficits. She has been regularly reviewed, and remains asymptomatic and has returned to her normal activities.

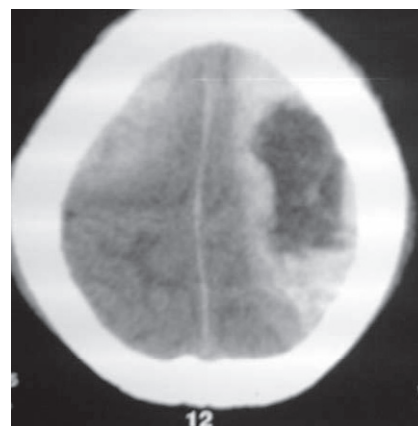


Fig 1: NCCT Head showing bilateral lesions

*Address for correspondence:*

Wg Cdr SGS Datta  
Cl Spl (Surgery) & Neurosurgeon  
CH (NC), C/o 56 APO  
Tele: 0-9906000580; email: sgs1datta@rediffmail.com

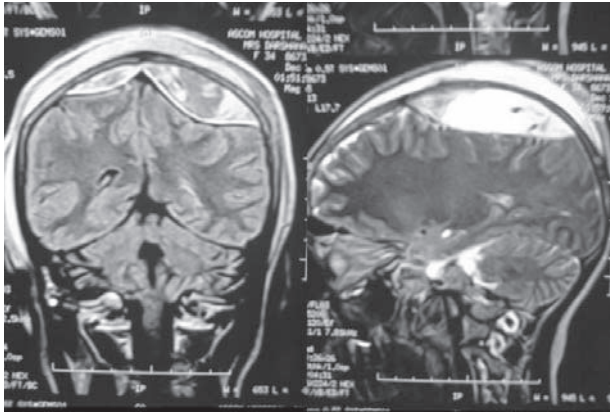


Fig 2: MRI brain Coronal & Sagittal views showing the bilateral vertex EDH with mass effect

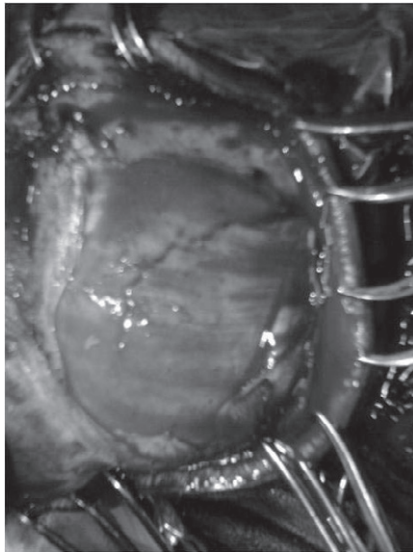


Fig 3: Operative photograph showing the coronally aligned linear parietal bone fracture going across the midline

## DISCUSSION

Epidural hematomas occurring at the vertex (VEH) represent a distinct group among all EDH's. The incidence of VEHs has been reported to be 0 to 8%, with a reported mortality rate of 18 to 50% in the pre-MRI period probably reflecting on the likelihood of having missed these lesions<sup>1</sup>. Majority of reported cases have an associated vertex fracture though the literature does include cases without a fracture at the vertex. The linear fracture line usually crosses the sagittal suture, or there is diastasis of the sagittal suture.

Vertex epidural hematomas are usually associated with a venous bleeding source, and hence the course can be more chronic and benign than with the typical arterial

epidural hematoma. The bleeding source could be veins, venous sinuses, the fracture itself or diffuse dural bleeding caused by dural stripping. In some cases, there is an obvious source in the form of a superior sagittal sinus (SSS) laceration. These patients are likely to present with rapid deterioration and have a poorer prognosis<sup>2</sup>. The sagittal sinus was intact in our patient but had been stripped away from the inner table of the skull. Obstruction of cerebral venous drainage by the expanding vertex epidural mass has been cited as a possible source of elevated intracranial pressure and focal neurologic deficit and could account for the transient motor deficits seen in our case and in others.

The clinical presentation has been frequently described as being both non-specific and non-localizing, thus giving few indications of the presence of the VEH<sup>3</sup>. This may lead to delays in treatment and even death. In contrast to convexity epidural hematomas, VEHs are not always acute in presentation. Chronic cases of VEH have been reported. The most prominent symptom is headache, which is usually severe and unrelenting. Upper motor neuron signs may also be present because of unilateral or bilateral compression of the parasagittal motor cortex as was seen in our case.

Conventional axial CT scans may be misleading. Coronal CT scans may better delineate the lesion. Separation of the sagittal sinus from the inner table is a characteristic angiographic finding in VEHs described in the pre-CT scan era. Retarded venous flow to the sinus has been frequently noted on arteriogram in cases of VEHs. MRI has been found to clearly delineate these lesions as VEHs. Whenever a strong clinical suspicion is present and axial CT scans of the vertex show either possible artefacts, questionable radiological features or a vertex fracture, MRI should be performed to search for a possible VEH<sup>1, 4, 5, 6</sup>.

Unlike standard epidural hematomas, those at the vertex do not necessarily require surgery<sup>1</sup>. VEHs may have a chronic and favourable course, with some resolving spontaneously. Consistent with having venous instead of arterial bleeding sources, it has been observed that the course of VEHs is more indolent and the prognosis more favorable than that of other epidural hematomas. The exceptions are those cases in which the superior sagittal sinus is lacerated, in which the course is much more acute and the mortality as high as 16.5 to 50%<sup>2</sup>. The majority of these hematomas receive aggressive surgical treatment. It must be recognized that

SSS tears may be exposed during surgery and may significantly complicate the surgical removal of these lesions. Strict criteria for surgical intervention have not been established. The choice of surgical versus conservative management should be based on the size of the VEH, the amount of SSS displacement, the degree of underlying mass effects and brain distortion, the overall severity of symptoms, the presence or absence of specific neurological examination findings, and worsening or improvement with conservative treatment.

### CONCLUSION

Vertex extradural hematomas form a unique subset of intracranial extra dural hematomas. There are many special features in their pathophysiology, clinical presentation, diagnosis (especially with a high probability of missing them) & important therapeutic issues. A high index of suspicion, close neurological monitoring and evacuation of the hematoma when indicated gives satisfying outcomes.

### REFERENCES

1. Miller DJ, Steinmetz M, McCutcheon IE. Vertex epidural hematoma: surgical versus conservative management: two case reports and review of the literature. *Neurosurgery* 1999; 45: 621 – 4.
2. Wylene EL, Nanda A. Vertex Epidural Hematoma with Coronal Suture Diastasis Presenting with Paraplegia. *J Trauma* 1998; 45: 413 – 5.
3. Dufour H, Métellus P, Manera L, Fuentes S, Do L, Grisoli F. Spontaneous vertex extradural hematoma: considerations about causes. Case report and review of literature. *J Neurosurg* 2001; 94: 633 – 6.
4. Harbury OL, Provenzale JM, Barboriak DP. Vertex epidural hematomas: imaging findings and diagnostic pitfalls. *Eur J Radiol* 2000; 36: 150 – 7.
5. Ramesh VG, Sivakumar S. Extradural hematoma at the vertex: A case report. *Surg Neurol* 1995; 43: 138 – 9.
6. Server A, Tolleson G, Solgaard T, Haakonsen M, Johnsen UL. Vertex epidural hematoma - neuroradiological findings and management. *Acta Radiol* 2002; 43: 483 – 5.