

Chronic spinal haematoma mimicking pseudomeningocele

P K Nayak M Ch, GC Sahoo MS*, G Das MS**, AK Mahapatra M Ch***

Departments of Neurosurgery, *Orthopedics and **Surgery
Neelachal Hospital, Bhubaneswar.

****Prof of Neurosurgery and Director
Sanjay Gandhi Postgraduate Institute, Lucknow.

A forty-five years old male presented with recurrent swelling in the lumbar region. He had a fall from a height four months back, followed by swelling in the lumbar area for which he consulted a local doctor. Blood stained fluid was aspirated twice, within one month. He was referred to our center since the swelling reappeared. There was no pain, fever or backache. On examination, the swelling was cystic, tense, fluctuant, transillumant, and measured 10cms X 6cms (Fig 1). No neurological deficit was noticed.

MRI of lumbo-sacral spine revealed a cystic swelling extending from L2 to S2 vertebral level with no definite connection to the thecal sac (Figs 2 & 3). The swelling was exposed by posterior midline approach. It was seen to be in the subcutaneous space, which was separated the para-spinal muscle. The swelling was full of pale, reddish fluid (Fig 4). The lining membrane was defined and excised totally. No definite connection to the thecal sac was noted.

Chronic spinal haematoma do occur in the extra and sub dural location along with ligamentum flavum, and have been described in literature as case report^{1,2}. Pseudomeningocele in the lumbar spine due to spinal fractures or surgical procedures are well recognized complications³. Chronic spinal haematoma in subcutaneous location mimicking pseudomeningocele has not been described. Blood trapped in space liquifies in course of time and draws more fluid into the cavity by osmolar gradient. Other theory is the secretion of fluid into the cavity by the lining membrane due to inflammation⁴. This may presents as swelling, low backache or neurological deficit if it involves any

neurovascular structue.⁵

This constitutes a rare complication of spinal trauma and need to be recognized in time, as its excision is associated with good prognosis.

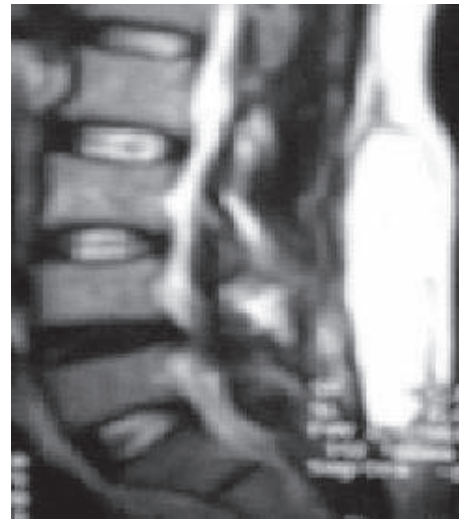

Fig 1: MRI showing haematoma

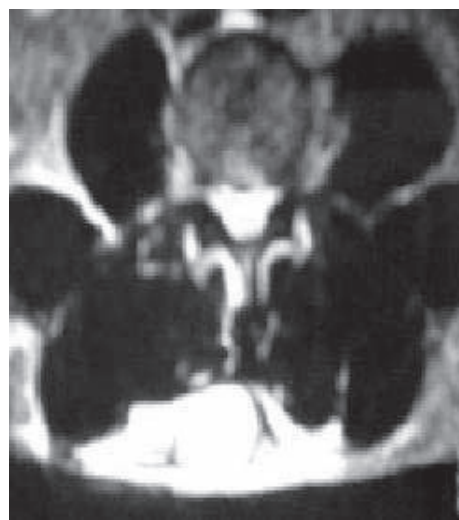

Fig 2: Axial MRI showing haematoma

Address for Correspondence:

Dr. P K Nayak
B-6/6, Chandrama appt., Kharvel Nagar,
Bhubaneswar-751001
E-mail: drmichaelpn@rediffmail.com

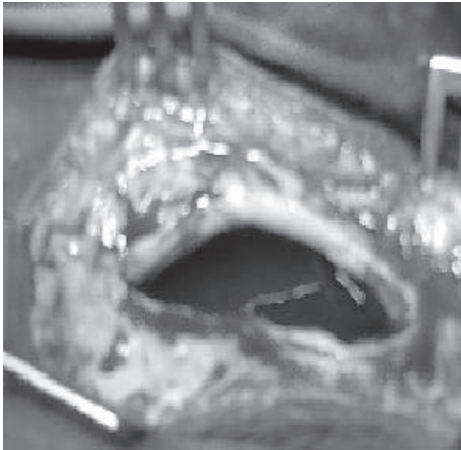


Fig 3: Intra operative appearance of the cyst

REFERENCES

1. Jimbo, H, Asamoto, S; Mitsuyama, T. Spinal Chronic Subdural Haematoma in Association with Anticoagulant Therapy: A Case Report and Literature Review. *Spine* 2006; 31: E184-E187.
2. Hirakawa K, Hanakita J, Suwa H et al. A post-traumatic ligamentum flavum progressive haematoma: a case report. *Spine* 2000; 25: 1182-4.
3. Johnson JP, Lane JM. Traumatic lumbar pseudomeningocele occurring with spina bifida occulta. *J Spinal Disord* 1998; 11: 80-3.
4. Frati A, Salvati M, Mainiero F et al. Inflammation markers and risk factors for recurrence in 35 patients with a posttraumatic chronic subdural haematoma: a prospective study. *J Neurosurg* 2004; 100: 24-32.
5. Cruz-Conde R, Berjano P, Buitron Z. Ligamentum flavum haematoma presenting as progressive root compression in the lumbar spine. *Spine* 1995; 20: 1506-9.