

Work-related unusual penetrating head trauma caused by industrial welding rod

Rakesh Kumar Singh M Ch, PN Pandey M Ch, Rohit Kumar M Ch
Department of Neurosurgery, Lok Nayak Hospital, MAMC, New Delhi 110002

Abstract: Accidental penetrating head injuries are rare but significant cause of morbidity. We report a case of a thirty five-year-old man who sustained a fatal trans-orbital penetrating injury following fall from a height. The metal rod was lodged intracranially, traversed close the brainstem, crossed the midline and stuck to the inner table of occipital bone. This case highlights the necessity for retrograde removal of penetrating rod in the direction of its line of trajectory.

Keywords: brain stem; penetrating brain injury

INTRODUCTION

Although head injuries are a common cause of accidental trauma in all age groups, penetrating head trauma is rare. Industrial workers are vulnerable to penetrating head trauma. We report a case of a 35-year-old man who sustained penetrating injury by a metal rod used for welding.

CASE REPORT

A 35 year old man was brought to the emergency room after a metallic rod penetration of the right eye due to fall from a height two hours earlier. There was no loss of consciousness. Patient was initially transferred to the regional eye hospital and subsequently to our hospital.

At the time of admission, patient was conscious, oriented to time, place and person but drowsy. General examination revealed the right orbit to be penetrated by a metallic rod, the point of entry was just superomedial to the eyeball (Fig 1). There was no bruit or pulsatile proptosis. Ocular examination revealed normal visual acuity with slight restriction of medial gaze of right eye. Detailed neurological examination revealed a normal mental status. The patient had no sensory motor deficit and planter responses were flexor bilaterally.

A computed tomography (CT) scan demonstrated the transorbital transcranial trajectory of the metallic rod crossing the midline upto left occipital bone inner table (Figs 2 & 3). Length of intracranial part of metallic rod

was 16 cm. There was no significant intracranial hematoma along the tract.

Bone windows demonstrated the rod to have passed through the superomedial wall of right orbit, about five cm behind anterior border of anterior cranial fossa (Figs 4 & 5). Rod traversed very close to midbrain, crossed the midline and reached the inner table of left occipital bone. There was no injury to right globe and nasolacrimal duct.

A three centimeter curved incision centered over entry point of rod given for right small superomedial orbitotomy. Intracranial part of metal rod was removed under direct visualization from the entry point without marked resistance. No obvious hemorrhage was noted intraoperatively. The ethmoid bone and shredded galea were repaired. Postoperative brain CT revealed a small residual hematoma along the penetrating path and residual coating material of welding rod at the entry point over the floor of right anterior cranial fossa. Patient was electively ventilated overnight. Postoperative course was uncomplicated. Patient was weaned off the ventilator on first day. He was noted to be hemodynamically stable, awake, and alert with no visual, speech or language impairment. Partial ptosis of right eye and mild hemiparesis was noted on left side on third day, which recovered gradually. Repeat brain CT was done on fifth post-operative day did not reveal any new finding. Mild wound infection also occurred which was treated by antibiotics. Patient was discharged to home on eleventh post-operative day with well healed wounds and no evidence of CSF fistula.

DISCUSSION

Penetrating head injuries have higher mortality and

Address for correspondence:

Dr Rakesh Kumar Singh
House No. 337, Jagriti Enclave, Anand Vihar, New Delhi-110092
Phone: 09968345770 E- mail: singhdrakesh@gmail.com

morbidity than blunt trauma even in civilian set up. Case fatality rates are higher for penetrating than closed injuries for all GCS, gender, age, and cause of injury categories¹. Most common sites for entry wound are the temporal area and orbit where the bone is thin².

The orbit is a bony pyramid shaped structure with thin walls that are vulnerable to injury. Foreign bodies typically penetrate the orbit from the medial canthus and usually pass through the optic canal and superior orbital fissure to lodge in the ipsilateral or contralateral side of the cranium³. The most frequent path of penetration is via the roof of the orbit due to the fragile structure of the superior orbital plate of the frontal bone, often resulting in frontal lobe contusion. The second most frequent path of penetration is the superior orbital fissure, by which foreign bodies occasionally reach the brain stem through the cavernous sinus and cause serious damage⁴. Brain damage in these cases can include cerebrospinal fluid fistulas, pneumocephalus, orbital cellulites, carotid-cavernous sinus fistula, central nervous system (CNS) infections, and intracranial hemorrhage. The appropriate management in the field is to leave the transorbital object in situ and transport the patient to the trauma center carefully. Management of patients with transorbital brain injuries and foreign bodies in situ should follow basic surgical principles, including removal of the object under direct vision in order to reduce further brain tissue damage by the foreign bodies catching on bone fragments. Following removal of the foreign body, thorough debridement with removal of all involved skull bone and foreign materials, hematoma evacuation followed by careful hemostasis along the trajectory, and meticulous dural closure to reduce the possibility of cerebrospinal fluid fistula are mandatory. For patients with deep-seated bullet in the brain, it is not necessary to remove the bullet because of the potential for further brain damage and because of the low incidence of CNS infection. However, metal bars and other missiles with extracranial components must be removed, and prophylactic antibiotics should be considered⁵.

CT is typically the first-line radiologic examination in the emergency room for head-injured patients. However, scanning artifacts from metal objects can sometimes limit visualization of brain tissue and brain damage along the trajectory of the penetrating object. In patients with transorbital brain injuries, the path of penetration often passes near the cavernous sinus and basal cisterns. Thus, corresponding brain contusion

hemorrhages with great mass effect may be obscured in the initial CT scan. Notably, in case 2, a large hematoma with no change in intracranial pressure was detected on postoperative CT (Figure 2). We therefore recommend an immediate follow-up CT scan postoperatively in order to look for missed contusion brain damage and possible hemorrhage. An alternative approach is endoscopic brain surgery via the transorbital route, which may offer direct visualization of unidentified brain damage along the penetrating path and provide direct hemostasis.

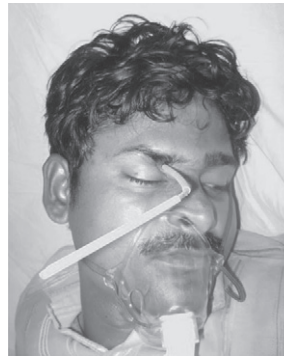

Fig 1: Patient with penetrating rod

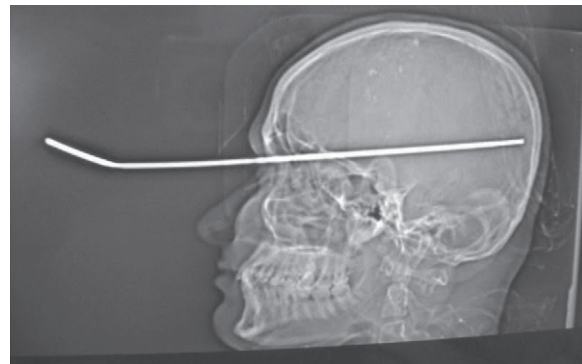


Fig 2: Topogram of pre operative CT brain showing extent of penetration of rod

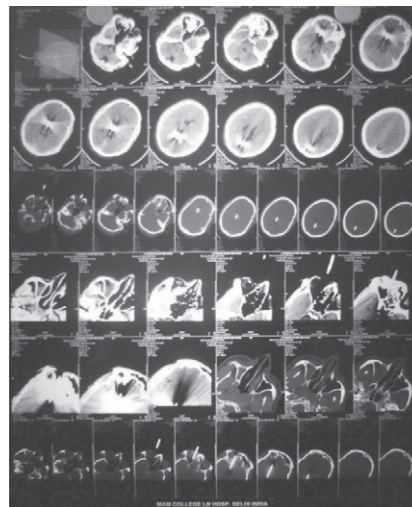


Fig 3: Preoperative CT Brain with Orbit

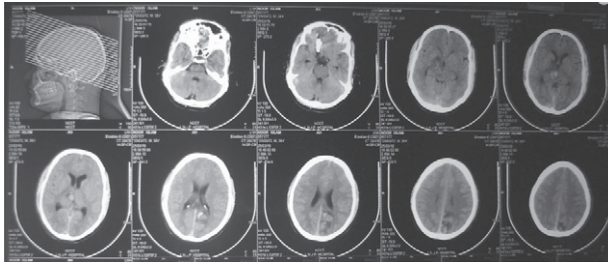


Fig 4: Post operative CT scan brain

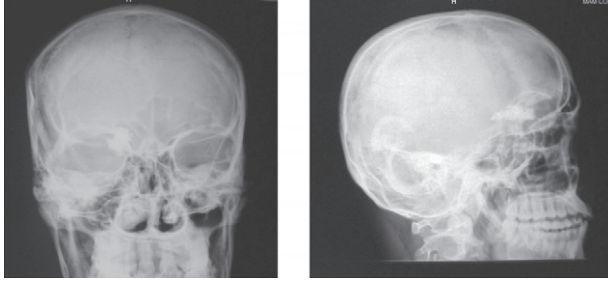


Fig 5: Post operative x-ray skull (AP and lateral view) showing residual coated material of welding rod over superomedial wall of right orbit

Finally, angiography is advocated by some authors for possible cerebral vascular injuries in patients following penetrating head injuries⁶. In 1 study, Kieck and Villiers⁷ reported 11 vascular lesions identified with cerebral angiography in 18 transorbital head-injured patients (61%). However, due to prolonged radiologic intervention procedures and inadequate CT scan resolution, patients with extended transorbital brain injuries may deteriorate rapidly⁸. Hung et al proposed that prompt craniotomy for decompression and direct hemostasis for vascular injuries is a better option than cerebral angiography in patients with extended transorbital brain injuries⁸.

In conclusion, accidental penetrating head injuries can be an important cause of disability among the workers especially in the developing contexts working under situations with improper safety and with life-threatening instruments. Transorbital brain injury caused by a metal bar is a rare but fatal event. Emergent surgical intervention and early follow-up CT is necessary if there is to be any chance of saving the life of the patient.

REFERENCES

1. Peek-Asa C, McArthur D, Hovda D, Kraus J. Early predictors of mortality in penetrating compared with closed brain injury. *Brain Inj* 2001; 15:801-10.
2. Faraji M, Ashrafzadeh, Farah. Penetrating head injuries in children. *Neurosurgery Quarterly* 2005; 15:160-3.
3. Davis GA, Holmes AD, Kulg GL. Delayed presentation of transorbital intracranial pen. *J Clin Neuroscience* 2000; 7:542-60.
4. Matsumoto S, Hasuo K, Mizushima A, et al. Intracranial penetrating injuries via the optic canal. *Am J Neuroradiol* 1998; 19:1163-5.
5. Harsh GR. Penetrating wounds of the head. In: Wilkins RH, Rengachary SS, eds. *Neurosurgery*. New York: McGraw-Hill, 1985:1670-8.
6. O'Neill OR, Gilliland G, Delashaw JB, Purtzer TJ. Transorbital penetrating head injury with a hunting arrow: case report. *Surg Neurol* 1994; 42:494-7.
7. Kieck CF, Villiers JC. Vascular lesions due to transcranial stab wounds. *J Neurosurg* 1984; 60:42-6.
8. Hung-Lin Lin, Han-Chung Lee, Der-Yang Cho. Management of Transorbital Brain Injury. *Chin Med Assoc* 2007; 70:36-8.