

# Synopsis of Traumatic Lesions of the Cranio-cervical Junction

Deepak Kumar Gupta MCh, SS Kale MCh, AK Mahapatra MCh

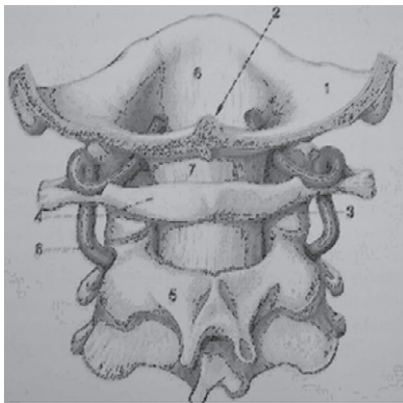
Department of Neurosurgery, All India Institute of Medical Sciences, New Delhi, India.

**Abstract:** The craniovertebral junction is subject to dislocation, subluxation and instability. Atlanto axial dislocation resulting from trauma is usually fatal owing to transection of the spinomedullary junction. Occipital condyle fracture (OCF) is a rarely encountered pathology not easily diagnosed by routine clinical and radiological evaluation. In upper cervical trauma, axis is involved in 25% of cases and atlas in 3-13% of cases. Serious injury to upper cervical spine resulting in spinal column structural damage or injury to the spinal cord with its sequelae may be devastating with respect to long term disability. The study of cervical spine injury has evolved dramatically during the past several decades. A greater understanding of the anatomic and mechanical considerations has enabled a more accurate classification of these injuries. Refinements in the medical and surgical treatment have significantly improved both short term and long term outcome in craniovertebral junction trauma patients.

**Keywords:** craniovertebral junction, trauma, occipital condyle, atlas, and axis

## Introduction

The craniovertebral region includes the funnel-shaped occipital bones forming the foramen magnum as well as the atlas and axis vertebrae and the encompassed neural structures of the cerebellum, medulla, cervicomedullary junction, and upper cervical cord (Fig 1).



**FIGURE 1.** Schematic picture showing CVJ anatomy: 1 (base of occiput bone), 2 (foramen magnum), 3 (spine of atlas), 4 (arch of atlas), 5 (axis), 6 (clivus), 7 (dural sheath) and 8 (vertebral artery).

The craniovertebral ligaments are vulnerable to high-speed trauma. In a post mortem study, Saturnus et al found rupture in 11 alar ligament in 30 craniocerebral traumas. Ruptures were seen also after less severe injuries<sup>1</sup>. In a dissection study, 20 out of 21 traffic fatalities without craniovertebral dislocation showed alar ligament injuries<sup>2</sup>.

*Address for correspondence:* Dr. SS Kale Associate Professor of Neurosurgery, Department of Neurosurgery, All India Institute of Medical Sciences, New Delhi-110029, INDIA, Tel No:011-26594888 Email: skale67@yahoo.com, Fax:011-26589650

In a computed tomography (CT) study of 43 traffic victims with clinically suspected rotational instability of the neck, 26 cases showed increased rotation between the occiput and the atlas as well as between the atlas and the axis<sup>3</sup> suggestive of alar ligament insufficiency. Atlantooccipital dislocation appears to have its highest incidence in the pediatric age group attributable to relatively high incidence of automobile pedestrian accidents and inherent instability of pediatric CVJ (the plane of articulation between the cranium and the atlas is almost horizontal, the occipital condyles of infants and children are not deeply seated into the fossa of the superior facet of the atlas).<sup>4,5</sup>

## Biomechanics of Craniovertebral Junction

The craniocervical or the craniovertebral junction (CVJ) is structurally composed of many bony and ligamentous structures; yet functionally, it is a stable, interlocking unit that acts as a transition between the skull and the spine. Embryologically it forms from multiple parts of the proatlax, the terminus of the notochord, and the first and second spinal sclerotomes. It allows for extension, flexion, and lateral rotation of the head. The geometry of the articular surfaces provides for mobility, the atlantoaxial facet joints (lateral masses) are horizontal and lack an intervertebral disc. Stability is provided for by the muscular and ligamentous attachments that span the skull and the cervical spine<sup>6</sup>. This versatile function necessitates numerous synovial joints; and this, together with the complex mobility of the region, makes the occipitoatlantoaxial complex vulnerable to traumatic injury.

## Occipitoatlantoaxial complex motion

Eighty-five to ninety percent of all axial rotation in the occipitoatlantoaxial complex comes from the atlantoaxial

complex. There is little lateral bending across the CVJ. The skull rotates axially an average 72.2 degrees with respect to the first thoracic vertebrae and the atlantoaxial complex accounted for 56% of this rotation. The alar ligaments contribute to limit this rotation. These ligaments are supported in their role by the tectorial membrane, the accessory atlantoaxial ligaments, and the joint capsule. The nuchal ligament, tectorial membrane, cruciform ligaments, and transverse ligament limit flexion.<sup>7</sup>

**Table 1 : Classification of CVJ Injuries**

Type of injury	Subtypes	Management
Occipital condylar fracture	Type I: Condylar fracture. Min. or no displacement of fragment Type II: Condylar fracture with extension to basilar skull bones. Type III: Avulsion fracture of condyle with displacement towards dens.	Type I and II fractures are stable. Type III: Urgent ext. immobilization. Additional treatment as per associated cervical fractures/instability.
Atlas fracture (Jefferson's fracture)	1. Intact transverse ligament 2. Transverseligament incompetent (>3mm atlanto dental distance, >6.9 mm lateral translation of fracture segments.	Intact trasverse ligament: Ext. immobilization Ruptured trans. Ligament: Operative stabilization required.
Odontoid fractures	Type I: Fracture through odontoid process Type II: Fracture through base of odontoid Type III: Fracture through body of odontoid	Surgery: >6mm ventral subluxation/dorssubluxation. Reduction of fracture and restoration of alignment with traction and flexion (for dorsal subluxation) or extension ( for ventral subluxation) under fluoroscopy.
Hangmans fracture (C2pars interarticularis fracture)	Type I: <2mm displaced disc space below intact Type II: C2-C3 disc disruption and displacement of C2 body Type III: C2-C3 locked facet with type II features	Type I : Rigid cervical collar for 12 weeks. Type II : Halo vest with neck extension for 3 months. Type III: Operative reduction and internal fixation with postop halo vest for 3 months.
Atlanto axial dislocaton	Type I : ventral dislocation Type II: longitudinal dislocation of occiput on the atlas Type III : dorsal dislocation	Ligament disruption implies instability and warrants immediate fixation (controlled posterior reduction with posterior fusion and stabilization)

## Craniovertebral Junction Injuries

Injury to the CVJ may be manifested by fractures or ligamentous injury related to the occiput, atlas, or axis. (Table I) Radiographic criteria exist for definition of these injuries and for assessment of clinical stability.

### 1. Occipital condylar fractures

These can be divided into 3 types. Type I injuries consist

of a fracture of the occipital condyle with minimal or no displacement of fragments into the foramen magnum. This type of fracture is thought to result from axial loading. Type II condylar fractures occur as extensions of basilar skull fractures resulting from direct blows to the skull. Type III fractures are avulsion fractures of the condyle manifested by inferomedial displacement of fracture fragments towards the dens (traction by alar ligaments). This type of fracture represents an avulsion of the alar ligament from the occipital condyle and is potentially unstable. The first two types of occipital condyle fractures are considered stable because the alar and tectorial membranes are intact<sup>8</sup>.

OCF is an uncommon injury requiring CT imaging for diagnosis. MR imaging is recommended to assess the integrity of the craniocervical ligaments. It is possible by use of high-resolution MRI to assess ligaments and membranes in the upper cervical spine, and classify structural changes in grades of severity. Patients sustaining high-energy blunt craniocervical trauma, particularly in the setting of loss of consciousness, impaired consciousness, occipitocervical pain or motion impairment, and lower cranial nerve deficits should undergo CT imaging of the craniocervical junction. Untreated patients with OCF often develop lower cranial nerve deficits that usually recover or improve with external immobilization. Identification of Type III OCF should prompt external immobilization. Additional treatment may be dictated by the presence of associated cervical fractures or instability. Although Type III occipital condyle fractures are considered by many authors to be unstable, not all patients, treated or not, developed neurological deficits. CT imaging with three dimensional reconstruction for more precise measurement of the magnitude of fracture displacement and MR imaging for differentiation of partial and complete ligamentous injuries may be useful in identifying subgroups of patients who do not require treatment or conversely require more rigid halo immobilization, rather than collar immobilization. Because OCF injuries remain relatively infrequent, cooperative retrospective collection of plain radiograph, CT and MR imaging data in-patients with OCF is recommended.

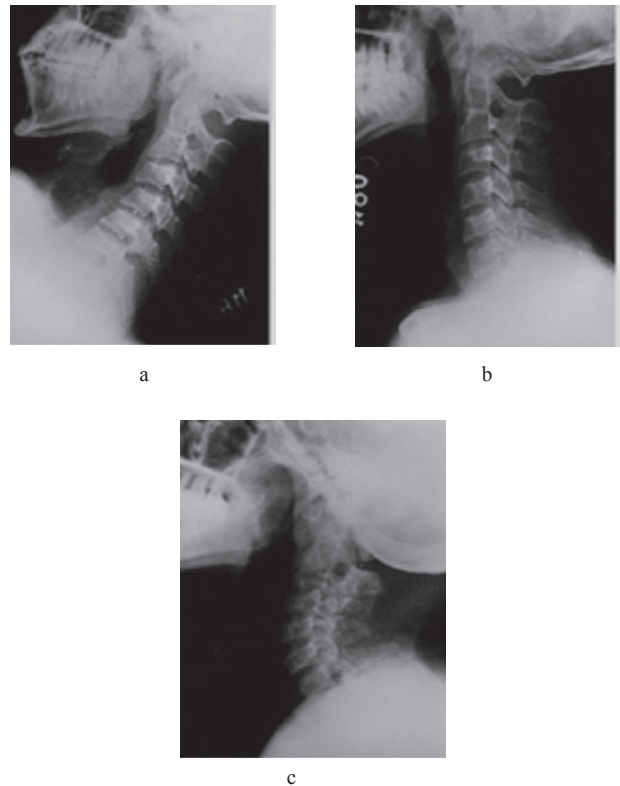
### 2. Atlanto-occipital injuries

Normal relationships between the occiput and the atlas are defined by the Powers ratio, by the basion-axial interval, and by measurement of the translational movement of the occiput on the atlas<sup>9-11</sup>. Both Treynalis and Menezes and Piper<sup>4,12</sup> have classified atlanto-occipital dislocations (AOD) based on the relative position of the occiput ( Figs 2,3). Ventral dislocation of the occiput is the most common type

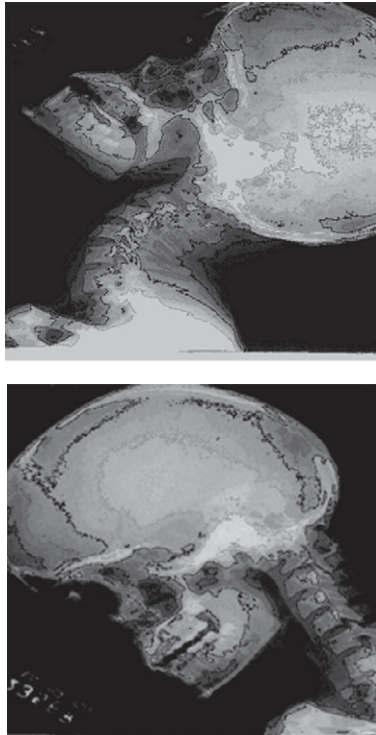
of dislocation and is termed Type I. Type II dislocations are the result of longitudinal dislocation of the occiput on the atlas. Type III injuries are characterized by dorsal dislocation of the occiput on the atlas. Radiographic findings associated with AOD are retropharyngeal hematoma, "bare" occipital condyles, and the presence of a prepontine epidural or subarachnoid hematoma on CT<sup>4,13</sup>. M.R imaging accurately depicts the anatomical integrity of the transverse ligament. After transverse ligament failure, the remaining ligaments of the craniovertebral junction are inadequate to maintain stability. The presence of ligament disruption should be considered as a criterion for early fusion.<sup>14</sup>

These injuries are rare, associated with high fatality and usually occur in the setting of distraction with the neck hyperflexed and may be associated with associated atlantoaxial instability. Rarely some patients survive the initial injury and of these who have preserved neurological function below the level of the injury should be immediately immobilized (halo vest) and brought to the operating room for immediate fixation (controlled posterior reduction across the occipital-atlantal-axial segment followed by posterior fusion and stabilization (Fig 4). Traction is not usually advocated for these patients.<sup>4</sup> Patients with complete injuries or with concomitant severe head injuries should

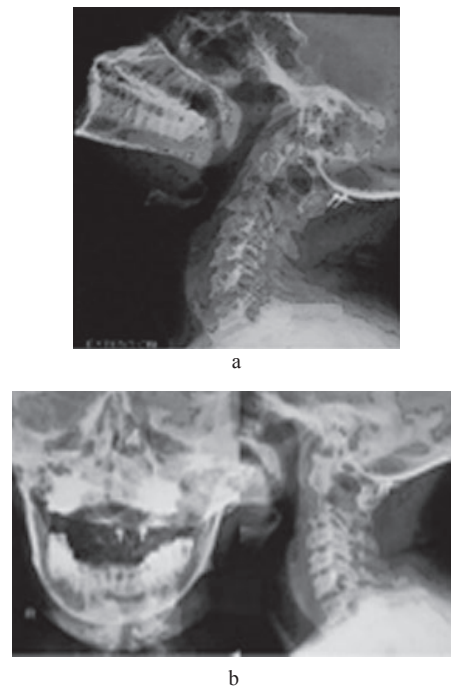be immediately immobilized with operative fixation performed on an elective basis.

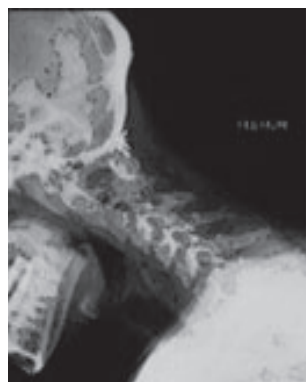

**FIGURE 3a,b, c.** Xray CVJ laterals view in flexion, neutral and extension (irreducible AAD)

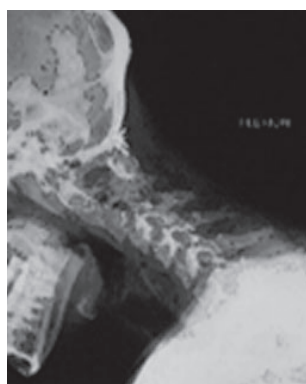


**FIGURE 2a,b.** X-ray CVJ lateral view Fig 2a in flexion and Fig 2b in extension (reducible AAD)





c



d

**FIGURE 4a,b, c, d.** Xray CVJ: 4a,b (AP and lat. View in neutral), Fig 4c and Fig 4d showing lateral view in flexion and extension of a case of AAD showing good post operative fusion

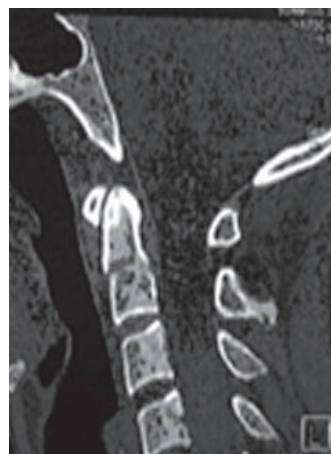### 3. Fractures of the Atlas

These are commonly referred to as Jefferson fractures in reference to Geoffrey Jefferson<sup>15</sup> who reviewed 46 cases of C1 burst fractures in 1920. These result from an axial load translated to the C1 via the wedge-shaped occipital condyles. These fractures are often detected with an open-mouth odontoid radiograph, which demonstrates spreading of the lateral masses of C1 beyond the lateral borders of the C2 lateral masses. A critical determination in the treatment of patients with Jefferson fractures involves the integrity of the transverse ligament of the atlas. Spence<sup>16</sup>, in a cadaver study, found that the transverse ligament was likely intact if lateral mass spread (total of both sides) was less than 5.7 mm and typically failed if the degree of spread totaled 6.9 mm or more. Another way to look for failure of transverse ligament is fine-cut axial CT or MRI<sup>16, 17</sup>. The use of MRI in evaluating transverse ligament integrity has revealed that the ligament may be incompetent, despite lateral translation of less than 6.9 mm<sup>18</sup>. Others have noted that an abnormal (greater than 3 mm) atlantodental interval (ADI) implies incompetence of the transverse ligament<sup>4, 18</sup>.

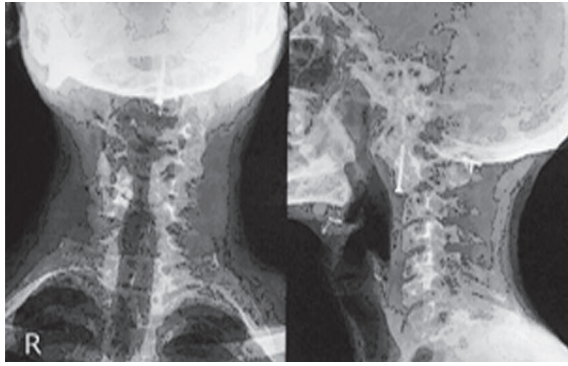
A study by Dickman et al<sup>17</sup>, which evaluated the use of MRI in the assessment of transverse ligament competence, revealed that an abnormal ADI reliably predicted failure of the transverse ligament in the absence of a C1 ring fracture. In the case of a fracture through the transverse tubercle, 26 % of patients with incompetent transverse ligaments had a normal ADI. Therefore, it appears prudent to study the CVJ with MRI in patients in whom stability cannot be established with flexion and extension radiographs. Failure of the transverse ligament implies instability, and in the absence of a fracture through the transverse tubercle, the need for operative stabilization<sup>17, 19</sup>. Atlas fractures without evidence of transverse ligament disruption is managed by external immobilization.

### 4. Fractures of the Odontoid

Anderson and D'Alonzo<sup>8</sup> have classified these according to the site of the fracture. Rare type I fractures occur obliquely through the odontoid process, type II fractures occur through the base of the odontoid (Fig 4), and type III fractures occur through the body of the axis. Depending upon the degree of subluxation of the cranial fragment and the status of the transverse ligament, there are a number of different management options for patients with odontoid fractures. Dorsal subluxations and ventral subluxations of more than 6 mm have been associated with high rates of nonunion. In these cases, surgery is often recommended. Reduction of the odontoid fragment and restoration of normal alignment are often achieved through the use of gentle traction and flexion (with dorsal subluxation) or extension (ventral subluxation) under fluoroscopic guidance. Once reduced, rigid external immobilization or internal fixation is used to secure the alignment (Fig5, 6). A complete radiographic workup, including MRI is advised before manipulation of odontoid fractures to define associated ligamentous injury<sup>17, 20</sup>.



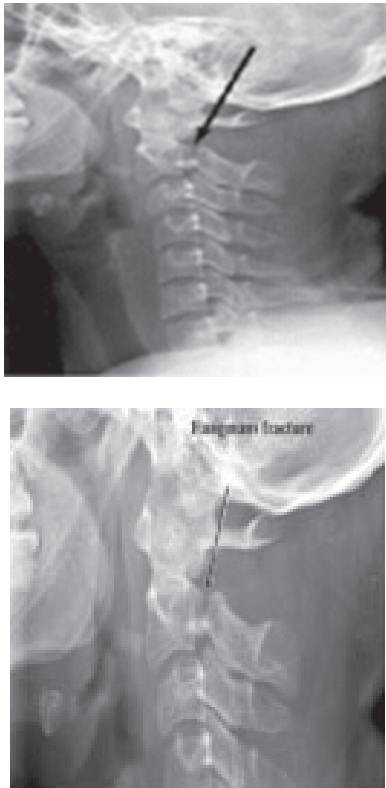
**FIGURE 5.** CT CVJ showing type II odontoid fracture



**FIGURE 6a,b.** Post op Xray CVJ AP view and lateral view of a case of axis fracture with AAD with condylar fracture showing transodontoid screw in situ with occipito-cervical fusion

### 5. Hangman's Fractures

These are fractures of the pars interarticularis of the C2, so called because of their similarity to fractures suffered as a result of judicial hanging<sup>21</sup>. Effendi et al<sup>22</sup> have classified these fractures into three types. Traumatic spondylolisthesis of C2 represents 4-7% of all cervical fractures and dislocations. The injury pattern is a bilateral pedicle fracture of C2 along with distraction of C2 from C3 (Fig 7-9). Today the most common cause of this type of injury now is motor

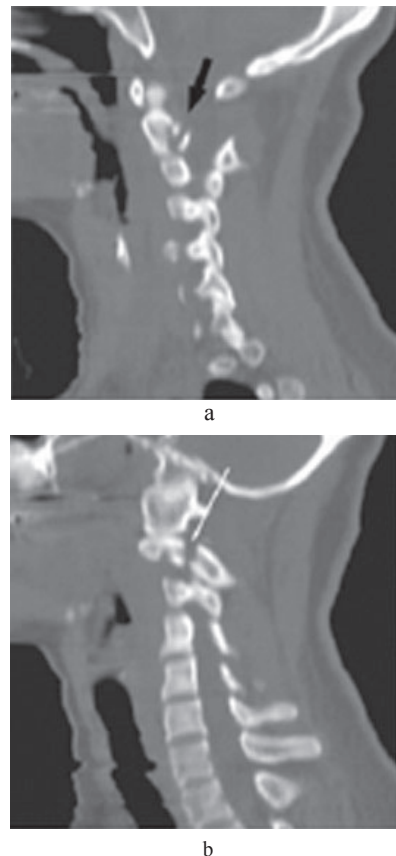


**FIGURE 7a, b.** Minimally displaced fractures of pedicles of C2, as well as some subluxation of C2 on C3. There is also an increased distance between posterior arch of C1 and spinous process of C2

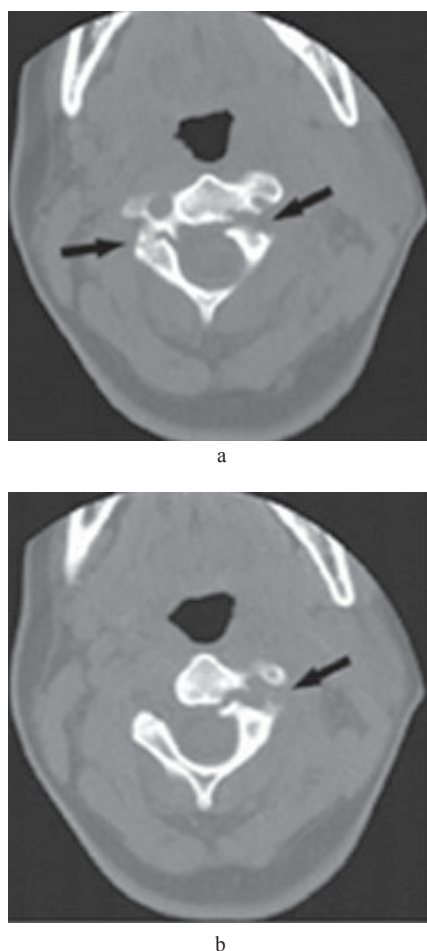
vehicle accident with hyperextension of the head and neck, or forced hyperflexion with compression in falls. The mechanism of action includes the occiput being forced down against the posterior arch of the atlas, which in turn is forced against the pedicles of C2.

The differential diagnosis of Hangman's fracture includes pseudosubluxation, which has to be considered in young children. However, this entity involves multiple upper cervical levels without any associated soft tissue swelling.

Typical clinical presentation of a patient with Hangman's fracture is upper cervical pain after a motor vehicle accident. Neurological symptoms are very uncommon on initial presentation. This is partly due to the fact that the cervical canal is wide at this point and is further decompressed by the fracture. In about 25% of the cases patients eventually develop neurological deficits mainly because of the vertebral artery injury. It is also very important to study the whole cervical spine as well as upper thoracic because there is a 33% chance of a concomitant fracture at another site, especially C1.



**FIGURE 8a,b.** CT showing lateral images demonstrating fracture of the left (Fig. 8a) and right (Fig. 8b) pedicles with mild subluxation of C2 over C3



**FIGURE 9a,b.** The axial images through the cervical spine reveal fracture of the bilateral pedicles of C2 (Fig. 9a). There is an extension of the fracture line to the posterior margin of the left foramen transversarium (Fig. 9b).

Type I fractures are minimally displaced (less than 2 mm) and angulated, and the disc space below the fracture is normal. Because ligamentous injury is minimal these fractures are considered to be stable and usually heal within 12 weeks after the neck is immobilized with a rigid cervical collar. Type II fractures are characterized by disruption of the C2-C3 disc and displacement of the body of the axis. The body of the axis (dens) may be displaced and/or angulated ventrally or dorsally. Treatment consists of a halo ring with slight extension of the neck, which might be necessary for 3 to 6 weeks to maintain anatomic reduction. The patient should be placed in a halo vest for the rest of the 3-month period. Type IIA fracture is a variant of Type II that shows severe angulation between C2 and C3 with minimal translation. Treatment recommendation is placement of a halo vest with slight compression to achieve anatomical reduction. Once reduction is obtained the vest can be continued for the rest of the 12-week period.

Type III fractures is rare. In addition to displacement and

## CONCLUSIONS

All trauma victims, particularly those with the head injuries, must be suspected of having craniocervical junction injuries and care needs to be given to prevent secondary injury to the spinal cord during patient transportation. Injuries, which are primary ligamentous, such as atlanto-occipital dislocation, frequently fail to heal with conservative therapy, and require posterior fusion as soon as medically feasible. Patients surviving atlanto occipital dislocation for the first 48 hrs may have a good outcome. Upto one quarter may survive neurologically intact, and another 25% are left with only minor deficits. Thus this condition must be kept in mind while examining the patient of acute head injury or cervical spine injuries as prognosis worsens significantly with its attendant high morbidity if CVJ injuries are overlooked.

## REFERENCES

1. Saternus KS, Thrun C. Traumatology of the alar ligaments. *Zur Traumatologie der Ligamenta alaria. Aktuelle Traumatol* 1987; 17:214-218.
2. Adams VI. Neck injuries: III. Ligamentous injuries of the craniocervical articulation without occipitoatlantal or atlanto axial facet dislocation. A pathologic study of 21 traffic accidents. *J Forensic Sci* 1993; 38:1097-1104.
3. Dvorak J, Hayek J, Ze4hnder R. CT- functional diagnostics of the rotatory instability of the upper cervical spine. Part 2. An evaluation on healthy adults and patients with suspected instability. *Spine* 1987; 12(8): 726-31.
4. Traynelis VC, Marano GD, Dunker RO et al. Traumatic atlanto occipital dislocation: case report. *J Neurosurg* 1986; 65:863-870.
5. Englander O. Non-traumatic occipito-atlanto-axial dislocation: A contribution to the radiology of the atlas. *Br J Radiol* 1942; 15:341-345.
6. Goel VK, Clark CR, Taleresk, et al. Movement-rotation relationship of the ligamentous occipito atlanto axial complex. *J Biomech* 1988; 21: 678-680.
7. Dvork J, Panjabi MM. Functional anatomy of the alar ligaments. *Spine* 1987; 12: 183-189.
8. Anderson PA, Montesano PX. Morphology and treatment of occipital condyle fractures. *Spine* 1988; 13:731-736.
9. Harris JH, Carson GC, Wagner LK. Radiological diagnosis of traumatic occipito cervical dissociation: 1. Normal occipitovertebral relationships on lateral radiographs of supine subjects. *Am J Roentegenol* 1994; 162: 881-886.
10. Powers B, Miller MD, Kramer RS et al. traumatic anterior atlantooccipital dislocation. *Neurosurgery* 1979; 4: 12-17.
11. Wiesel SW, Rothman RH. Occipitoatlantal hypermobility.

- Spine* 1979; 4: 187-191.
12. Menezes AH, Piper JG. Anatomy and radiographic pathology of injury to the occipitoatlantal complex. In Rea GL, Miller CA (eds). *Spine Trauma: Current evaluation and management. American Association of Neurological Surgeons, Park Ridge, II, 1993*
  13. Przbyski GJ, Clyde BL, Fitz CR. Craniovertebral junction subarachnoid hemorrhage associated with atlanto occipital dislocation. *Spine* 1996; 21:1761-1768.
  14. Dickman CA, Mamourian A, Sonntag VKH et al: Magnetic resonance imaging of the transverse atlantal ligament for the evaluation of atlantoaxial instability. *J Neurosurg* 1991; 75:221-227.
  15. Jefferson G. Fracture of the atlas vertebra: report of four cases and a review those previously recorded. *Br J Surg* 1920; 7:407-422.
  16. Spence KF Jr, Decker S, Sell KW. Bursting atlantal fracture associated with rupture of of the transverse ligament. *J Bone Joint Surg Am* 1970; 52A: 543-549.
  17. Dickman CA, Crawford NR, Brantley AGU, Sonntag VKH. Injuries involving the transverse atlantal ligament: classification and treatment guidelines bases upon experience with 39 injuries. *Neurosurgery* 1996; 38:44-50.
  18. Penning L. Normal movements of the cervical spine. *Am J Roentgenol* 1978; 130:317-326.
  19. Sonntag VKH, Dickman CA. Treatment of upper cervical spine injuries. In Rea GL, Miller CA (Eds): *Spinal Trauma: Current evaluation and management. American Association of Neurological surgeons. Park, Ridge, II, 1993.*
  20. Prezybylaski GJ, Welch WC. Longitudinal atlantoaxial dislocation with type III odontoid fracture: case report and review of the literature. *J Neurosurg* 1996; 84: 666-670.
  21. Schneider RC, Livingston KE, Cave AJE, et al. Hangman's fracture of the cervical spine. *J Neurosurg* 1965; 22:141-154.
  22. Effendi B, Roy D, Cornish B et al. Fractures of the ring of the axis. : A classification based on the analysis of 128 cases. *J Bone Joint Surg Br* 1981; 63B: 319-327.
  23. Hadley MN, Dickman CA, Borwner CM et al. Acute axis fracture: a review of 229 cases. *J Neurosurg* 1989; 714:642-647.
  24. Papadopoulos SM. Biomechanics of occipito atlanto axial trauma. In Rea GL, Miller CA (Eds): *Spinal Trauma: Current evaluation and management. American Association of Neurological surgeons. Park, Ridge, II, 1993.*
  25. RPS Chhabra. Craniovertebral junction anomalies. MCh Research paper submitted in All India Insitute of medical Sciences, India. 2001. (Personal communication to author)
  26. Menezes AH. Craniovertebral junction anomalies: diagnosis and management. *Semin pediatr Neurol.* 1997 Sep.4(3): 209-23.