

## Post-traumatic Superior Sagittal Sinus Thrombosis

JD Mukherji D M, KK Sen\* M D, Prakash Singh # M Ch, K K Singh D M.

Departments of Neurology, Neurosurgery # and Radiodiagnosis\*

Army Hospital (Research & Referral), New Delhi: 110010, India

**Abstract:** Cerebral sinus venous thrombosis (CVST) is a rare complication following head injury. The diagnosis may remain elusive and consequently the outcome grave unless high index of suspicion coupled with magnetic resonance imaging (MRI) and magnetic resonance venography (MRV) is resorted to at an early stage. We report two cases CVST following head injury.

**Keywords:** cerebral venous sinus thrombosis, head injury

### Introduction

Cerebral venous sinus thrombosis is an uncommon clinical entity with variable clinical presentation. The diagnosis can be overlooked especially in the setting of cerebral trauma, which can lead to complications like venous congestion, persistently raised intra cranial pressure (ICT) and cerebral infarction. Clinical suspicion, neuroimaging with CT scan (Delta sign), MRI and MRV along with evaluation of procoagulant factors like homocysteine levels, deficiency of protein C and S usually lead to correct diagnosis. The authors describe two cases of head injury, which were complicated with CVST.

### CASE REPORT

#### Case one

A 24-year-old man was admitted with head injury due to a road traffic accident with GCS 10/15, anisocoria and right hemiparesis. CT scan of the brain showed left basal ganglia hematoma. He was febrile at the time of admission, and remained so for the next three weeks. Detailed clinical exam, hematological workup, biochemical analysis, chest skiagram, sonography, body fluid cultures including CSF, bone marrow exam and various serological markers yielded no positive results. He was treated with a combination of broad spectrum antibiotics for fever for three weeks without any significant remission. Later MRI and MRV revealed superior sagittal sinus thrombosis and left lentiform nuclear and left insular hemorrhagic venous infarct (Figs 1 & 2). Procoagulant work up showed elevated serum homocysteine levels (32  $\mu\text{mol/L}$ ). He responded promptly to addition of low molecular weight heparin and folic acid with complete remission of fever and improvement in GCS

Address for correspondence: Lieut Col J D Mukherji MD, DM  
Department of Neurology, Army Hospital (R & R), Delhi Cantt 110010.  
New Delhi, E-mail: jdmukherji@hotmail.com

from 10/15 to 12/15. On discharge he had a residual right hemiparesis and was independent for activities of daily living (ADL) with a modified Barthel ADL score of 16.

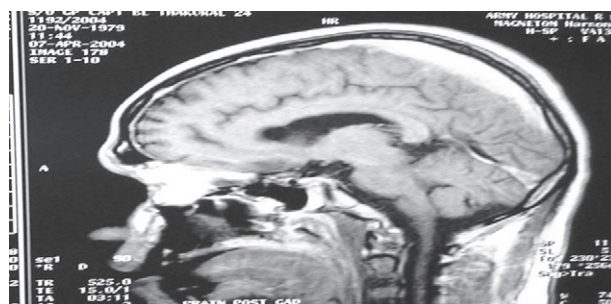


FIGURE 1. MRI showing hyperintensity of superior sagittal sinus

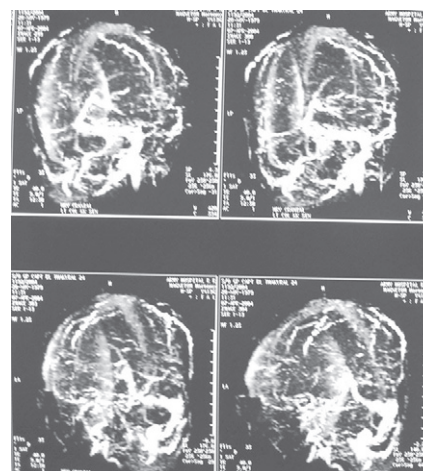
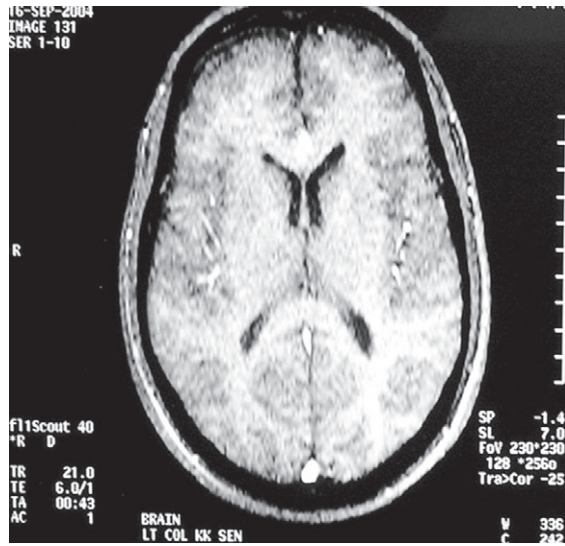


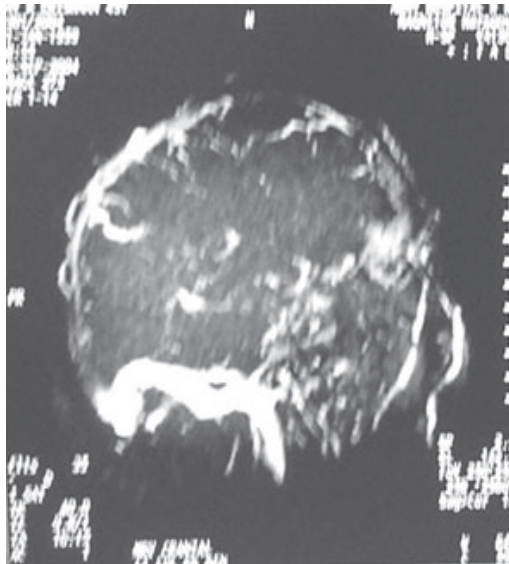
FIGURE 2. MR venography showing occlusion of superior sagittal sinus

#### Case Two

A 49-year-old male was admitted with a head injury following a road traffic accident associated with fracture left zygoma, left subconjunctival hemorrhage and a GCS of



**FIGURE3.** MRI (T1 axial) showing thrombus in superior sagittal sinus



**FIGURE4.** MR venography showing occlusion of posterior third of superior sagittal sinus

8/15. His plantar reflexes were bilaterally extensor. CT scan of the brain showed diffuse cerebral edema while MRI and MRV brain revealed superior sagittal sinus thrombosis (Figs 3 & 4). Pro-coagulant work up did not reveal any abnormality. He responded to a combination of cerebral decongestants, low molecular weight heparin and antibiotics with an improvement in GCS from 8/15 to 10/15.

## DISCUSSION

The precise mechanisms for the development of thrombosis following trauma remain uncertain. Sinus dissection, sinus

distortion and flow impediment by bone fragments can create venous flow obstructions, which in turn induce thrombosis. Associated predisposing procoagulant factors include use of oral contraceptive pills, deficiency of protein C and S, factor V Leiden mutation, elevated blood homocysteine levels and presence of anti phospholipid antibodies. Other factors include infection, dehydration, acquired and congenital heart diseases, pregnancy, neoplasia and connective tissue disorders<sup>1-5</sup>. Severity of head injury or association with fracture is not correlated with the development of CVST, although endothelial damage caused by rotational injury has been suggested as an etiologic factor<sup>6</sup>. Superior sagittal sinus is the commonest dural venous sinus involved<sup>7</sup>, and the thrombus may extend till the torcula<sup>8</sup>. Involvement of sigmoid sinus following trauma has also been reported<sup>9</sup>.

Clinical presentation may be subtle and missed in the posttraumatic scenario unless specifically looked for. Worsening sensorium occurs due to venous infarcts. Alternatively, there may be plateauing of neurological improvement, unexplained fever, papilledema or fresh neurological deficits after initial improvement. All these features should raise suspicion of CVST<sup>7</sup>. Untreated CVST may lead to persistent raised ICT, seizures, visual loss, hydrocephalus and sometimes-unexplained fever as in our first patient. While CT scan findings include hemorrhagic and non hemorrhagic venous infarcts, cord sign and empty delta sign, CT may be normal in 10 - 20% of patients with sinus venous thrombosis. MRI allows certain diagnosis with direct visualization of the thrombus and sinus occlusion is seen on MRV.

The management of CVST is not standardized and is variable. Controlled and randomized studies are difficult to perform because of the multiplicity of clinical features and varied etiopathogenesis. Conservative management is espoused in most patients because of the benign nature of the disease. However various authors have advocated cerebral decongestants, steroids, decompressive craniectomy<sup>3</sup>, sinus thrombectomy and use of unfractionated and fractionated heparin. Urokinase infusion using a micro catheter into the dural sinus through a femoral vein has successfully reestablished venous sinuses patency<sup>10</sup>.

The mortality rate of CVST ranges from 5.5 % -30% and out of those who survive 15.5%-25.5% are left with residual deficits<sup>7</sup>. It would be important to identify the clinical factors that are indicative of a poor outcome, so that a more focused and aggressive treatment program can be pursued. So far, only GCS (<8) and presence of intracerebral hemorrhage are demonstrated as significant and independent predictors of poor outcome<sup>11</sup>. Whether

these observations can be extrapolated to traumatic CVST remains to be proven. Significantly, most of the traumatic CVST have been reported in patients with minor head injury, or in those who did not require surgical intervention for traumatic intracerebral hematoma<sup>8,10,12</sup>.

### CONCLUSION

CVST is often overlooked in the posttraumatic situation resulting in poor prognosis. The condition should be suspected in a patient with head injury who does not improve, has plateauing of neurological recovery, develops seizures or fresh neurological deficits, has persistently raised ICP with papilledema, or intractable fever with leukocytosis. MRV is diagnostic, and prompt identification to receive appropriate therapy can avoid secondary complications which increase morbidity and mortality

### REFERENCES

1. Bosch J, Rovira. Value of cranial MRI in the follow up of dural sinus thrombosis. *Rev Neurol* 1998; 26:971-3.
2. Buonanno F, Moody D, Computed cranial tomography findings in cerebral sinovenous occlusion. *J Comput Asst Tomogr* 1978; 2:281-90.
3. Stefini R, Latronica N, Cornali C, Bollati A, Emergent decompressive craniectomy in patients with fixed dilated pupils due to cerebral venous and dural sinus thrombosis: report of three cases. *Neurosurgery* 1999; 45: 626-9.
4. Stringer WL, Peerless SJ. Superior sagittal sinus thrombosis after closed head injury *Neurosurgery* 1983;12:95.
5. Rinal M. Traumatic thrombosis of dural venous sinuses in closed head injuries. *J Neurosurg* 1967; 27:142-5.
6. Meena AK, Jayalaxmi SS, Murthy JMK. Cortical sinovenous thrombosis following closed head injury. *Neurol India* 2000; 48:195-6.
6. Ferrera PC, Pauze D R, Chan. Sagittal sinus thrombosis after closed head injury. *Am J Emerg Med* 1998;16:382-5.
7. Gowers WR. Manual of diseases of the nervous system. 2<sup>nd</sup> ed. London: Churchill, 1988:416.
8. Kumar GSS, Chacko AG, Joseph M. Superior sagittal sinus and torcula thrombosis in minor head injury. *Neurol India* 2004; 52:123-4.
9. Sousa J, O'Brien D, Barlett R, Vas J. Sigmoid sinus thrombosis in a child after closed head injury. *Br J Neurosurg* 2004; 18:187-8.
10. D'Alise MD, Frank Fichtel F, Horowitz. Sagittal sinus thrombosis following minor head injury treated with continuous urokinase infusion. *Surg Neurol* 1998; 49:430-5.
11. de Bruijn SF, de Haan RJ, Stam J. Clinical features and prognostic factors of cerebral venous sinus thrombosis in a prospective series of 59 patients. *J Neurol Neurosurg Psychiatr* 2001; 70: 105-8.
12. Barbati G, Dalla Monta G, Coletta R, Blasetti AG. Post-traumatic superior sagittal sinus thrombosis. Case report and analysis of the international literature. *Minerv Anesthesiol* 2003; 69:919-25.