

# Traumatic Interhemispheric Hematoma: A Case Report

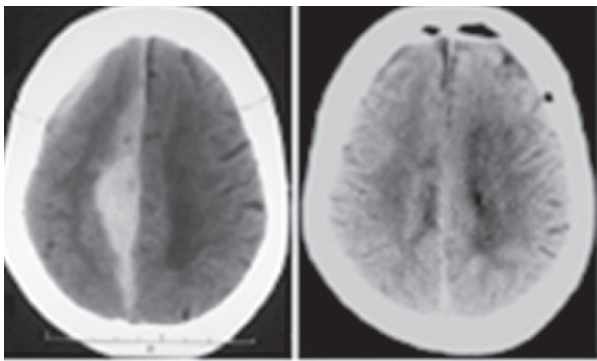
Ratilal Bernardo M D, Vara Luiz Carlos M D

Department of Neurosurgery of Hospital Sao Jose, Lisbon, Portugal

**Abstract :** Interhemispheric subdural hematoma is a rare form of traumatic intracranial hematoma. We report one such case in a sixty-four year old female patient.

**Key words:** falx syndrome; head injury; interhemispheric hematoma.

A sixty-four-year-old woman struck back of her head on ground during a fall two days prior the admission at our institution. There was no loss of consciousness. A day later she noticed headache and progressive gait disturbance, which deteriorated so that she was no longer able to walk even with assistance. At admission she was fully alert with left hemiparesis involving the leg (1/5) more than the arm (3/5) and a homolateral central facial paresis. Deep tendon reflexes were exaggerated on every limb with a left extensor plantar reflex. Laboratory results, including coagulation parameters, were within normal limits. CT showed a right-sided high density interhemispheric lesion and a thin homolateral frontal subdural collection, compatible with fresh blood (Figure 1). There was no skull fracture visible. A right parietal parasagittal craniotomy was performed and right frontal and interhemispheric dark blood clots were evacuated. Postoperative course was uneventful. She was able to walk unaided after five days and was discharged from hospital. On follow-up, she had no residual neurological deficit.



**FIGURE 1.** *Left:* Non-enhanced CT scan disclosing an acute right-sided interhemispheric hematoma and a thin right frontal subdural blood collection; *Right:* post-craniotomy non-enhanced CT scan at the third day.

Address for correspondence : Bernardo Ratilal, Postal: Rua Tristão Vaz, n.31 – 3.esquerdo 1400-350 Lisbon/Portugal  
Email: bratilal@yahoo.com, Phone number: +(351)963047176  
Fax number: +(351)218841049

## DISCUSSION

Although traumatic interhemispheric hematoma is not infrequent in children because of child abuse with shaking, it is rarely encountered in adults. So far more than 100 cases have been reported, usually occurring after the 6<sup>th</sup> decade. Bleeding disturbances, alcoholism and chronic renal failure are predisposing factors<sup>1</sup>. This type of hematoma tends to occur with occipital trauma of low velocity. This may be explained so that an occipital blow in the sagittal plane would facilitate the injury to the anatomic anteromedial orientated bridging veins of the interhemispheric fissure<sup>2</sup>. Most patients have a period between the time of injury and the presentation of prominent neurological deficits such as disturbances of consciousness, seizure, language disorders, gait ataxia, oculomotor dysfunction or a 'falx syndrome', which is characterized by contralateral motor palsy with crural dominance<sup>3</sup>.

We report a mixed acute traumatic interhemispheric and convexity subdural hematoma, even if the latter was of minor clinical significance. Traumatic interhemispheric hematoma seems to be a distinct physiopathologic, clinic and neuroradiological entity with better outcome than acute subdural convexity hematoma. The ideal management is still a matter of discussion but surgery is immediately required in patients with disturbances of consciousness or neurological deterioration.

## REFERENCES

1. Bartels RH, Verhagen WI, Prick MJ, Dalman JE. Interhemispheric subdural hematoma in adults: case reports and a review of the literature. *Neurosurgery* 1995; 36:1210-4.
2. Fruin AH, Juhl GL, Taylon C. Interhemispheric subdural hematoma Case report. *J Neurosurg* 1984; 60:1300-2.
3. Rapana A, Lamaida E, Pizza V, Lepore P, Caputi F, Graziussi G. Inter-hemispheric fissure, a rare location for a traumatic subdural hematoma. Case report and review of the literature. *Clin Neurol Neurosurg* 1997; 99:124-9.