

Hemispheric cerebral ischemia in traumatic brain injury: A report of four cases.

Y R Yadav M Ch, Sanjay Pandey M Ch, Alok Agrawal M D*

Departments of Neurosurgery and *Radiodiagnosis
NSCB Medical College Jabalpur and Hospital, Jabalpur (MP)

Abstract: Vascular injury to brain as a secondary phenomenon is not uncommon in head injury. Abnormality in cerebral blood flow after head injury is well documented. There are plenty of reports of focal vascular insults in head injury; however hemispheric ischemia is not reported so far to the best of our knowledge. Four patients of hemispheric ischemia were treated in last 13 years time out of the total of 13167 patients admitted for head injury. Three patients were males of six months, 30 years and 34 years of age while the fourth patient was a 10-year-old-female. Road traffic accident, assault and fall from height were the mode of accident in these cases. Both the adults died while both the children survived with gross neurological deficits. All four patients had subarachnoid and subdural hematomas along with evidence of hyperextension injury suggested by abrasion on forehead. Severe form of vascular injury like hemispheric ischemia is rare. Subarachnoid and subdural hematoma and hyperextension injuries could be risk factors. Prognosis is poor. There is a need to identify a subgroup of patients at risk of such complications.

Keywords: cerebral infarction, secondary brain injury, traumatic hemispheric cerebral ischemia, vascular insult

INTRODUCTION

Cerebral ischemia is an important contributor to increased morbidity and mortality in patients of head injury. The importance of cerebral vascular dysfunction in the pathophysiology of brain injury, the effect of trauma on cerebral circulation has been well studied^{1,2}. The exact incidence is not known. Isolated cerebro-vascular injury is thought to be quiet common but we have not come across any reference of the global hemispheric cerebral ischemia. However diffuse vascular injury was observed in about 11% of patients with fatal diffuse axonal injury². We are reporting four such patients of diffuse vascular injury producing unilateral hemispheric ischemia.

CASE REPORT

Case 1

A thirty-four-year old male presented with alleged history of assault by a hard and blunt object. He was unconscious since injury, and his GCS on admission was 4/15 (E₁V₁M₂). There was no history of hypertension, diabetes mellitus or any cardiac illnesses. His pupils were 4 mm in size, dilated and not reacting to light bilaterally. He had also developed left sided hemiplegia following the assault. There were abrasions and diffuse swelling on forehead on either side

Address for correspondence : Y R Yadav M Ch, 105 Nehru Nagar, Opposite Medical College, Jabalpur MP 482003
E-mail: yadavyr@yahoo.co.in

and on the vertex. There was no external evidence of injury on neck. He was hyperventilating with rate of 44 per minute and there were bilateral coarse crepitations in the chest. He was intubated and ventilated. CT scan showed right fronto-parietal thin acute subdural haematoma with right fronto parieto-temporo-occipital (hemispheric) hypodensity involving the grey white matter sparing basal ganglia region suggestive of ischemia with gross midline shift (Figure 1). Hypodensity extended on other side adjacent to falx. Subarachnoid bleed in interhemispheric fissure was also seen. Tiny hemorrhagic contusions were also seen in the right cerebral convexity. Patient was also put on osmotic diuretics and ventilation was continued. In spite of treatment, patient deteriorated and died 17 hours

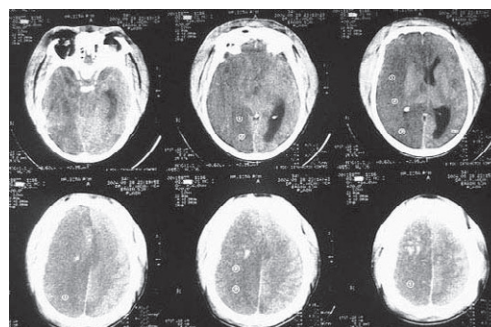


FIGURE 1: Axial CT shows hypo density involving the grey white matter of the right fronto parietal and temporo occipital region. There is interhemispheric subdural bleed, brain swelling ,midline shift and uncocal herniation with hypodensity on other side adjacent to falx

after the injury.

Case 2.

A six-month-old male child had a fall from bed of about 2 feet in height, and became unconscious. He had an episode of generalized tonic-clonic seizures after the fall, and at the time of admission, GCS was 5/15 (E₁V₁M₃). Pupils were 2 mm in size and reacting to light. He was not moving his right side. There was abrasion on left side of his forehead, and his vitals were stable. There was no external evidence of neck injury. CT scan showed left sided fronto-parieto-

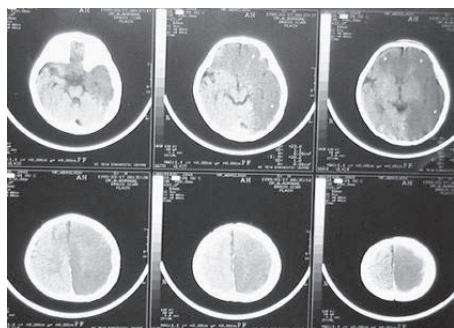


FIGURE 2 : Axial CT shows extensive hypodensity involving the grey white matter of the left fronto parietal and temporo occipital region.

temporal thin acute subdural haematoma and hemispheric hypodensity suggesting of ischemia (Figure 2). There was blood in posterior part of interhemispheric fissure. He was put on conservative management with frusemide and antiepileptic drugs. Doppler for neck vessels revealed normal blood flow through both the internal and external carotids. Patient showed gradual improvement for 20 days after which his neurological status plateaued. Repeat CT showed chronic subdural hematoma in left fronto-parietal region, which was managed by repeated tapping. He showed gradual improvement in sensorium and partial resolution of weakness in right half. He was discharged three weeks after the injury with spontaneous eye opening, no verbal response and right-sided hemiparesis. Child showed gradual improvement in his hemiparesis and speech at follow up. CT done after two years showed cerebral atrophy of left hemisphere with ipsilateral ventriculomegaly (Figure 3). Child is having hemiparesis (power grade 3-4 in proximal group and 1-2 in distal group). He is able to speak few words only with spastic speech, however his comprehension is fairly good. He is able to perform his daily activity without any help. His school performance is below average

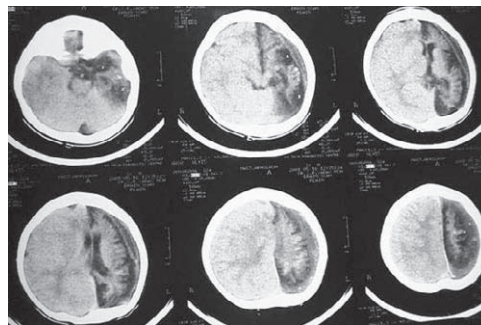


FIGURE 3 : Follow up axial CT shows interval development of left hemispheric atrophy and chronic left sided subdural collection.

Case3.

A 30-year-old-male was brought in 20 hours after a road traffic accident. He had developed hemiplegia on the right since the time of the accident, and had become unconscious 3-4 hours after the accident. He had one episode of generalized seizures, and vomited 5-6 times. There was no history of hypertension, diabetes mellitus or any cardiac illnesses. On admission his GCS was 4/15 (E₁V₁M₂), pupils were fully dilated and sluggishly reacting to light. There were abrasions on right side of his forehead. There was no external evidence of injury in neck. CT showed thin subdural hematoma in left fronto- parietal region with left hemispheric hypodensity and midline shift of 12 mm (Figure 4). There

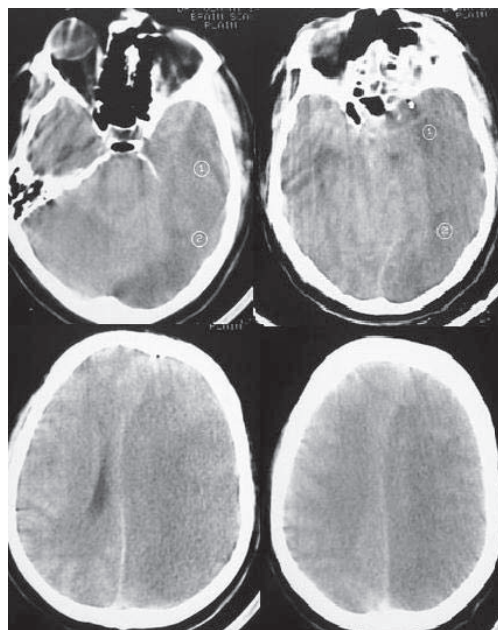


FIGURE 4: Axial CT showing extensive hypo density involving the grey white matter of the left fronto parietal and temporo occipital region including the ipsilateral basal ganglia.interhemispheric subdural bleed, brain swelling, midline shift and uncal herniation is also seen.

was blood in the interhemispheric fissure. He was intubated and hyperventilated and mannitol and frusemide were administered. There was no response to treatment, and the patient deteriorated and died 30 hours after the accident.

Case 4:

A ten-year-old girl sustained head injury in a road traffic accident. She became unconscious immediately after the accident. There was no history of seizures or ear, nose and throat bleeding. There was no history of hypertension, diabetes mellitus or any cardiac illnesses. Her Glasgow coma scale was 4/15 ($E_1M_2V_1$), and pupils were normal sized, reacting to light. There was no external evidence of injury in neck. She had abrasions on right forehead. CT done on the day of injury showed normal-sized ventricles including basal cisterns. There was subarachnoid hemorrhage in posterior interhemispheric fissure. Her condition remained status quo for the next 5 days. MRI of brain was done looking to her very minimal findings in CT and poor neurological status. MRI revealed gyral swelling and signal alteration in left hemisphere. Gyral signal alterations were hyper intense in T2 and FLAIR and iso to hypo intense in T1-weighted images. Left lateral ventricle was effaced. There was minimal subdural bleed in bilateral temporal lobe and adjacent right cerebellum (Figure 5). She was shifted to our hospital for further treatment, and was put on frusemide, mannitol and anticonvulsants. Doppler for neck vessels revealed normal blood flow through both carotids in its course in the neck. She showed gradual neurological recovery, and repeat CT done after 28 days of injury showed

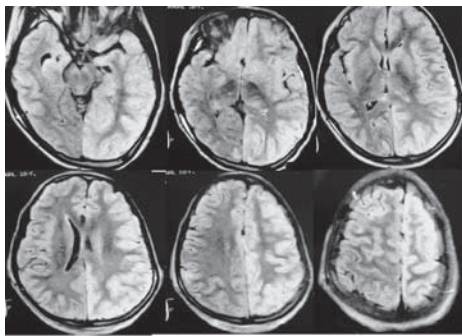


FIGURE 5 : T2W axial images reveal gyral swelling and hyper intensity of the left cerebral hemisphere.

infarct in left occipital lobe. GCS at the time of discharge 45 days later was $E_4M_6V_2$. There was right-sided hemiparesis with power grade 1-2 in proximal joints and no power in distal joints. She was advised physiotherapy and to come for follow up after one month.

DISCUSSION

Based on the observations of forehead bruise in all cases and associated unilateral injury to the lateral aspect of the skull in two of our cases we propose that hyperextension and rotation mechanism leading to dissection/thrombosis of intracranial portion of carotid artery could be the cause of vascular injury in our cases. Association of subarachnoid bleed and subdural hematoma in all our cases suggest that vasospasm could also be responsible for ischemia. The posterior cerebral artery (PCA) involvement could be explained on the basis of either compression of the vessel in the ambient cistern secondary to midline shift or to the fetal origin of the PCA. The anterior cerebral artery (ACA) involvement could be due to absence of anterior communicating artery. In one of our patient evidence of ischemia was not there in first CT scan suggesting that it was secondary insult which can be prevented. Doppler study of the neck vessel was possible in only two cases, which did not show any lesion in the neck, other two cases were in very poor condition and both of them died before these investigations could be done.

Although exact incidence and pathophysiology of cerebral ischemia is not known, however various pathological finding were reported in the literature. Varying degree of cerebral ischemia in head injury has been reported^{1,2,3}. Intravascular thrombosis has been associated with ischemia⁴. Multiple cerebrovascular abnormalities including subarachnoid hemorrhage, focal platelet accumulation, and severe ischemia are seen in traumatic brain injuries⁵. Three stages of hemodynamic changes are observed in severe head injury: hypoperfusion, hyperemia and vasospasm. Isolated vascular injury like infarct in distribution of artery of Heubner is well reported⁶. Diffuse vascular injury has been reported in 11.7% of patients in fatal diffuse axonal injury². Vascular endothelial growth factor was increased in CSF after brain injury suggesting that vascular injury occurs in head injury patients⁷. Microvascular basal lamina damage was also seen in brain injury. Ischemic damage in intracranial hematomas was thought to be more commonly due to artery compression secondary to brain shift and herniation⁸. Pathophysiological studies in traumatic brain injuries revealed primary membrane damage to neuronal cell bodies, white matter structure and vascular beds due to shear forces. These injuries were similar to strokes.

The definite evidences of proof of benefit of any drug altering coagulation in human being are lacking. Enoxaparin reduced brain edema, cerebral lesions, and improves motor and cognitive impairments induced by traumatic brain injuries in rats⁹. However in the other study antithrombin treatment in patients with traumatic brain injury resulted only in marginal reduction of hyper

coagulation, and could not produce any obvious influence on the progression of brain injury, on CT scan, on outcome or time needed for intensive care¹⁰. Early and late intravenous infusion of nor epinephrine has been seen to increase cerebral perfusion in rats¹¹, and this can also be used as a treatment option to decrease ischemic insult to the brain. L- Arginine was found to improve microcirculation in missile injury which was decreased in early stage of injury in an experimental study on cats¹².

Routine use of methods detecting cerebral blood flow in head injury can identify subgroup of patients in all head injury likely to get secondary insult due to vascular insults. It has been seen that the post concussion syndrome in mild head injuries could be due to vascular insults. Hyperventilation or lowering of blood pressure can in fact be detrimental in such cases¹³.

CONCLUSION

There is a need to identify subgroup of patients at risk of vascular complications by use of methods detecting cerebral blood flow. Association of hyperextension and rotation injuries, patients with subarachnoid hemorrhage and subdural hematoma in such patients may point towards certain path physiological mechanism. Management strategies useful in prevention of such insults and early management of such complications when they occur can improve prognosis.

REFERENCES

1. Dewitt DS, Prough DS. Traumatic cerebral vascular injury: the effect of concussive brain injury on the cerebral vasculature. *J Neurotrauma* 2003; 20: 795-825.
2. Pittella J E, Gusmao SN. Diffuse vascular injury in fatal road traffic accident victim: its relation to diffuse axonal injury. *J Forensic Sci* 2003; 48: 626-30.
3. Schroder ML, Muizelaar JP, Fatouros P, Kuta AJ, Choi SC. Early cerebral blood volume after severe traumatic brain injury in patients with early cerebral ischemia. *Acta Neurochir Suppl [Wien]* 1998; 71:127-30.
4. Stein SC, Graham DI, Chen XH, Smith DH. Association between intravascular micro thrombosis and cerebral ischemia in traumatic brain injury. *Neurosurgery* 2004; 53 : 687-91
5. Dietrich WD, Alonso O, Busto R, Prado R, Zao W, Dewanjee MK, Ginsberg MD. Posttraumatic cerebral ischemia after fluid percussion brain injury: an auto radiographic and histopathological study in rats. *Neurosurgery* 1998; 43:585-93.
6. Fujimura M , Kameyama M, Motohashi O, Kon H, Ishi K, Onuma T. Cerebral infarction in the caudate nucleus associated with acute epidural haematoma and diffuse brain injury in a child after severe head injury. *Childs Nerv Syst* 2004; 20:430-3.
7. Shore PM, Jackson EK, Wisniewski SR, Clark RS, Adelson PD, Kochanek PM. Vascular endothelial growth factor is increased in cerebrospinal fluid after traumatic brain injury in infants and children. *Neurosurgery* 2004; 54:605-11.
8. Abe M, Udono H, Tabuchi K, Uchino A, Yshikai T, Taki K. Analysis of ischemic brain damage in cases of acute subdural Hematomas. *Surg Neurol* 2003; 59:464-72.
9. Wahl F, Grosjean-Piot O, Bareyre F, Ujan A, Stutzmann JM. Enoxaparin reduces brain edema, cerebral lesions, and improves motor and cognitive impairments induced by traumatic brain injuries in rats. *J Neurotrauma* 2000; 17:1055-65.
10. Grenander A, Bredbacka S, Rydvall A, Aroch R, Edner G, Koskinen LO, Olivecrona M. Antithrombin treatment in patients with traumatic brain injury: a pilot study. *J Neurosurg Anesthesiol* 2001; 13:49-56.
11. Kroppenstedt SN, Thomale UW, Griebenow M, Sakowitz OW, Schaser KD, Mayr PS, Unterberg AW, Stover JF. Effect of early and late intravenous norepinephrine infusion on cerebral perfusion, microcirculation, brain tissue oxygenation, and edema formation in brain injured rats. *Crit Care Med* 2003; 31:2211-21.
12. Wang F, Chen CC, Mao BY, Mao Q, Zhang YK, Lei D, Xu RX. Effect of L-Arginine on the changes of cerebral microcirculation following craniocerebral missile wound at early stage in cats. *Sichuan Da Xue Xue Bao Yi Xue Ban* 2004; 35:402-5.
13. Bouma GJ, Muizelaar JP, Choi SC, Newlon PG, Young HF. Cerebral circulation and metabolism after severe traumatic brain injury: the elusive role of ischemia. *J Neurosurg* 1991; 75:685-93.