

## Penetrating craniocerebral injury with nails: Case report

Amresh Bhaganagare M S, Trimurti Nadkarni M Ch, Atul Goel M Ch

Department of Neurosurgery

King Edward Memorial Hospital, Seth G.S. Medical College, Parel, Mumbai

**Abstract:** A 19 year-old-male presented with three nails being hammered into his head. The patient had no neurological deficits at the time of presentation. Computed tomography (CT) of the brain showed the nails to have penetrated both tables of the skull. All of these metallic foreign bodies were extracted surgically. One of these nails, noted in the midline, was bent at its shaft and lay in the epidural space. The other two nails lying parasagittally had penetrated into the brain parenchyma of the frontal lobes. There was no intraparenchymal hemorrhage noted in relation to the tracts of the nails. The patient had an uneventful postoperative recovery. The relevant literature related to this unusual case is reviewed.

**Keywords:** craniocerebral injury, nails, penetrating injury

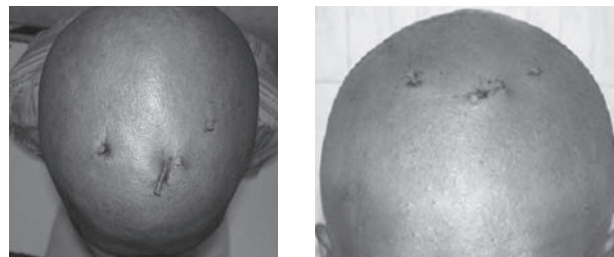
### CASE REPORT

A 19-year-old college student, a victim of campus rivalry, walked into the emergency department six hours after being assaulted by four people. He had been gagged and three nails were hammered into his head at the vertex. He was unconscious for an hour after the episode. On admission the patient had no neurological deficit. Local examination of the head after shaving revealed three nail heads on the vertex (Fig.1A and B). The location of the nails was further delineated on the bone algorithms of the CT scan of the head. The midline nail was lateral to sagittal suture on left side and 4 cms in front of coronal suture. The head end of nail was bent forwards on scalp skin. The second nail noted on the right side lay in the frontal area 1 cm in front of coronal suture and 6cms lateral to sagittal suture with head of the nail flush to scalp skin. The third nail on left side was at the coronal suture, 6 cms from the sagittal suture with head of nail flush to the scalp skin. The CT (computed tomographic) scan demonstrated the paths of the nails more vividly (Fig.2). All the nails had penetrated both tables of the skull. The nails on either side of the midline had penetrated the tissues perpendicularly and their tips lay within the brain. The midline nail was noted however to have a tangential course through the skull with its tip

lying in the epidural space. The nails were removed surgically using an orthopedic surgery plier under general anesthesia (Fig.3). There was no bleeding from any of the entry sites of the nails and the scalp puncture sites were primarily sutured. All the nails were made of iron and two of these measured 5cms in length and the third was 2.5 long (Fig 3). The patient was conscious, alert and without neurological deficits after reversal of anesthesia. A postoperative CT scan of the brain was done 6 hours later showed small fresh bleed in right frontal lobe along the track of nail tip. Delayed postoperative CT scan brain 6 days later showed resolution of the clot. Patient received intravenous antibiotic for 2 weeks. Patient is asymptomatic without neurological deficits on follow up after 3 months.

### DISCUSSION

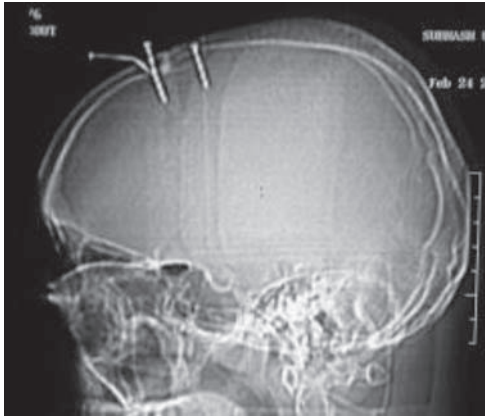
Very few cases of penetrating injuries of the brain caused by a nail have been reported in the literature<sup>1,2,3,4,5,7,9</sup>. Nailing of the head is an unusual type of penetrating



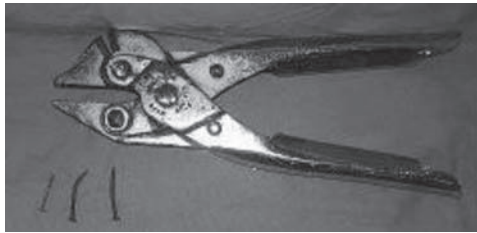
**Fig 1 A&B:** Photographs of head, superior and frontal view showing three nails driven into the vertex. One on right side, second just to left of midline and the third nail on left side. The heads of first and third nails are flush with skin and the second nail is bent on its own shaft.

#### Address for Correspondence:

Professor Trimurti D. Nadkarni  
Department of Neurosurgery,  
King Edward Memorial Hospital,  
Seth G.S. Medical College, Parel, Mumbai 400 012  
Tel: 91-22-24129884; Fax: 91-22-24143435  
E-mail: tdnadkarni@hotmail.com



**Fig 2:** CT brain (bone window), sagittal view showing three radio-opaque nails which have penetrated both tables of skull and entered the brain parenchyma.



**Fig 3:** showing the plier with three nails which were extracted out of skull, the two longer ones were 5cms each in length and the shorter one was 2.5cms in length

injury, which may be the result of a suicide<sup>14</sup>, homicide, punishment or accident<sup>4,5,7,9,13</sup>. The present case is of assault and this type of injury dates back to ancient times when criminals were punished by driving long nails into the head<sup>4</sup>. Similar to the case presented here, in most of the cases reported in the literature, the nails were situated on or close to the midline<sup>4,5,7,9</sup> due to the belief that it will cause instant death<sup>2</sup>. Most of the cases reported in the literature survived and suffered no significant neurological deficit<sup>4-7,13</sup>.

The extraction of such nails is usually done easily and can be accomplished by gentle traction<sup>4,7</sup>. Contrary to belief, serious hemorrhage at the time of injury is unusual even when the nail has transfixed the sagittal sinus.

## REFERENCES

1. Aarabi B. History of the management of craniocerebral wounds. In: Aarabi B, Kaufman HH, Dagi TF, George ED, Levy ML, editors. *Missile Wounds of the Head and Neck*. Vol 1. Park Ridge, Illinois; American Association of Neurological Surgeons; 1999. p.281-92.
2. Ljunggren B, Strömlad LG. The good old method of the nail. *Surg Neurol* 1977; 7:288-92.
3. Luotonen J. Intracranial penetration of a nail from nailing gun through cheek and infratemporal Fossa. *J Laryngol Otol* 1986;100:247-50.
4. Ohaegbulam SC, Ojukwu JO. Unusual craniocerebral injuries from nailing. *Surg Neurol* 1980;14:393-5.
5. Olumide AA, Adeloje A. Unusual craniocerebral injuries: report of two cases in Nigerians. *Surg Neurol* 1976; 6:306-8.
6. Reeves DL. Penetrating cranio-cerebral injuries: report of two unusual cases. *J Neurosurg* 1965; 23:204-5.
7. Shenoy SN, Raja A. Unusual self-inflicted penetrating craniocerebral injury by a nail. *Neurol India* 2003; 51:411-3.
8. Kim HS, Ko K. Penetrating trauma of the posterior fossa resulting in vernet's syndrome and internuclear ophthalmoplegia. *Journal of Trauma-Injury Infection & Critical Care* 1996;40:647-9.
9. Tiwari SM, Singh RG, Dharker SR, Chaurasiya BD. Unusual cranio cerebral injury by a key. *Surg Neurol* 1978; 9:267.
10. Greene KA, Dickman CA, Smith KA, Kinder EJ, Zabramski JM. Self-inflicted orbital and intracranial injury with a retained foreign body associated with psychotic depression: case report and review. *Surg Neurol* 1993; 40:499-503.
11. Andrade GC, Silveira RL, Arantes AA Jr, Fonesca Filho GA, Pinheiro N Jr. Penetrating brain injury due to a large asbestos fragment treated by decompressive craniectomy: case report. *Arq Neuropsiquiatr* 2004;62:1104-7.
12. Stables G, Quigley G, Basu S, Pillay R. An unusual case of a compound depressed skull fracture after an assault with a stiletto. *Emerg Med J* 2005; 22:303-4.
13. Rao BD, Reddy DR. An unusual intracranial foreign body. *Neurol India* 1971; 19:95.