

Minor head injury

Ashok Kumar Mahapatra M Ch, Deepak Agrawal M Ch*, Raj Kumar M Ch

Department of Neurosurgery, Sanjay Gandhi Postgraduate Institute of Medical Sciences, Lucknow - 226014, &
*All India Institute of Medical Sciences, Ansari Nagar, New Delhi 110029

Abstract: In India about one million people sustain head injury every year. Minor head injury constitutes about 80 - 90% cases of total head injury patients. About 50% minor head injury cases have associated organic brain dysfunctions. Studies like SPECT, VEP, BAER, TCD and P₃₀₀ recordings have demonstrated hypoperfusion and dysfunctional abnormalities of brain parenchyma in most of the cases having post-concussion syndrome and persistent post-concussion syndrome. Significant blood flow abnormalities are found in medial temporal lobe, hippocampus and frontal lobe etc, which are responsible for various functional problems.

Keywords: minor head injury, post-concussion syndrome

INTRODUCTION

Minor head injury is also known as mild traumatic brain injury or concussion. It has been the subject of investigations in recent years, because it carries organic brain damage despite having normal CT of brain¹.

Minor head injuries, form the bulk of head injuries ranging from 80 to 90%. It amounts to 800000 (minor) head injuries in India per year. More than 50% minor head injury cases continue to have problems lasting months or years.

CLINICAL FEATURES

An interdisciplinary special interest group (BISIG) of the American Congress of Rehabilitation Medicine (Handbook 16)² has laid down the criteria's for minor head injury, which are:

1. Loss of consciousness not exceeding 30 minutes
2. GCS score between 13 and 15 after the initial 30 minutes
3. Post-traumatic amnesia should not exceed 24 hours.

Post concussion syndrome was defined as history of head trauma with loss of consciousness that precedes symptoms onset by a maximum of four weeks with three or more symptoms of the following³.

Address for Correspondence:

Dr. Raj Kumar
Professor & Head, Department of Neurosurgery
Sanjay Gandhi Post Graduate Institute of Medical Sciences
Lucknow - 226014, U.P. [INDIA]
Phone No. 0522-2668700, 2668800 Ext. 2157 (C), 2158 (R),
2107 (OT), 2741 (O), Fax No.: 91(522) 2668129 & 2668017
e-mail: rajkumar@sgpgi.ac.in & rajkumar1959@gmail.com

- Headache, dizziness, malaise, fatigue, noise intolerance.
- Irritability, depression, anxiety, emotional liability.
- Subjective concentration, memory or intellectual difficulties without neuropsychological evidence of marked impairment.

Post-concussion syndrome has been reported to occur in upto 80% of the patients following minor head injury⁴. This syndrome includes symptoms such as headache, irritability, poor concentration, memory disturbances, dizziness, anxiety and depression¹. Persistent post-concussion syndrome is defined as persistence of symptoms of post-concussion beyond 3 months. It is seen in more than 30% of cases and upto 15% may have persistent disabling symptoms beyond 6 months^{5,6}.

PATHOPHYSIOLOGY

Smith et al⁷ found that bilateral dentate hilar neuron loss was a consistent finding two weeks after minor head injury and was uniformly associated with memory dysfunction. Hippocampal lesions are found to be responsible for this dysfunction. Dentate gyrus, subicular complex and entorhinal cortex are the structures involved in these injuries.

A study at All India Institute of Medical Sciences, New Delhi using SPECT brain showed medial temporal hypoperfusion in 86% cases and frontal hypoperfusion in 13% cases⁵. These findings may result from vasospasm, direct vascular injury and perfusion changes due to alterations in remote neuronal activity (diaschisis)⁸. A significant medial temporal hypoperfusion has been demonstrated by SPECT in cases of pediatric post concussion syndrome, which would imply that medial

temporal lobe damage involving hippocampus may occur after minor head injury. Role of Medial temporal hypoperfusion (MTH) has been documented in patients with postconcussion vertigo also 5 for publish of minor head injury⁵.

Hippocampus is especially vulnerable to undergo such ischemic, hypoxic changes and damage may be responsible for seizures. Extent of hippocampal damage may be correlated with severity of memory impairment (personal experience). There is evidence to show that brain is more vulnerable to ischemic injury after minor head injury^{1,9}.

INVESTIGATIONS

CT scan has low sensitivity of less than 10% in minor head injuries^{1,10,11}. Neuropsychological testing, evoked potential, P₃₀₀ testing (event related evoked potential) PET, SPECT and MRI have been the tools to investigate minor head injuries and these correlated with cerebral dysfunction and with symptoms in case of minor head injuries¹². Ninety percent of cases with minor head injury having post concussion syndrome had abnormal findings on PET or SPECT imaging.

In our study SPECT has shown a sensitivity of 80% which is excellent when compared to abysmally poor sensitivities of 9% for CT and 46% for MRI scan recorded by others^{10,11}. SPECT scan revealed structural lesions in 87.5% compared to 37.5% on CT scan when mild and moderate head injuries were studied by Nedd et al¹³. Both SPECT and PET dynamic imaging modalities are used to measure a regional blood flow

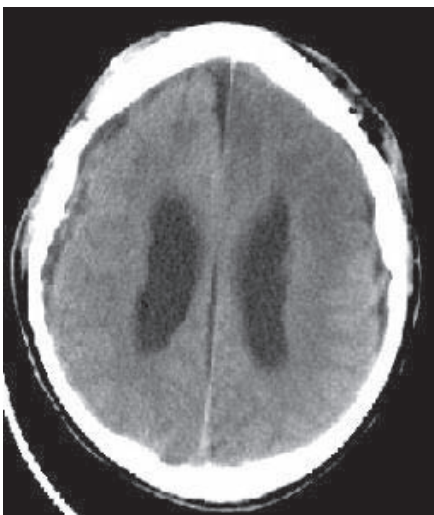


Fig 1: Minor head injury showing normal CT scan.

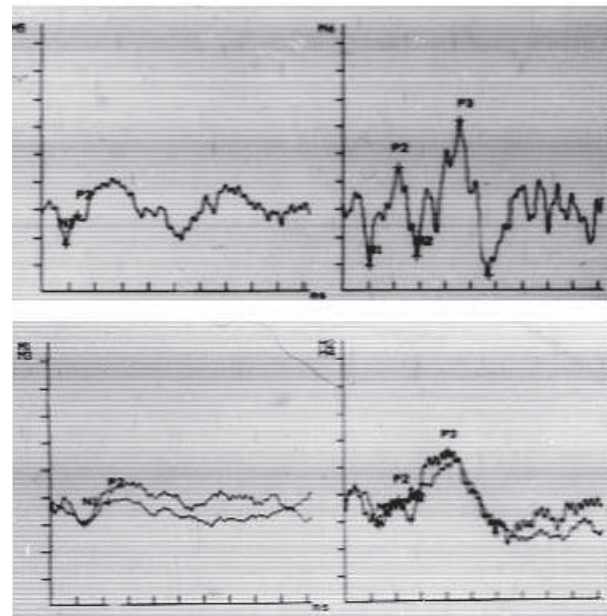


Fig 2: The curve showing delayed responses in P 300 recording

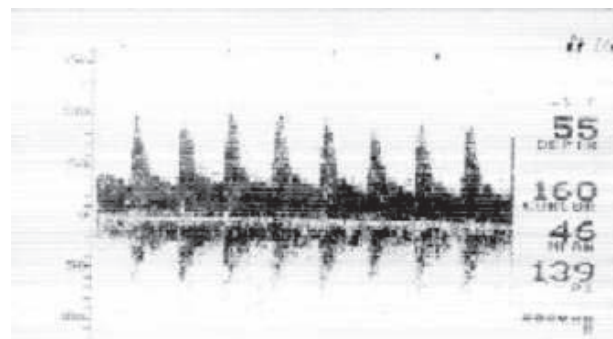


Fig 3: TCD impact of minor head injury shows normal flow velocity.

and cerebral blood volume. Both are proven to be more sensitive than CT and MR imaging with a sensitivity approaching to 90%¹³. Brain SPECT has a proven role in early identification of children prone to develop persistent post concussion syndrome^{1,5}. The role of transcranial Doppler BAER, VEP has also been established in demonstrating the perfusion abnormalities in cases of minor head injuries^{14,15}. VEP and BAER were studied at All India Institute of Medical Sciences, New Delhi, and found to be abnormal in 57% of adult cases having abnormal CT in minor head injury, while in children these were abnormal in 45% cases with abnormal CT scan, with persisting post concussion syndrome^{14,15}.

MANAGEMENT

Investigative tools such as SPECT, PET and neuropsychological assessment help in prognostication,

especially in preschool children as there is good evidence that even minor head injury, if occurring at any age that is critical for the development of a certain skills, which may cause persisting deficits¹⁶. Wrightson et al prospectively studied the effect of minor head injury on preschool children, which it seemed to have affect on the process of learning to read¹⁶.

Profound brain perfusion abnormalities have been demonstrated behind a seemingly normal CT head of such 'minor' head injury patients with post concussion syndrome. A neurotrophic agent, piracetam has been tried in such patients. It has neuroprotective properties, which is mediated through effects on the cell membrane¹⁷. Piracetam has beneficial effects on the cerebral blood flow by decreasing the adhesivity, aggregation, and deformability of erythrocytes along with flow thrust tension of the blood¹⁸. If early identification and diagnosis of these children could be made, the teachers of such children could be made aware and remedial teaching measures could be made available to them¹⁹. Low doses of Piracetam can reverse cerebral perfusion and symptomatic improvement may ensue.

CONCLUSION

Children with medial temporal hypoperfusion are much more likely to develop memory and learning disorders. Minor head injury is associated with organic brain damage. SPECT, VEP, and BAER are much more sensitive than CT in detecting brain dysfunction. There are significant blood flow abnormalities in minor head injury leading to functional problems, which was evident by P300, TED and SPECT abnormalities.

REFERENCES

1. Agrawal D, Mahapatra AK: Minor head injury in text book of written by Prof. A. K Mahapatra & Raj Kamal, Modern publishers, New Delhi, India 3rd edition 2005, pp 123 – 8.
2. Mild head injury interdisciplinary special interest group of the American Congress of Rehabilitation Medicine. Definition of mild traumatic brain injury. *J Head Trauma Rehabil* 1993; 8: 86 – 8.
3. World Health organization: International statistical classification of disease and related health problems, 10th ed. Geneva, Switzerland, World Health Organization, 1992.
4. Hugenholtz H, Stuss DT, Stethem BA, Richard MT. How long does it take to recover from a mild concussion? *Neurosurgery* 1998; 22: 853 – 8.
5. Agrawal D, Dowda NK, Bal CS, Pant M, Mahapatra AK. Is medial temporal injury responsible for pediatric post concussion syndrome. A prospective controlled study with Single – photon emission computerized tomography. *J Neurosurg (Pediatric)* 2005; 102 : 167 – 71.
6. Jain KC, Mahapatra AK, Walia BS: Objective assessment of post – minor head injury syndrome. A P-300 and blood flow velocity study. *Clin Neurol Neurosurg* 1997; 99(Suppl): S74 (Abstract).
7. Smith DH, Lowenstein DH, Gennarelli DI, McIntosh TK. Persistent memory dysfunction is associated with bilateral hippocampal damage following experimental brain injury. *Neurosci Lett* 1994; 168 : 151 – 4.
8. Hofman PAM, Stapert SZ, van Kroonenburgh MJPG, Lolles J, De Kruik Kelle, Welmink JT. MR imaging, Single-photon emission CT and neurocognitive performance after mild traumatic brain injury. *AJNR* 2001; 22: 441 – 9.
9. Jenkins LW, Lu Y, Johnston WE, Lyeth BG, Prough DS. Combined therapy affects outcomes differently after mild traumatic brain injury and secondary forebrain ischemia in rats. *Brain Res* 1999; 817 ; 132 – 44.
10. Kant R, Smith- Seemiller L, Isaac G, Duffy J. Tc-HMPAO SPECT in persistent postconcussion syndrome after mild head injury: Comparison with MRI/CT. *Brain Inj* 1997; 11 : 115.
11. Jain KC, Mahapatra AK, Walia BS. Objective assessment of post minor head injury syndrome. A P300 and blood flow velocity study. *Clin Neurol Neurosurg* 1997, 99 : 574(Abstract).
12. Umile EM, Sandel E, Alavi A, Terry CM, Plotkin RC: Dynamic imaging in mild traumatic brain injury: support for the theory of medial temporal vulnerability. *Arch Phys Med Rehabil* 2002; 83 : 1506 – 13.
13. Nedd K, Sfakainakis G, Ganzw Urichchio B, Vernberg D, Villaneva P : 99Mtc – HMPAO SPECT of the brain in mild to moderate traumatic brain patients compared with CT – A prospective study. *Brain Inj* 1993 ; 7 : 469 – 79.
14. Jain KC, Mahapatra Ak : Cerebral blood flow velocity P300 studies in patients with minor head injury : A preliminary study. In: Brain protection and neural trauma. VK Khosla, VK Kak and BS Sharma (eds), Narosa Publishers, New Delhi, 2000: pp 298 – 305.
15. Jindal A, Mahapatra AK: Transcranial Doppler in neurosurgery. *Neurol India* 1999; 4: 57 – 8.
16. Wrightson P, McGinn V, Gronwall D. Mild head injury in preschool children: evidence that it can be associated with persisting cognitive defect. *J Neurol Neurosurg Psychiatry* 1995; 59: 375 – 80.
17. Peuvot J, Schanck A, Deleers M et al. Piracetam-induced changes to membrane physical properties : a combined

- approach by ^{31}P nuclear magnetic resonance and conformational analysis.
Biochem Pharmacol 1995; 50 : 1129 – 34.
18. Vernon E: Piracetam a nootropil analogue. In: Goulliaev AH, Seening A (eds) : Piracetam and other structurally related neurotropsics.
Brain Res Rev 1991; 19 : 180.
19. Agrawal D, Naveen K, Bal CS, Mahapatra AK: Post-concussion vertigo. Is the cause central? Correlation with SPECT and CT.
Neurosciences Today 2003; 7: 33 – 6.