

Single photon emission computed tomography evaluation in patients with mild to moderate head injury

SS Dhandapani M Ch, A Sharma M Ch, SK Rajan M Ch, Karam Chand M Ch, L Das M Ch
Dept. of Neurosurgery, Safdarjung Hospital & VM Medical College, New Delhi

Abstract: Head injury is a major cause of disability and death in adults. The commonest pathological substrate in patients dying with blunt head injury is ischemic brain damage. Evaluation of cerebral perfusion is currently not a standard practice. We reviewed the medical records of 40 patients with Mild & Moderate Head Injury (GCS 9-14) who had 43 SPECT brain perfusion studies (Tc99m-ECD). They were evaluated in relation to GCS, NCCT (TCDB) grading, timing of scan and other factors. It was found that some degree of hypoperfusion in SPECT was noted in most, with moderate head injury patients having more severe hypoperfusion than those with mild head injury. Also, hypoperfusion was more marked during the first 24 hours of injury. In univariate analysis of various factors on the outcome, severe hypoperfusion and moderate/severe hypoperfusion emerged as significant predictors of unfavourable outcome (P values 0.05 and < 0.001 respectively). With respect to the area of hypoperfusion, parietal involvement had more impact on neurological outcome than other areas (P = 0.07). Bilateral involvement and other factors had no significant relationship with outcome. In multivariate analysis using binary logistic regression, severe hypoperfusion was found to have significant effect on outcome independent of GCS, CT category and timing of SPECT (P=0.02).

Keywords: head Injury; hypoperfusion; outcome; SPECT

INTRODUCTION

Head injury is a leading cause of disability and death in adults, and most patients (85–95%) have mild-to-moderate injury¹. Complex pathophysiological and functional alterations are involved in head injury which may result in long term disability. The commonest pathological substrate in patients dying with blunt head injury is ischemic brain damage². Significant developments in imaging techniques have contributed to the knowledge of the ischemic pathophysiology of head injury. Although extensive research is available on severe head injury, less is known about mild-to-moderate head injury despite the fact that most patients sustain this type of injury.

But perfusion studies of brain have not become a standard practice. The measurement of regional cerebral blood flow (rCBF) by single-photon emission computed tomography (SPECT) represents the most commonly available and widely applied functional brain imaging technique used in clinical practice^{3,4}. It is obtained by the injection of one of the series of compounds that cross the blood-brain barrier and are distributed in the brain according to regional perfusion or to the density

of a given receptor. The regional brain distribution of the injected compound can be measured because it is bound to a radioactive substance that emits photons. Emitted photons are collimated to facilitate determining their source and detected with sodium iodine crystal detectors. Finally, the techniques of CT are used to reconstruct the density of photons emitted by each volume element (voxel) of the brain^{4,5}.

METHODS

We reviewed the medical records of patients with mild and moderate head injury who had a SPECT brain perfusion study in our department. Patients (non-consecutive) admitted with head injury under the Neurosurgical department of Safdarjung Hospital, New Delhi, since 2008 with GCS 9-14, on primary conservative management, stable enough to be shifted for SPECT, underwent SPECT scan whenever feasible.

SPECT was performed in a silent room with lights. Eyes of patients were open and ears were left unplugged. Intravenous injection of 740 MBq, ^{99m}Tc-ECD (BARC, Mumbai) was given in patients of age more than 18 years while for patients less than 18 years of age the dose was calculated based on the patient's weight (10 MBq /kg). Acquisition was done on a dual-headed rotating scintillation gamma camera (Millennium, GE) with the patient supine, head-rest attached, smallest permissible radius of rotation, 128 x 128 matrix, 360°, 120

Address for correspondence :

SS Dhandapani, Asst. Professor
Dept. of Neurosurgery, Safdarjung Hospital
New Delhi-110029. E-mail: ssdhandu@rediffmail.com

projections, 25 seconds per projection by using either low-energy ultrahigh-resolution fan beam. Subsequently raw data were smoothed with Butterworth filtered Nyquist of 1.404 cycles/cm and cut-off frequency of 0.56 and Chang attenuation correction was applied. Images were then reoriented in axial, coronal, and sagittal planes. Final data were displayed on a computer monitor and analyzed by using multi-point color scale⁶. On the basis of SPECT, patients were grouped into mild, moderate and severe hypoperfusion depending on the worst state of perfusion.

SPECT changes were evaluated in relation to timing of study, location, Glasgow coma score (GCS) and TCDB CT category⁷. The clinical and radiological data of the patients were analysed retrospectively in relation to GOS at 2 months following trauma. Good recovery or moderate disability was considered as favorable outcome and severe disability, persistent vegetative state or death was considered as unfavorable outcome⁸.

SPSS software (version 17, SPSS Inc, Chicago) was used for the statistical analyses. Proportions were compared by using chi-square tests or Fisher's exact test, wherever appropriate. Multivariate analysis was conducted with logistic regression adjusting for admission GCS, TCDB CT category, day of SPECT and degree of hypoperfusion. Two sided significance tests were used throughout, and the significance level was kept at $P < 0.05$.

RESULTS

We had 40 patients who underwent Brain SPECT. The age distribution is as shown (Fig 1). The mean age was 34 years. There were 5 females and 35 males. Out of

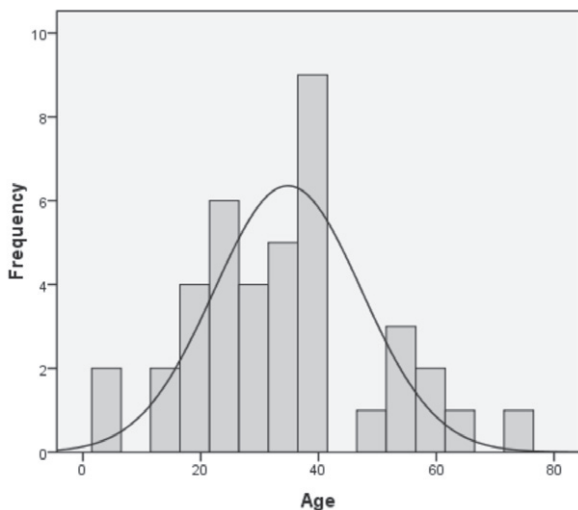


Fig 1: Age Distribution

40, three had SPECT twice. Among the 43 SPECT studies, 18 and 14 had severe and moderate hypoperfusion at the most (Fig 2).

Of the 43 studies, 8 were performed within 24 hours of injury, 21 from 1 to 3 days, 5 from 4 to 14 days, 9 studies between 2 and 3 weeks. All patients who underwent SPECT within 24 hours were found to have moderate to severe hypoperfusion ($P = 0.07$) (Fig 3).

Hypoperfusion was found most commonly in temporal lobe (30), followed by frontal (29) and parietal (19) lobes (Fig 4). The degree of hypoperfusion in relation to GCS

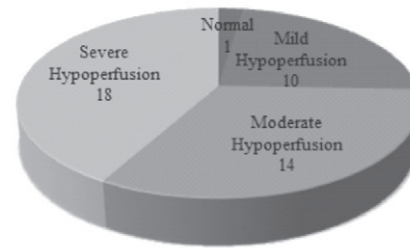


Fig 2: SPECT Findings

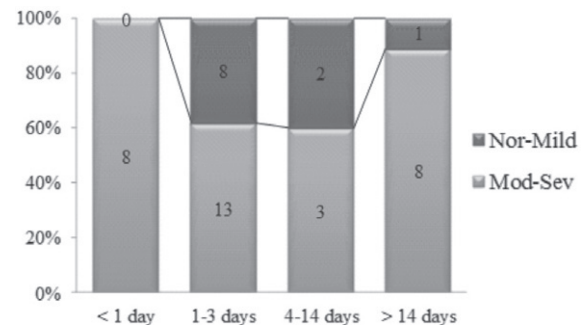


Fig 3: Day of injury Vs Hypoperfusion

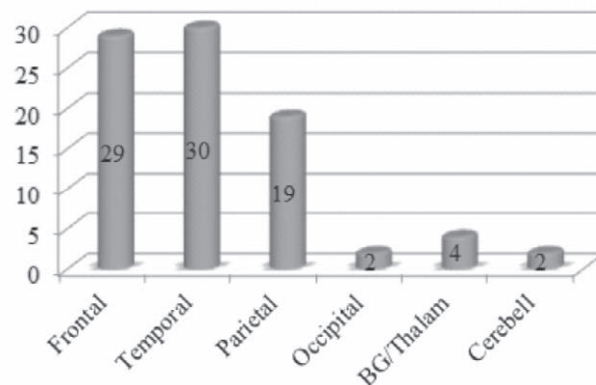


Fig 4: Hypoperfusion Localization

and TCDB CT Category is as shown (Figs 5 & 6). Even in patients with near normal CT, 50% had moderate hypoperfusion (Fig 6).

Neurological outcome data was available for 20 patients. In univariate analysis of various factors on the outcome, severe hypoperfusion and moderate/severe hypoperfusion emerged as significant predictors of unfavourable outcome (P values 0.05 and < 0.001 respectively) (Fig 7).

With respect to the area of hypoperfusion, parietal involvement had more impact on neurological outcome than other areas (P = 0.07). Bilateral involvement and

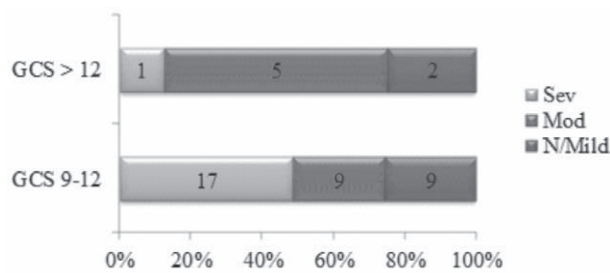


Fig 5: GCS Vs Hypoperfusion

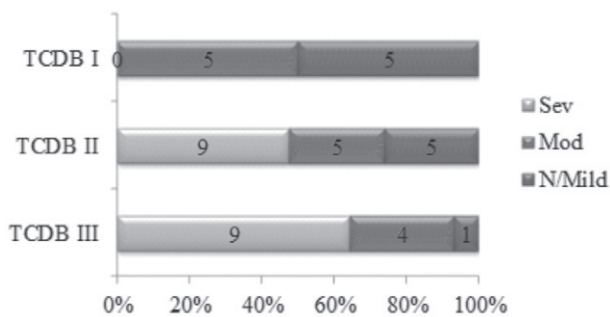


Fig 6: CT category Vs Hypoperfusion

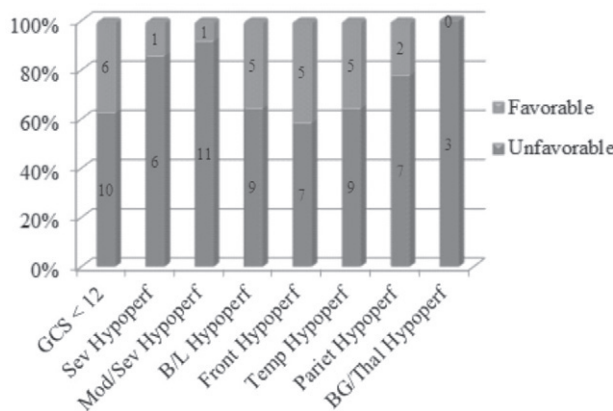


Fig 7: Factors Vs Outcome (Univariate analysis)

other factors had no significant relationship with outcome. In multivariate analysis using binary logistic regression, severe hypoperfusion was found to have significant effect on outcome independent of GCS, CT category and timing of SPECT (P = 0.02) (Fig 8 & 9).

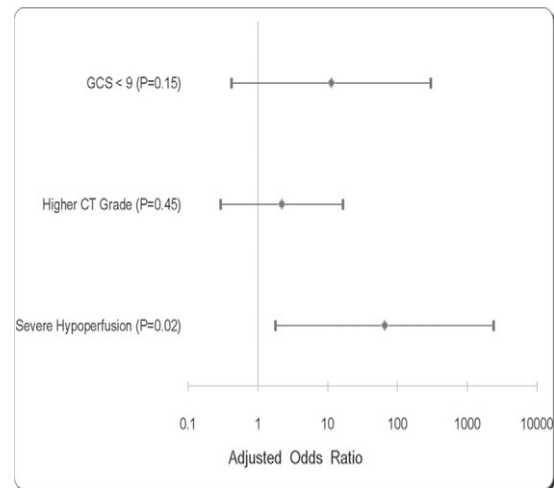


Fig 8: Logistic regression (Multivariate analysis)

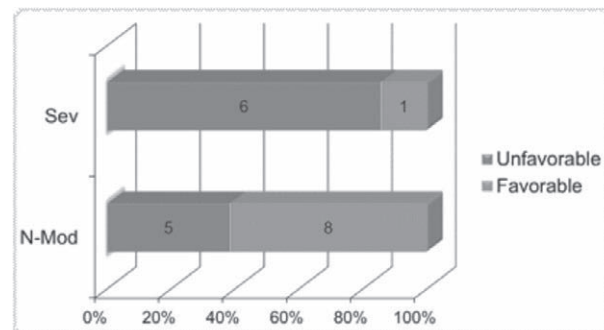


Fig 9: Severe Hypoperfusion Vs Outcome

DISCUSSION

Head injury is a significant cause of morbidity. The actual prevalence of chronic sequelae is virtually unknown in any society due to imprecise information gathering, lack of recognition of late developing neurological and endocrinological symptoms, and not recognizing the true range of traumatic brain-injury related dysfunctions⁹. Thus it has been rightly labelled as 'Silent epidemic'^{10,11}. Rough estimates place the mortality rate due to brain injury at the global level to be 97/100,000 population per year¹². In India, it is the seventh-leading cause of mortality contributing to 11% of total deaths; 78% of cases are due to road traffic injuries alone¹³.

Graham et al noted ischemic brain damage in 91% of patients dying of head injury.² Up to one third of patients who receive only emergency room care are considered to experience persisting symptoms¹⁴⁻¹⁵, and as many as 15% of patients who have mild head injury have been reported to have disabling symptoms a year later¹⁶.

CT is of value in demonstrating large acute haematomas after head injury, and MRI is more sensitive in showing smaller traumatic Lesions¹⁷⁻¹⁹. Early studies indicated that SPECT reveals areas of cerebral damage, which may be either contusional or ischaemic, frequently not shown by CT or MRI. Defects on SPECT may correlate with focal neurological deficit. The most disabled patients tend to show the most number of lesions on SPECT²⁰. Although CT and MRI have been useful in prognosis by providing data on damage associated with poor prognosis (e.g., hematomas, diffuse axonal injury), SPECT's detection of cerebral functioning may be more useful in anticipating the course of the eventual clinical deficit^{21,22}.

The extent of acute SPECT changes seems to correlate with the clinical severity of the posttraumatic syndrome²³. SPECT brain perfusion studies have been playing an important role in understanding the patho-physiology, medical and socioeconomic decision-making involving mild traumatic brain injury patients (MTBI)²⁴⁻²⁸. While SPECT imaging cannot replace traditional structural imaging modalities for identifying major lesions, hematomas, or edema, brain SPECT may play important role in assessing cortical, basal ganglia, and thalamic perfusion alterations resulting from trauma. There are reports that disturbances in affect, behaviour, and cognition, which are often present after head injury, are associated with SPECT abnormalities²⁹⁻³⁰. SPECT has proven to be useful in predicting particular symptoms (e.g., headaches) and permanent damage following some types of brain trauma³¹.

Hofman and co-workers concluded that although 77% of patients of mild TBI revealed lesions in SPECT or MRI there was a weak correlation between neuroimaging findings and neurocognitive outcome³². Also although on some occasions the presence of lesions on SPECT, MRI, or both can help to explain a poor clinical outcome, it is not necessarily an indication of poor outcome³³.

With more evidences and studies comparing SPECT with CT and MRI, it is now been considered that

SPECT, with better sensitivity for detection of cerebral perfusion abnormalities, can complement CT in initial diagnostic evaluation of abnormal areas of the brain following mild to moderate traumatic brain injury. It is particularly useful in patients having PTA, LOC, or PCS with normal anatomic imaging³⁴. In our study severe hypoperfusion in SPECT was associated with unfavourable neurological outcome independent of other confounding factors in patients with mild to moderate head injury.

Also SPECT study can potentially identify patients who can benefit from either CPP based therapy or Lund therapy. Patients with evidence of significant hypoperfusion are likely to benefit from CPP based therapy, while those with edema and no hypoperfusion may benefit from Lund therapy.

CONCLUSION

Traumatic brain injury is a disease with significant presence in society and not all aspects of its pathophysiology are well understood. The prognostication of traumatic brain injury is an unsolved quest particularly more in mild to moderate head injuries. SPECT study can help us in better prognostication of mild to moderate head injuries and may also help us in guiding the treatment on case to case basis.

REFERENCES

1. Tagliaferri F, Compagnone C, Korsic M, Servadei F, Kraus J. A systematic review of brain injury epidemiology in Europe. *Acta Neurochirurgica* 2006; 148:255-68.
2. Graham DI, Adams JH, Doyle D. Ischaemic brain damage in fatal non-missile head injuries. *J Neurol Sci* 1978; 39:213-34.
3. Zwany Metting, Lars A Rödiger, Jacques De Keyser, Joukje van der Naalt. Structural and functional neuroimaging in mild-to-moderate head injury. *Lancet Neurol* 2007; 6:699-710.
4. Devous MD. Single-photon emission computed tomography in neurotherapeutics. *NeuroRx* 2005; 2:237-49.
5. Masdeu JC, Arbizu J. Brain single photon emission computed tomography: Technological aspects and clinical applications. *Semin Neurol* 2008; 28:423-34.
6. Abdel-Dayem HM, Abu-Judeh H, Kumar M et al. SPECT brain perfusion abnormalities in mild or moderate traumatic brain injury. *Clin Nucl Med* 1998; 23:309-17.

7. Marshall LF, Marshall SB, Klauber MR. A new classification of head injury based on computerized tomography. *J Neurosurg* 1991; 75(Suppl): S14-S20.
8. Jennett B, Bond M. Assessment of outcome after severe brain damage: a practical scale. *Lancet* 1975; 1:480-4.
9. Parker RS. Enhancing information gathering after mild head injury in the acute and chronic phase. *J Neurol Ortho Med Surg* 1995; 16:118-25.
10. Goldstein M. Traumatic brain injury: A silent epidemic. *Ann Neurol* 1990; 27:327.
11. Parker RS. Enhancing information gathering after mild head injury in the acute and chronic phase. *J Neurolog Ortho Med Surg* 1995; 16:118-25.
12. World Health Organization. Injury: a leading cause of the global burden of disease. Geneva: World Health Organization; 1999.
13. World Health Organization. The world health report 1999: making a difference. Geneva: World Health Organization; 1999.
14. Kraus JF, McArthur DL, Silberman TA. Epidemiology of mild brain injury. *Sem Neurol* 1994; 14:1-7.
15. Rimel RW, Giordani B, Barth JT, Boll TJ, Jane JA. Disability caused by minor head injury. *Neurosurgery* 1981; 9:221-8.
16. Alexander MP. Mild traumatic brain injury: Pathophysiology, natural history, and clinical management. *Neurology* 1995; 45:1253-60.
17. Gentry LR, Godersky JC, Thompson B, Dunn VD. Prospective comparative study of intermediate-field MR and CT in the evaluation of closed head trauma. *AJR* 1988; 150:673-82.
18. Jenkins A, Teasdale G, Hadley MD, Macpherson P, Rowan JO. Brain lesions detected by magnetic resonance imaging in mild and severe head injuries. *Lancet* 1986; ii:445-6.
19. Gandy SE, Snow RB, Zimmerman RD, Deck MD. Cranial nuclear magnetic resonance imaging in head trauma. *Ann Neurol* 1984; 16:254-7.
20. Newton MR, Greenwood RJ, Britton KE, et al. A study comparing SPECT with CT and MRI after closed head injury. *J Neurol Neurosurg Psychiat* 1992; 55:92-4.
21. Bavetta S, Nimmon CC, White J, et al. A prospective study comparing SPET with MRI and CT as prognostic indicators following severe closed head injury. *Nucl Med Comm* 1994; 15:961-8.
22. Jennett B, Teasdale G, Braakman R, Minderhoud J, Heiden J, Kurze T. Prognosis of patients with severe head injury. *Neurosurgery* 1979; 4: 283-9.
23. Lee B, Newberg A. Neuroimaging in traumatic brain imaging. *NeuroRx* 2005; 2:372-83.
24. Abu Judeh HH, Parker R, Singh M, et al. SPET Brain perfusion imaging in mild traumatic brain injury without loss of consciousness and normal computed tomography. *Nucl Med Comm* 1999; 20:505-10.
25. Crooks DA. The pathological concept of diffuse axonal injury: Its pathogenesis and the assessment of severity. *J Path* 1991; 165:5-10.
26. Hekmatpanah J, Hekmatpanah CR. Microvascular alterations following cerebral contusion in rats. *J Neurosurg* 1985; 62:888-97.
27. Mathew RJ. Sympathetic control of cerebral circulation: Relevance to psychiatry. *Biological Psychiatry* 1995; 37:283-5.
28. Batjer HH, Giller CA, Koopitnik TA, et al. Intracranial and cervical vascular injuries. In: Cooper PR ed.: Head injury, 3rd ed. Baltimore: Williams & Wilkins, 1993; 373-403.
29. Oder W, Goldenberg G, Spatt J, Podreka I, Binder H, Deecke L. Behavioural and psychosocial sequelae of severe closed head injury and regional cerebral blood flow: a SPECT study. *J Neurol Neurosurg Psychiat* 1992; 55:475-80.
30. Goldenberg G, Oder W, Spatt J, Podreka I. Cerebral correlates of disturbed executive function and memory in survivors of severe closed head injury: a SPECT study. *J Neurol Neurosurg Psychiat* 1992; 55:362-8.
31. Reid RH, Gulenchyn KY, Ballinger JR, Ventureyra ECG. Cerebral perfusion imaging with Technetium- 99m HMPAO following cerebral trauma: Initial experience. *Clin Nucl Med* 1990; 15:383-8.
32. Paul AM, Hofman, Sven Z, Stapert, Marinus JPG van Kroonenburgh, et al. MR Imaging, Single-photon Emission CT, and neurocognitive performance after mild traumatic brain injury. *AJNR Am J Neuroradiol* 2001; 22:441-9.
33. Mitchener A, Wyper DJ, Patterson J, et al. SPECT, CT, and MRI in head injury: Acute abnormalities followed up at six months. *J Neurol Neurosurg Psychiat* 1997; 62:633-6.
34. Gowda NK, Agrawal D, Bal C, et al. Technetium Tc-99m Ethyl Cysteinate Dimer Brain Single-Photon Emission CT in Mild Traumatic Brain Injury: A Prospective Study. *AJNR Am J Neuroradiol* 2006; 27:447- 51.