

## Brain abscess complicating hemorrhagic contusion in a case of closed head injury: Case report

Abrar A Wani M Ch, Altaf U Ramzan M Ch, Nayil K Malik M Ch, Ashish Kumar MS, Anil Dhar MS, Furqan A Nizami MS, Sarabjit S Chibber M Ch, MA Wani M Ch  
Department of Neurosurgery, Sher-i- Kashmir Institute of Medical Sciences, Srinagar, (J&K) India.

**Abstract:** Brain contusions commonly are identified in patients with traumatic brain injury (TBI) and represent regions of primary neuronal and vascular injury. These edematous lesions contain punctate parenchymal hemorrhages, which are termed micro-hemorrhages. These hemorrhages rarely get infected by hematogenous spread of microorganisms causing a brain abscess. Delayed brain abscess formation in the contusion is a very rare entity. We report a one year old patient who had traumatic right parietal hemorrhagic contusion with no external wound. She was managed conservatively. Two weeks after injury he deteriorated in neurological status and was found to have developed brain abscess. Patient underwent immediate craniotomy with drainage of abscess and excision of abscess wall; she was discharged home after one week. Infective complication can occur rarely even after closed head injury and should be kept as a differential diagnosis in a patient with delayed deterioration.

**Keywords:** brain abscess; hemorrhagic contusion

### INTRODUCTION

Traumatic brain abscesses are the result of penetrating wounds of the brain, the abscess developing in a zone of necrosis caused by implanted foreign bodies or bone chips<sup>1</sup>. Non-traumatic brain abscess is mostly due to hematogenous spread from a distant focus of infection<sup>2</sup>. Absence of a clear source of infection is reported in as many as 40% of cases<sup>3</sup>. Brain abscess following hemorrhagic contusion in a case of closed head injury is rare and so far only one case has been reported<sup>4</sup>. Our patient developed the abscess in hemorrhagic contusion after having non penetrating trauma to head without any identifiable focus of infection.

### CASE REPORT

A one year old girl presented with history of road traffic accident followed by vomiting and loss of consciousness. There was no history of nasal or ear bleed. On examination, Glasgow coma score (GCS) was 13/15 (E3V4M6) and pupils were equal and reacting. There was no evidence of any external injury. CT head was showing a right parietal elevated skull fracture with underlying hemorrhagic contusion without any mass effect (Figure 1). She was managed conservatively with

anti-epileptics and anti-edema measures and discharged home on sixth post injury day with GCS 15/15.

Four months after injury, she was readmitted with history of sudden onset of vomiting and convulsions, followed by loss of consciousness. On examination, GCS was 9/15 (E2V2M5) and pupils were anisocoric. CT head showed well defined ring enhancing lesion (abscess) in the region of previous contusion (Figure 2) with hydrocephalus. Immediately she underwent right parietal

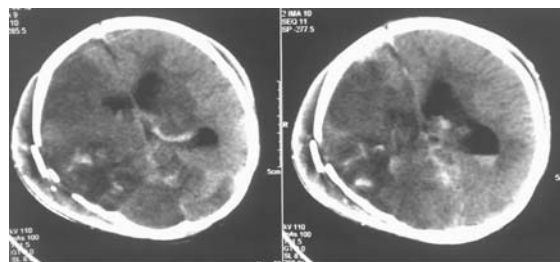


Fig 1: CT scan showing right fronto parietal elevated fracture with underlying contusion

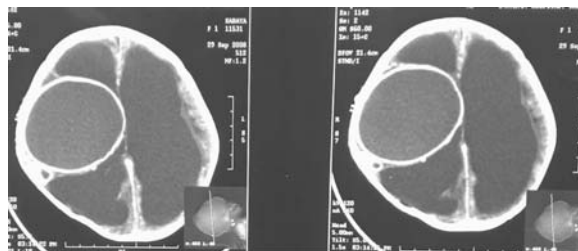


Fig 2: Well defined capsulated abscess seen in right fronto parietal location in the region of previous contusion

*Address for correspondence:*

Dr. Abrar Ahad Wani – Assistant Professor  
Department of Neurosurgery  
Sher-i- Kashmir Institute of Medical Sciences  
Soura, Srinagar, J&K. India E-mail: abrarwani@rediffmail.com

craniotomy and excision of abscess along with external ventricular drain (EVD). Pus culture sensitivity reported growth of *Staphylococcus* sensitive to vancomycin. She received appropriate antibiotics based on culture sensitivity. No source of infection could be revealed in history or clinical examination. After one week EVD was removed and ventriculoperitoneal shunt was put in once CSF cultures were sterile twice. The patient responded well & was discharged home on eighth post operative day.

## DISCUSSION

Focal brain injury includes contusions and hematomas. In brain contusion, there is subpial extravasation of blood and swelling of the affected area. If the lesion is severe, the brain area may be necrotic, soft, and hemorrhagic<sup>5</sup>. Ischemia may play a role in the pathogenesis of contusions<sup>6</sup>.

Single contusions are located either below or opposite the region of impact. On CT scan the contusions appear as heterogeneous areas of brain necrosis, hemorrhage, & infarct representing mixed density lesions<sup>7</sup>. Multiple focal contusions have a “salt and pepper” appearance on CT.

A prerequisite to abscess formation is an area of necrosis which is then seeded by bacteria<sup>8,9</sup>. A brain abscess is initiated when microorganisms are introduced into cerebral tissues as a result of trauma, contiguous infection, or hematogenous dissemination. Although source of infection is frequently apparent, the definitive cause remains obscure in 10 to 37 percent of patients<sup>10</sup>. Suppurative processes of the paranasal sinuses, middle ear and mastoid are the most common sources of underlying infections<sup>11,12,13,14</sup>. Intact brain is quite resistant to infection. However disruption of the blood-brain barrier caused by hemorrhage or infarction may predispose the affected brain tissue to infection and thus abscess formation. Advances in neurosurgical techniques and antibiotic treatment have greatly reduced the mortality of brain abscess to as low as 4% to 9.7%<sup>15,16</sup>. In our patient trauma disrupted the blood brain barrier & predisposed the underlying brain contusion to get infected from some occult source of infection leading to abscess formation within the territory of contused brain only.

## CONCLUSION

Knowledge of possible risk of transformation of a traumatic cerebral hematoma into an abscess with delayed clinical deterioration and without any identified focus of infection may lead to better management of head trauma patients.

## REFERENCES

1. Kasamo S, Asakura T, Kusumotok, et al. Transorbital penetrating brain injury. *No Shinkei Geka* 1992; 20:433.
2. Moorthy RK, Rajshekhar V. Management of brain abscess: An overview. *Neurosurg Focus* 2008; 24:3-9.
3. Dashti SR, Baharvahdat H, Sauvageau E, Chang SW, Stiefel MF, Park MS, et al. Brain abscess formation at the site of intracerebral hemorrhage secondary to central nervous system vasculitis. *Neurosurg Focus* 2008; 24:12-6.
4. Thomas SG, Moorthy RK, Rajshekhar V. Brain abscess in a non-penetrating traumatic intracerebral hematoma: Case report and review of literature. *Neurology India* 2009; 57:73-5.
5. Lee MZ, Muizelaar JP. Clinical pathophysiology of traumatic brain injury. *Youmans Neurological Surgery* 2006; 5 (4):5041-2.
6. Schroder ML, Muizelaar JP, Bullock MR, et al. Focal ischemia due to traumatic contusions documented by stable xenon-CT and ultrastructural studies. *J Neurosurg* 1995; 82:966-71.
7. Zimmerman RA, Bilaniuk LT, Dolinskas C, et al: Computed tomography of acute intracerebral hemorrhagic contusion. *J Comput Assist Tomogr* 1977; 1:271-9.
8. Wood JH, Doppman JL, Lightfoote WE II, et al. Role of vascular proliferation on angiographic appearance and encapsulation of experimental, traumatic and metastatic brain abscesses. *J Neurosurg* 1978; 48:264-73.
9. Wood JH, Lightfoote WE II, Ommaya AK. Cerebral abscesses produced by bacterial implantation & septic embolisation in primates. *J Neurol Neurosurg Psychiat* 1979; 42:63-9.
10. Britt RH. Brain abscess. In Wilkins RH, Rengachary SS (Eds): *Neurosurgery*. New York: McGraw-Hill, 1985, pp 1928-56.
11. Beller AJ, Sahar A, Prais I. Brain abscess: review of 89 cases over a period of 30 years. *J Neurol Neurosurg Psychiat* 1973; 36:757-68.
12. Garfield J. Management of supratentorial intracranial abscess: a review of 200 cases. *Br Med J* 1969; 2:7-11.
13. Morgan H, Wood MW, Murphey F. Experience with 88 consecutive cases of brain abscess. *J Neurosurg* 1973; 38:698-704.
14. Samson DS, Clark K. A current review of brain abscess. *Am J Med* 1973; 54:201-10.
15. Manpalam TJ, Rosenblum ML. Trends in the management of bacterial brain abscesses: a review of 102 cases over 17 years. *Neurosurgery* 1988; 23:451-8.
16. Yang SY, Zhao CS. Review of 140 patients with brain abscess. *Surg Neurol* 1993; 39:290-6.