



ELSEVIER

# Journal of Coloproctology

www.jcol.org.br



## Original article

# Anatomical and physiological changes in pelvic diaphragm in patients with chagasic megacolon submitted to Duhamel surgery

Hélio Moreira Júnior, José P. T. Moreira, Raniere R. Isaac,  
Arminda C. de Almeida, Hélio Moreira, Wilmar A. Klug

Hospital das Clínicas da Universidade Federal de Goiás (UFGO), Goiânia, GO, Brazil

### ARTICLE INFO

#### Article history:

Received 12 February 2013

Accepted 20 April 2013

#### Keywords:

Chagas disease

Megacolon/surgery

Intestinal constipation

Anal canal

Surgical procedures of the digestive system

Perioperative care

Evaluation

### ABSTRACT

*Original contribution:* understand the reasons why Duhamel surgery results in clinical improvement of constipation in patients with Chagasic colopathy.

*Background:* Duhamel surgery is one of the most widespread techniques for the treatment of Chagasic megacolon, with low rates of recurrence of constipation.

*Objective:* evaluate the anatomical and physiological changes in the pelvic diaphragm of patients with chagasic colopathy, as well as changes occurring after undergoing Duhamel surgery. *Design:* clinical data and results of cindefecography, electromanometry and anorectal ultrasound of the anal canal were evaluated in patients with Chagasic colopathy, before and after Duhamel surgery.

*Location:* Service of Coloproctology – Department of Surgery, Faculdade de Medicina da Universidade Federal de Goiás. *Patients:* patients with positive serology for Chagas Disease, with constipation and radiological megacolon, who presented consecutively to the Chagas outpatient clinic and freely agreed to participate in this study, were prospectively included. *Results:* a total of 20 patients were included, with a mean age of 53.2 years, of which 16 were women. The following parameters were observed in the postoperative period: change in bowel frequency, of, on average, one evacuation every ten days to daily bowel movement; 16 patients used laxatives preoperatively and only one did, intermittently, in postoperative period. Electromanometry showed, postoperatively, a decrease in anal resting pressure (60.88 to 37.2 mmHg  $p < 0.001$ ) and anal squeeze pressures (244.3 mL to 161.25  $p = 0.01$ ), whereas ultrasound showed that 75% of the patients had abnormalities of the internal anal sphincter in the posterior anal canal juxtaposed to the pulled-through colon. Postoperative rectal emptying observed in cindefecographic tests occurred more quickly and with less effort when compared with the preoperative findings. There was a change in the anorectal angle postoperatively, which became more obtuse, both during rest, straining and during evacuation.

*Conclusions:* the anatomical and functional changes in the pelvic diaphragm are significant after Duhamel surgery and together, they result in clinical improvement of patients.

© 2013 Elsevier Editora Ltda. Este é um artigo Open Access sob a licença de [CC BY-NC-ND](#)

\* Corresponding author.

E-mail: drhmjr@gmail.com (H. Moreira-Júnior)

## Avaliação das alterações anatômicas e funcionais do diafragma pélvico de pacientes portadores de colopatia chagásica submetidos à cirurgia de Duhamel

### R E S U M O

#### Palavras-chave:

Doença de Chagas  
Megacolon/cirurgia  
Constipação intestinal  
Canal anal  
Procedimentos cirúrgicos do sistema digestório  
Cuidados peri-operatórios  
Avaliação

*Contribuição original:* compreender os motivos pelos quais a cirurgia de Duhamel resulta na melhora clínica da obstipação intestinal de pacientes com colopatia chagásica.

*Antecedentes:* a cirurgia de Duhamel é uma das técnicas mais difundidas para o tratamento do megacólon chagásico, com baixos índices de recidiva dos sintomas de obstipação intestinal. *Objetivo:* avaliar as alterações anatômicas e fisiológicas do diafragma pélvico de pacientes portadores de colopatia chagásica e as mudanças ocorridas após serem submetidos à cirurgia de Duhamel.

*Desenho do estudo:* foram avaliados os dados clínicos e os resultados de exames de cinedefecografia, eletromanometria anorretal e o ultrassom do canal anal de pacientes portadores de colopatia chagásica, no pré e pós-operatório da cirurgia de Duhamel.

*Localização:* Serviço de Coloproctologia – Departamento de Cirurgia Faculdade de Medicina da Universidade Federal de Goiás.

*Pacientes:* foram incluídos, prospectivamente, pacientes com sorologia positiva para Doença de Chagas, com obstipação intestinal e megacólon radiológico, que se apresentaram consecutivamente ao ambulatório de Chagas e que livremente aceitaram participar desse estudo.

*Resultados:* foram incluídos 20 pacientes, com média de idade de 53,2 anos, sendo 16 mulheres. Observou-se, no pós-operatório, uma mudança do ritmo intestinal de, em média, uma evacuação a cada dez dias para uma evacuação diária; 16 pacientes faziam uso de laxantes no pré-operatório e somente um o fazia, intermitentemente, no pós-operatório. A eletromanometria evidenciou, no pós-operatório, uma diminuição das pressões anais de repouso (60,88 para 37,2 mmHg com  $p < 0,001$ ), e da capacidade retal (244,3 para 161,25 mL,  $p = 0,01$ ) e o ultrassom revelou que em 75% dos pacientes haviam alterações anatômicas do esfíncter interno na porção posterior do canal anal, justaposto ao local de abaixamento do cólon. O esvaziamento da ampola retal, observado durante a cinedefecografia pós-operatória, se processou mais rapidamente e com menor esforço quando comparado com os achados pré-operatórios. Houve mudança do ângulo anorretal no pós-operatório, que se tornou mais obtuso, tanto durante o repouso como durante o esforço evacuatório.

*Conclusões:* as alterações anatômicas e funcionais do diafragma pélvico são significativas após a cirurgia de Duhamel e que ela determina, em conjunto, a melhoria clínica dos pacientes.

© 2013 Elsevier Editora Ltda. Este é um artigo Open Access sob a licença de [CC BY-NC-ND](https://creativecommons.org/licenses/by-nc-nd/4.0/)

## Introduction

It is estimated that there are between 70 and 90 million people worldwide at risk of being infected by Chagas disease.<sup>1</sup> Recently, there was a significant increase in the number of individuals infected by *Trypanosoma cruzi* in developed countries such as United States (USA), Japan, Canada and Spain.<sup>2</sup> There are approximately 300,000 individuals with Chagas disease in the United States,<sup>3</sup> therefore, it constitutes a new challenge to be faced by health authorities in these countries.

Surgical treatment of chagasic megacolon is indicated when there is progression and worsening of symptoms of constipation or progression to complicated forms of the disease, such as sigmoid volvulus or fecal impaction. A wide variety of surgical techniques has been described for the treatment of chagasic megacolon; many of them were based on prevalent physiopathological concepts of the disease whenever they were described and others have been abandoned because they had high rates of recurrence

of constipation or high rates of postoperative complications.<sup>4-13</sup>

Bernardes et al. (1965) employed for the first time the Duhamel technique in the treatment of chagasic megacolon,<sup>14</sup> using the proposed method made by this french surgeon for the treatment of congenital megacolon.<sup>15</sup> This technique was latter modified by Haddad et al.<sup>16</sup>

The Service of Coloproctology, of Universidade Federal de Goiás, has used Duhamel surgery as a routine technique for the treatment of chagasic megacolon since 1966, with some of the various modifications that have been incorporated over the years.<sup>17-22</sup> Despite of good surgical results, to date there has been no detailed study that explained what anatomo-physiological changes result from this operation, which would be, in the end, responsible for the functional improvement of the patients.

## Aim

Evaluate the anatomical and physiological changes observed in the pelvic diaphragm of patients with Cha-

gas colopathy after undergoing Duhamel surgery, using cinedefecography, electromanometry and anal ultrasound for the evaluation.

---

## Materials and methods

### Type and location of study

The study was developed at the Service of Coloproctology of the Department of Surgery, Hospital das Clínicas da Universidade Federal de Goiás.

### Ethical aspects

The study was performed in accordance with the Declaration of Helsinki and local regulations. The project was approved by the Research Ethics Committee (Hospital das Clínicas, Universidade Federal de Goiás). All patients enrolled in this study were informed on the purpose of the tests performed and signed a free and informed consent form.

### Patients and Eligibility

A total of 20 patients with the following characteristics were prospectively selected from May 2006 to June 2008:

- positive serology for Chagas disease in at least one serological test;
- chronic constipation, defined as frequency of bowel movements of less than twice a week; and
- barium enema showing megacolon and/or anorectal electromanometry demonstrating achalasia of the internal anal sphincter.

All patients underwent Duhamel-Haddad surgery and were submitted to cinedefecography, electromanometry and anal canal ultrasound preoperatively and at the third month after surgery. Patients also answered a specific questionnaire to assess demographic data, the presence and severity of constipation, association with other clinical forms of Chagas disease functional status at these two distinct moments. The continence was assessed using Jorge and Wexner incontinence score,<sup>23</sup> ranging from 0 to 20, with 0 being perfect continence. The classification of chagasic megaesophagus described in the study is based on radiological findings of these segment, with patients being assigned to groups I, II, III and IV, in which I is the least advanced.<sup>28</sup> The classification of sigmoidocele and/or enterocele used in our material was described by Jorge et al.,<sup>29</sup> and only grade 3 cases were considered clinically significant, i.e., the ones that reaches below the ischiococcygeal line.

### Statistical analysis

Consensual statistic analysis show that a homogeneous sample of 20 patients with Chagas colopathy evaluated at two different times, by the same tests, in which control and post-treatment cases corresponded to the same group of

patients are adequate to evaluate anatomic and physiologic changes after Duhamel surgery.

The comparison of qualitative variables observed in the pre- and postoperative periods was performed by McNemar test. Quantitative variables were assessed using Student's t-test for paired samples or Wilcoxon test. The significance level was set at 5%.

---

## Results

A total of 20 patients with Chagas colopathy were included in the study. The mean age of patients was  $53.2 \pm 11.2$  years. Seventy-five percent of cases were females. The mean time of symptom onset was 16 years. The mean time without a bowel movement was 10.3 days. Sixteen patients routinely used laxatives. Fourteen patients complained of abdominal pain and distension, 17 of sensation of incomplete evacuation, and seven had a history of fecal impaction. One case had a sigmoid volvulus and was treated by endoscopic distortion. Half of patients had Chagasic heart disease and seven patients presented with chagasic megaesophagus (five in group II and two in group III). Five patients had all three clinical forms of the disease (colopathy, esophagopathy and Chagas cardiopathy). Three patients had symptoms of anal incontinence and, in two cases, incontinence was related to gas, at a rate of one episode every 15 days (incontinence score = 2). Another patient complained involuntary lost of liquid stool (speccially after using enemas) and gas, every 20 days and solid stools every 30 days (incontinence score = 5). Symptoms did not interfere with patient daily activities in any of these cases.

The postoperative bowel movement was a median of one daily bowel movement, ranging from three times a day to once every four days. Only one patient used laxatives, intermittently (once every 15 days on average). Two patients had persistent abdominal pain and distension, but with less intensity and frequency. Seven patients reported incomplete evacuation, being necessary to evacuate at least twice, the second almost immediately after the first evacuation.

There were no cases of fecal impaction or sigmoid volvulus postoperatively. Among the seven patients with chagasic megaesophagus, four reported dysphagia improvement after surgical treatment of megacolon. Four patients had symptoms of anal incontinence after surgery, and three of these patients already had symptoms preoperatively.

There was a worsening of anal incontinence in two of these patients, who reported incontinence to gas almost daily and rarely for liquid stools (incontinence score = 5). The other patient reported that incontinence to gas became a weekly event (incontinence score = 3). The third patient, who had a preoperative incontinence score of 5, reported symptom improvement after discontinuing the use of enemas and also reported having involuntary escape of gas daily, with no loss of liquid or formed stools (incontinence score = 4). No patient reported that symptoms of anal incontinence interfered with their usual daily activities.

Ultrasonography of the anal canal showed to be normal in 90% of patients preoperatively, (except two female patients who had lesions of the external sphincter, at the anterior portion of the middle third of the anal canal). After surgery, it

showed abnormalities in 75% of patients. Three patients had complete injuries, with or without fibrotic tissue surrounding the internal sphincter at the posterior hemicircumference of the anal canal, juxtaposed to the pulled-through colon (Fig. 1A) and another 12 patients had partial lesions of the sphincter with or without scar tissue, at the posterior hemicircumference of the anal canal (Fig. 1B). Only five patients showed an intact sphincter anatomy. There were no significant changes at the perineal body thickness of female patients (mean 13.04 preoperatively to 12.6 mm postoperatively).

Cinedefecography showed, preoperatively, prolonged opening of the anal canal despite of an adequate relaxation of the puborectalis during evacuation in 95% of patients (Table 1). Eight female patients had rectocele. However, only two were considered clinically significant (greater than 3 cm and partially emptied after evacuation). Four patients had sigmoidocele (grades 1 and 2), but these findings did not cause obstruction of rectal contents during evacuation. One patient had partial relaxation of the puborectalis.

Static perineal descent was diagnosed in 35% of patients; 10% had associated static and dynamic perineal descent and 15% had dynamic descent, exclusively. Eighty-five percent of the patients had, preoperatively, a sensation of incomplete evacuation despite of a prolonged straining (Table 2). Objective data with their respective means and standard deviations

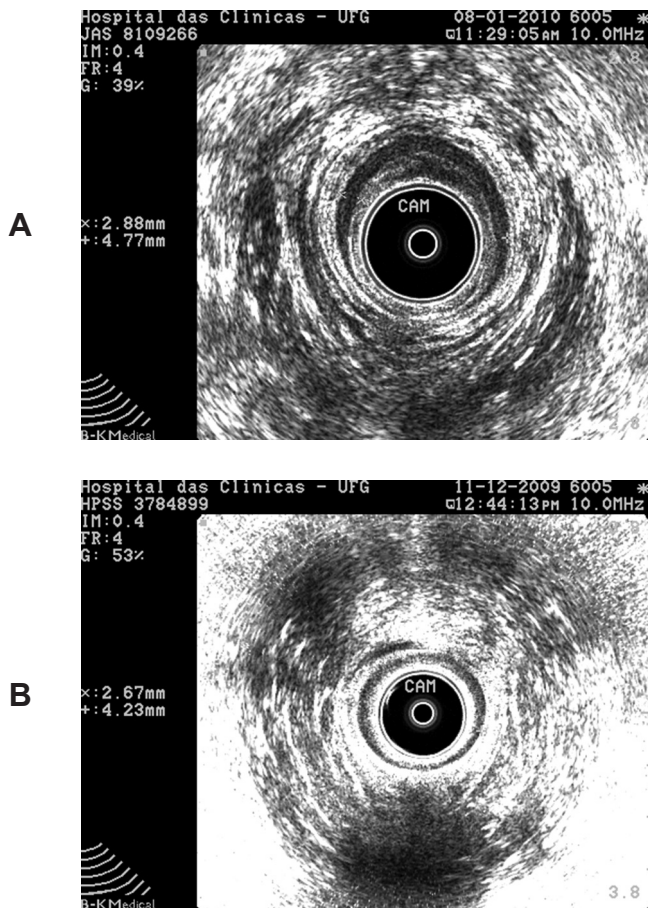
observed at the cinedefecography preoperatively are summarized in Table 3.

Rectal emptying in postoperative cinedefecography occurred faster and with less effort when compared with preoperative findings (Table 1). The funnel-shaped image in the proximal portion of the anal canal during straining persisted in only two patients; however it did not determined any symptoms (both had daily stool frequency postoperatively, without effort).

Two out of eight patients who had preoperative rectocele were not diagnosed with the same problem postoperatively. Rectocele remained clinically significant postoperatively in the same two patients diagnosed before (Fig. 2). Both persisted with symptoms of incomplete evacuation, one of which eventually used digital maneuvers to have a successful bowel movement, both pre and postoperatively.

Four patients had sigmoidocele, three grade 1 and one grade 2, but these findings did not cause outlet obstruction. Postoperative mean static and dynamic perineal descent decreased, when compared with values observed preoperatively. However, the difference between these two moments was only statistically significant for the static descent (Table 3).

Four patients postoperatively showed incomplete evacuation, two of them with significant rectocele. One patient had



**Fig. 1 – Partial lesion (A) and thinning (B) of the internal anal sphincter at the posterior hemicircumference of the anal canal, juxtaposed to the pulled-through colon in different patients who underwent Duhamel surgery.**

**Table 1 – Observation of the prolonged opening of the anal canal in patients with Chagas colopathy, evaluated before and after Duhamel surgery.**

		Prolonged opening of the anal canal in the postoperative period		Total
		Yes	No	
Prolonged opening of the anal canal in the preoperative period	Yes n (%)	3 (15)	16 (80)	19 (95)
	No n (%)	0 (0)	1 (5)	1 (5)
Total n (%)		3 (15)	17 (85)	20 (100)

p < 0.001

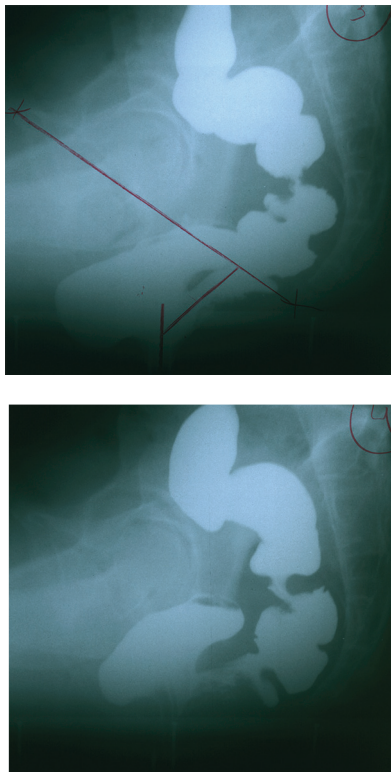
**Table 2 – Observation of the sensation of incomplete evacuation in patients with Chagas colopathy, evaluated before and after Duhamel surgery.**

		Sensation of incomplete evacuation in the postoperative period		Total
		Yes	No	
Sensation of incomplete evacuation in the preoperative period	Yes n (%)	3 (15)	14 (70)	17 (85)
	No n (%)	2 (10)	1 (5)	3 (15)
Total n (%)		5 (25)	15 (75)	20 (100)

p < 0.004

**Table 3 – Anorectal and coloanal angles, static and dynamic perineal descents observed on cinedefecography in the pre and postoperative period of patients with chagasic colopathy who underwent Duhamel surgery.**

Variable	Moment of assessment	Mean	Standard deviation	Minimum	Median	Maximum	p
Anorectal angle at rest	pre-op	103.3	20.5	58	103	135	< 0.001
	post-op	136.6	12.1	110	137.5	160	
Coloanal angle at rest	post-op	103.3	20.1	62	100	143	0.975
Anorectal angle at squeeze	pre-op	81	21.5	42	76.5	120	< 0.001
	post-op	120	11.4	95	121	145	
Coloanal angle at squeeze	post-op	84.7	19.7	51	80	135	0.411
Anorectal angle at evacuation	pre-op	119	16.1	94	119	145	< 0.001
	post-op	141	15.9	100	140.5	170	
Coloanal angle at evacuation	post-op	125.7	22.1	90	125	165	0.091
Static perineal descent	pre-op	6.7	4.9	1.8	5.7	19.5	0.031
	post-op	4.4	2.3	2	3.5	11	
Dynamic perineal descent	pre-op	2.8	2.1	0	3	6	0.389
	post-op	2.3	2.2	0	1.75	8	



**Fig. 2 – Radiographs of patients with Chagas colopathy, after Duhamel surgery, during evacuation straining and after evacuation, respectively. Note the presence of an incomplete emptied bulky anterior rectocele at the two distinct moments, with a partial emptied rectocele.**

partial relaxation of the puborectalis muscle during straining. Another patient, despite the presence of residual contrast in the rectal stump, did not complain of a sensation of incomplete evacuation.

There was a significant change in the anorectal angle postoperatively which became more obtuse, both during resting and evacuation (Table 3). The same was not observed when we compared the anorectal angle preoperatively with the angle formed between the pulled-through colon and the anal canal.

Postoperatively, the anorectal electromanometry showed a decrease in the mean resting and squeeze pressure of the anal canal of 60.88 mmHg to 37.2 mmHg ( $p < 0.01$ ), and 146.56 mmHg to 122.2 mmHg ( $p < 0.004$ ). The mean length of the functional anal canal did not change when compared pre- and postoperatively (2.15 to 2.05 cm, respectively,  $p = 0.608$ ). The postoperative mean rectal capacity decreased from 244 mL to 161 mL ( $p = 0.01$ ) (Table 4).

## Discussion

Chronic constipation is the main clinical manifestation of Chagasic colopathy, which worsens progressively and become resistant to conservative medical treatment. The disease pathogenesis were identified by Habr-Gama et al.,<sup>26,27</sup> as two basic functional changes that could explain the onset of constipation, both resulting from the destruction of Meissner and Auerbach intestinal plexus: achalasia of the internal anal sphincter and colonic motor incoordination of the colon.

Cavenaghi et al.,<sup>28</sup> in a series of 39 patients with Chagasic megacolon, described that the rectoanal inhibitory reflex (RAIR) is not always evident in patients with Chagas disease due to the use of insufficient volumes of air insufflation in the rectum during eletromanometric test. The authors observed that the RAIR was present in 43% of studied cases, with a mean volume of 196 mL. Other authors have shown that, in normal subjects, intrarectal balloon inflation with up to two thirds of the rectal threshold volume was enough to demonstrate RAIR.<sup>29,30</sup> In our study, we decreased the possibility of false negative RAIR considering that rectal sensory threshold might be equivocal as it relies on patient's information. The mean volume used to evaluate the reflex was 80 mL. These values are below those reported by Cavenaghi et al.,<sup>28</sup> and may be due to different methodological approach used in our service. We think that eliciting RAIR with very high intrarectal volume does not consubstantiate a normal physiological state, and may, as reported by Fang et al.,<sup>31</sup> be an electromanometric evidence of the opening of the anal canal caused by significant increase of intrarectal pressure other than a normal RAIR.

The reason why a large number of surgical techniques has been proposed for the treatment of Chagasic megacolon may

**Table 4 – Electromanometric assessments, performed pre- and postoperatively in patients with Chagas colopathy submitted to Duhamel surgery.**

Anorectal electromanometry variable	Moment of assessment	Mean	Standard deviation	Minimum	Median	Maximum	p
Resting pressures (mmHg)	pre-op	60.88	22	26.66	59	101.87	< 0.001
	post-op	37.2	10.75	21.9	36.67	66.46	
Contraction pressures (mmHg)	pre-op	146.56	50.7	61	144.82	245	< 0.004
	post-op	122.2	42	56.7	120.94	211	
Functional anal canal (cm)	pre-op	2.15	0.68	1	2	4	0.608
	post-op	2.05	0.51	1	2	3	
Rectal sensitivity (mL)	pre-op	34.75	18.88	10	34.5	80	0.229
	post-op	30.25	10.19	15	30	50	
Rectal capacity (mL)	pre-op	244.3	179.12	90	175	660	0.011
	post-op	161.25	83.53	55	130	360	

be due to the lack of better knowledge on the functional effects of surgery on these patient. The most appropriate surgery would be the one that, at least in part, addresses the described physiopathological changes for chagasic megacolon, with acceptable of morbidity and mortality rates.

The postoperative functional results of Duhamel surgery in the middle and long term are quite satisfactory, with exceptional risk of recurrence of constipation.<sup>32,33,34</sup> Even in patients who complain of postoperative constipation, the severity of symptoms is much lower when compared to the preoperative state. However, there is a risk with post-operative anal incontinence. In most cases, these symptoms are more common in the immediate postoperative period and improve over time.

Nevertheless, a minority of patients may have refractory symptoms of anal incontinence, which might impact their quality of life. In the present study, the functional results were satisfactory with significant improvement of constipation in all studied cases. The surgery resulted in the onset of subtle postoperative anal incontinence in only three cases, without interfering on their social or work activities. However, it should be noted that these results were postoperatively evaluated after a short period of time.

The mechanisms for such good functional outcome after Duhamel surgery were, until now, partially understood. Several studies have shown that achalasia of the internal anal sphincter persists after Duhamel surgery. Moreira<sup>35</sup> observed that motor incoordination between the pulled-through colon and rectal stump is restored to a similar normal pattern as the contraction of the pulled-through colon is followed by rectal relaxation. It is speculated that this return to normal motor patterns between the colon and rectum would occur due to a side-to-side other than an end-to-end anastomosis of these two segments.

However, other anatomofunctional aspects resulting from the surgery could influence postoperative results. Our results demonstrate that patients with chagasic megacolon, after undergoing Duhamel surgery, presented a decrease resting pressure of the anal canal and rectal capacity, as well as an improvement in rectal sensory threshold. These electromanometry findings are similar to those observed by Moreira JPT.<sup>36</sup> Ultrasound of the anal canal provides an explanation for these functional changes, as approximately 60% of patients after surgery, showed reduced thickness of the internal sphincter and 15% had complete lesion of this muscle in the poste-

rior circumference of the anal canal; only 25% had an intact sphincter anatomy.

Fang et al.<sup>31</sup> evaluated 29 patients with advanced Chagasic megacolon through cinedefecography and detected a prolonged time for evacuation when compared with asymptomatic individuals.

These cinedefecography findings were similar to those observed in our study. Despite of an adequate relaxation of the puborectalis muscle during straining, the anal canal was not adequately opened, obstructing rectal emptying. Only after a considerable increase of intra-abdominal pressure that rectal contrast was eliminated, confirming Fang et al.<sup>31</sup> theory that evacuation only occurs due to a difference of intrarectal pressure vs. resting pressure of the anal canal. At maximum stage of pushing, a funnel shape image was noted in the upper portion of the anorectal ring, which represents the dynamic display of the internal anal sphincter achalasia.

Furthermore, we observed, in the pre-operative period of female patients other mechanisms that corroborated with constipation, especially larger than 4 cm rectoceles which did not emptied after straining. These bulky rectoceles determined postoperative sensation of incomplete evacuation, and need for digital maneuvers to successfully achieve a complete empty rectum.

It is noteworthy in this study, the change in the anorectal displacement that occurred after Duhamel surgery. The pulled-through colon on the retrorectal space shifted forward the rectal stump axis, originating an obtuser anorectal angle. It is known that after this surgery, bowel transit includes the rectal stump as the last segment to store the fecal content.<sup>37</sup> Therefore an obtuser anorectal angle between the anal canal and the rectal stump becomes a facilitating mechanism for evacuation in the postoperative period of patients undergoing Duhamel surgery.

We can therefore summarize that the anatomophysiological changes determined by Duhamel surgery addresses the physiopathological changes of Chagasic colopathy, includes:

- 1) Low latero-lateral anastomosis between pulled-through colon and rectal stump. Study published by Moreira H.<sup>35</sup> showed that after Duhamel surgery, the pulled-through colon and rectal stump start once again to show propulsive motor coordination, i.e., the contraction of the colon wall is accompanied by rectal wall relaxation. This phenomenon facilitates the progression of colonic contents into the rectal stump.

- 2) The resting pressure of the anal canal decreases after surgery as a consequence of partial damage or thinning of the internal anal sphincter, associated with fibrotic process, at the posterior hemicircumference of the anal canal, where the colon was pulled-through. This electromanometric finding has important implications for rectal emptying as the intrarectal pressure needed to overcome internal anal sphincter achalasia will be reduced.
- 3) Postoperative cinedefecographic assessments showed that as the rectal stump is laid up with contrast, the anastomotic angle between the rectal stump and the pulled-through colon moves posteriorly and works as a valvular mechanism that precludes retrograde transit during the effort for evacuation, enhancing intrarectal pressure. Therefore, an effortless evacuation is achieved as a more efficient rise of intrarectal pressure is expected. For a few other patients, the rectal stump and pulled-through colonic contrast were emptied at the same moment.
- 4) A retrorectal, endoanal space is created to pull-through the colon. Consequently, the axis of the remaining rectal stump is shifted anteriorly, determining an obtuse anorectal angle. During straining, there is an almost complete rectification (close to 180°) between the axis of the anal canal and the remaining rectal stump, facilitating the emptying of the rectum.

This study provides a better understanding of why there are good functional results in the postoperative period of patients with Chagasic megacolon who underwent Duhamel surgery. New knowledge can determine other technical variations for different subgroups of patients with megacolon, in order to further improve postoperative results. We can, for instance, re-evaluate the use of this technique in patients who already have deteriorated sphincter function preoperatively, those with a large megarectum, or even in patients who have other conditions causing outlet obstruction in association to chagasic megacolon, such as rectocele and anismus.

## Conclusions

Anal sphincter pressure in the pre-operative time measured by eletromanometry is within normal limits; there is a significant decrease in resting and squeeze pressures of the anal canal after Duhamel surgery, as well as a decreased capacity and increased rectal sensitivity.

Ultrasound of the anal canal, postoperatively, detected partial or total lesion of the internal anal sphincter muscle, such as perimuscular fibrosis, in 75% of cases, always at the posterior hemicircumference of the anal canal, where the colon was pulled-through.

Postoperative cinedefecography confirmed a significant improvement in rectal emptying during straining. A significant change in the anorectal angle was also observed at rest and during straining (which became, postoperatively, more obtuse).

Secondary factors in the genesis of constipation may be present in some patients with Chagasic colopathy (rectocele, perineal descent and anismus).

Significant anatomical and functional changes were identified by anorectal eletromanometry, anal ultrasound

and cinedefecography in patients who underwent Duhamel surgery for chagasic megacolon, which ultimately resulted in clinical improvement.

## Conflict of interest

The authors declare no conflicts of interest.

## REFERENCES

1. Coura JR, Dias JCP. Epidemiology, control and surveillance of Chagas disease: 100 years after its discovery. *Memórias do Instituto Oswaldo Cruz* 2009; 104: 31-40.
2. Parker ER, Sethi A. Chagas disease: coming to a place near you. *Dermatol Clin*, v. 29, n. 1, p. 53-62, Jan 2011.
3. Bern C, Montgomery SP. An estimate of the burden of Chagas disease in the United States. *Clin Infect Dis* 2009;49:e52-4.
4. Almeida AD. Sigmoidectomy abdominal no tratamento do megacolo. *Rev Paul Med* 1963; 62: 349-60.
5. Capelhuchnik P, Silva Prado W. Hemicolectomia esquerda no tratamento do megacolon-resultado em 57 casos. In: Congresso da International Society of University Colon and Rectal Surgeons [Anais] São Paulo; 1970.
6. Cardoso AA. Modificação na técnica de anastomose colon-retal na cirurgia do megacolon chagásico. *Rev Bras Cir* 1963; 15:16-22.
7. Celso NM. Tratamento do megacolo adquirido pela anorretomiectomia. *Rev Assoc Med Minas Gerais* 1962;13:139-46.
8. Cutait DE. Megacolo. Nova técnica de retossigmoidectomia abdômino-perineal sem colostomia. In: 1º Congresso Latino-Americano, 11º Internacional e 10º Brasileiro de Proctologia [Anais]. São Paulo. 1960; 2:831-46.
9. Ferreira-Santos R, Carril CF. Megacolon chagásico – Análise de 36 casos tratados cirurgicamente. 1º Congresso Latino Americano, 2º Internacional e 10º Brasileiro de Proctologia [Anais] São Paulo. 1960; 2:863-5.
10. Paula Pinto E. Tratamento cirúrgico do megacolon adquirido. 1º Congresso Latino Americano, 2º Internacional e 10º Brasileiro de Proctologia. [Anais] São Paulo 1960; 1:294-5.
11. Simonsen O, Habr-Gama A, Gazal P. Retossigmoidectomia endoanal com ressecção da mucosa retal. *Rev Paul Med* 1960; 57:116-7.
12. Vasconcelos E. Nova técnica de abaixamento do colon sem suturas, no megacolon. *Rev Hosp Clin Fac Med São Paulo* 1961; 16:355-62.
13. Vasconcelos E. Colectomia sub-total e anastomose ceco-retal no tratamento do megacolon do adulto. *Rev Hosp Clin Fac Med São Paulo* 1964; 19:332-7.
14. Bernardes de Oliveira A, Oliveira C, Goldenberg S. A anastomose ano-reto-cólica no tratamento cirúrgico do megacolon (operação de Duhamel). *An Paul Med Cir* 1965; 89:45-61; 83-94; 103-18.
15. Duhamel B. Une nouvelle operation pour le megacolon congenital: L'abaissement retro-rectal et trans-anal du colon et son application possible au traitement de quelques autres malformations. *Presse Med* 1956; 64:2249-50.
16. Haddad J, Raia A, Corrêa-Neto A. Abaixamento retro-retal do colon com colostomia perineal no tratamento do megacolon adquirido. *Rev Assoc Med Bras* 1965; 11:83-8.
17. Sebba F. Tratamento cirúrgico do megacolon chagásico pela operação Duhamel, com contribuição de nova conduta cirúrgica no volvo da sigmóide. [Tese – Livre Docência]. Goiânia: Faculdade de Medicina da Universidade Federal de Goiás; 1971.
18. Moreira H. Tratamento do megacolon chagásico pela técnica de Duhamel-Haddad. Experiência pessoal. *Arq Gastroenterol* 1971; 8:185-90.

19. Moreira H. Megacólon chagásico. In: Speranzini M, Ramos M. Manual do residente de cirurgia. 2ª. ed. Rio de Janeiro: Guanabara-Koogan; 1981. p.286-92.
20. Moreira H. Tratamento cirúrgico do megacolo chagásico pela técnica de Duhamel-Haddad. Aspectos técnicos. In: Pinotti HW. Atualização cirúrgica. São Paulo: Robe; 1982. v. 7, p.161-82.
21. Lins Neto MAF. Operação de Duhamel modificada com anastomose colorretal imediata para o tratamento do megacólon chagásico. [Tese - Mestrado]. São Paulo: Faculdade de Medicina da Universidade de São Paulo; 1997.
22. Moreira H, Moreira JPT, Moreira Jr H. Avaliação crítica do tratamento cirúrgico de megacólon chagásico. Castro LP, Savassi-Rocha PR, Lacerda Filho A, Conceição AS, (Eds) Tópicos em Gastroenterologia 11 - Avanços em coloproctologia. Rio de Janeiro: Medsi; 2001. p.403-13.
23. Jorge JMN, Wexner SD. Etiology and management of fecal incontinence. *Disease of Colon and Rectum* 1993; 36: 77-97.
24. Rezende JM, Lauer KM, Oliveira AR. Aspectos clínicos e radiológicos da aperistalsis do esôfago. *Rev Bras Gastroenterol* 1960;12:2473/462.
25. Jorge JMN, Yang YK, Wexner SD. Incidence and clinical significance of sigmoidoceles as determined by a new classification system. *Dis Colon Rectum* 1994; 37:1112-7.
26. Habr-Gama A. Motilidade do cólon sigmóide e do reto. Contribuição à fisiopatologia do megacólon chagásico. [Tese - Doutorado]. São Paulo: Faculdade de Medicina da Universidade de São Paulo; 1966.
27. Habr-Gama A, Costa Curta L, Raia A. Anatomia e fisiologia do esfíncter interno do ânus. *Rev Soc Bras Proctol.* 1970; 3:21-30.
28. Cavenaghi S, Felício OC, Ronchi LS, Cunrath GS, Melo MM, Netinho JG. Prevalence of rectoanal inhibitory reflex in chagasic megacolon. *Arq Gastroenterol.* 2008; 45:128-31.
29. Collier JA. Clinical application of anorrectal manometry. *Gastroenterol Clin North Am.* 1987; 16:17-33.
30. Stein BL, Roberts PL. Manometry and the rectoanal inhibitory reflex. In: Wexner SD, Bartolo DCC. (Eds). *Constipation: Etiology, evaluation and management.* Oxford: Butterworth Heineman; 1995. p 63-76.
31. Fang CB, Klug WA, Aguida HASC, Ortiz JÁ, Capelhunik P. Avaliação das pressões anais em doentes com o megacólon chagásico. *Rev Bras Colo-Proctol.* 1998; 18:173-7.
32. Moreira H, Rezende JM, Sebba F, Azevedo IF, Leite ACA, Soares EP. Chagasic megacólon. *Coloproctology.* 1985; 5:260-6.
33. Moreira H, Rezende JM. Megacólon chagásico: clínica, diagnóstico e tratamento. In: Moreira H. (Ed.) *Coloproctologia: conceitos.* Goiânia: Escaleno; 1993. p.15-60.
34. Moreira H. Megacólon chagásico. In: Cordeiro F, Meneghelli U, Resende JM (Eds). *Federação Brasileira de Gastroenterologia. A gastroenterologia no Brasil: subsídios para sua história até o ano 2000.* Rio de Janeiro: Revinter; 2001. p.377-407.
35. Moreira H. Estudo eletromanométrico da atividade motora do coto retal e do cólon descendente em pacientes chagásicos submetidos às cirurgias de Hartmann e de Duhamel. [Tese - Mestrado]. Goiânia: Faculdade de Medicina da Universidade Federal de Goiás; 1972.
36. Moreira JPT. Avaliação eletromanométrica no pré e no pós operatório de pacientes portadores de megacolon chagásico submetidos à cirurgia de Duhamel. [Tese - Mestrado] Goiânia: Instituto de Patologia Tropical -Universidade Federal de Goiás; 2001.
37. Almeida AC. Resultados funcionais da operação de Duhamel-Haddad no tratamento do megacólon chagásico. [Tese - Mestrado] Goiânia: Faculdade de Medicina da Universidade Federal de Goiás; 1996.