



Journal of Coloproctology

www.jcol.org.br



Original article

Two-year experience in laparoscopic colorectal surgery in a healthcare service in Salvador: a critical analysis

Carlos Ramon Silveira Mendes^{a,b,*}, Luciano Santana de Miranda Ferreira^a,
Ricardo Aguiar Sapucaia^a, Meyline Andrade Lima^a

^aService of Coloproctology, Hospital Santa Izabel, Salvador, BA, Brazil

^bBrazilian Society of Coloproctology, Rio de Janeiro, RJ, Brazil

ARTICLE INFO

Article history:

Received 2 March 2013

Accepted 12 May 2013

Keywords:

Laparoscopic colorectal surgery

Colectomy

Laparoscopy

ABSTRACT

Introduction: laparoscopic colorectal surgery has become a viable access route since the beginning of 1990, using Jacobs' technique. Its outcomes are decrease in hospitalization length, early return to routine activities, better esthetic results and less postoperative pain. **Objective:** to report a series of patients treated by a team using videolaparoscopic access route in colorectal surgery.

Material and methods: retrospective, descriptive study carried out in Salvador, state of Bahia, Brazil, from April of 2010 to May 2012.

Results: a total of 81 procedures were analyzed; 59.3% of cases were females, mean age was 58.3 years. Benign illness was treated in 48.1% to the patients. Rectosigmoidectomy was carried out in 41.5% and right colectomy in 21%. Intraoperative complications were observed in 3.7% and postoperative in 21% of cases, with a conversion rate of 6.2%.

Conclusion: the laparoscopic procedure showed to be safe and the surgeon's training results in better outcomes in this series.

© 2013 Elsevier Editora Ltda. Este é um artigo Open Access sob a licença de [CC BY-NC-ND](#)

Dois anos em cirurgia colorretal videolaparoscópica em um serviço em Salvador: uma análise crítica

RESUMO

Introdução: a cirurgia videolaparoscópica colorretal tem se tornado uma opção de acesso viável, desde o início de 1990, por Jacobs. Tem-se obtido redução dos dias de internação, retorno precoce às atividades, melhor resultado estético e menos dor pós-operatória.

Objetivo: relatar a casuística de uma equipe utilizando o acesso videolaparoscópico.

Materiais e métodos: estudo retrospectivo, descritivo realizado em Salvador, de abril de 2010 a maio de 2012.

Resultados: 81 procedimentos foram analisados, com 59,3% do sexo feminino, média de idade de 58,3 anos. Foi tratada doença benigna em 48,1% dos pacientes. A retossigmoidectomia foi realizada em 40,7%, e a colectomia direita em 21%. Das complicações encontradas, 3,7% foram transoperatórias e 21% pós-operatórias com uma taxa de conversão de 6,2%.

Palavras-chave:

Cirurgia laparoscópica colorretal

Colectomia

Laparoscopia

* Corresponding author.

E-mail: proctoramom@hotmail.com (C.R.S. Mendes)

Conclusão: o procedimento videolaparoscópico tem-se mostrado seguro, e a capacitação do cirurgião tem trazido melhores resultados na casuística.

© 2013 Elsevier Editora Ltda. Este é um artigo Open Access sob a licença de CC BY-NC-ND

Introduction

Since 1990, when the first laparoscopic colon surgical procedures started to be performed by Moises Jacobs,¹ the viability of this access route has been demonstrated. In 1992, Regadas et al.² started to perform this type of intervention in Brazil. The good results with decreased hospitalization length, earlier return to normal activities, better esthetic results and less postoperative pain also increased the number of laparoscopic resections.

Literature data have shown results similar to those of conventional colectomy in the treatment of colorectal cancer.^{3,4,9,19} The learning of this technique requires good training of the surgeon concerning the operative technique and the instruments to be used.^{5,6,7,8} Currently, few data are reported in the literature regarding laparoscopic colorectal surgery performed in the state of Bahia, Brazil.

Objective

Our aim was to demonstrate and analyze the initial series of a surgical team using laparoscopic access in the treatment of colorectal diseases for a period of two years.

Material and methods

The present was a retrospective, descriptive study carried out in Hospital Santa Izabel, in the city of Salvador, state of Bahia, Brazil, after assessing the database of a healthcare team from April 2010 to May 2012. We included all patients submitted to laparoscopic colorectal surgery in this period.

The variables studied were age, gender, length of hospitalization, procedure performed, type of condition treated, complications and causes of conversion. Data were collected and analyzed using the statistical package SPSS for Windows, release 17.0.

Results

A total of 81 laparoscopic colorectal procedures were performed, of which 59.3% (48) in female patients and 40.7% (33) in males (Fig. 1). The mean age of patients was 58.2 years old (1-88 years). The mean length of hospitalization was 5.78 days, ranging between 1 and 31 days. The Brazilian Unified Health System (SUS) paid for the procedures in 17.3% of cases, whereas 82.7% of them were covered by health insurance companies.

The laparoscopic approach was used to treat 48.1% of patients with benign diseases. Of the diseases treated, 19.8% corresponded to diverticular disease, 2.5% to rectal prolapse, 3.7% to megacolon and 14.8% to colonic polyposis. Malignant

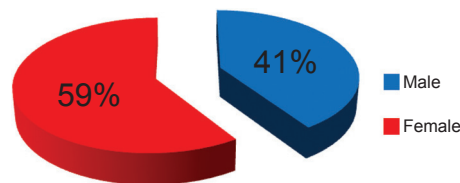


Fig. 1 – Distribution by gender.

diseases were seen in 51.9% of cases, being distributed by site: 18.5% were located in the rectum, 7.4% in the sigmoid colon, 6.2% in the cecum and descending colon, 1.2% in the anal canal and synchronous disease and 2.5% in the ascending colon, whereas the transverse colon showed 8.6% of neoplasms (Fig. 2).

Of the procedures performed, 40.7% underwent a recto-sigmoidectomy, followed by right colectomy in 21%, total colectomy in 9.9%, left colectomy in 7.4%, Milles' surgery in 4.9%, transversectomy in 3.7%, Duhamel surgery in 4.9%, total proctocolectomy in 1.2%, sacral promontofixation and reconstruction of intestinal transit accounted for 2.5% each, according to Fig. 3.

Complications were divided into intraoperative and postoperative ones, comprising a total of 24.7% of cases, of which 21% were postoperative and 3.7%, intraoperative. Intraoperatively, there was an opening of the bladder wall, due to advanced cecum malignancy, which was repaired by simple suture and a small bowel lesion due to adhesion of the ileum to a rectal neoplasm.

The postoperative complications included an, anastomotic dehiscence (3.7%) in a patient submitted to a right colectomy for cancer of the cecum that had Crohn's disease, on the third postoperative day with reoperation and reinforcement of the suture. Another dehiscence occurred after a total colectomy with a side to side ileorectal anastomosis after total colectomy. Two patients (2.5%) had intra-abdominal abscess, which were managed through interventional radiology procedure with percutaneous drainage. Respiratory

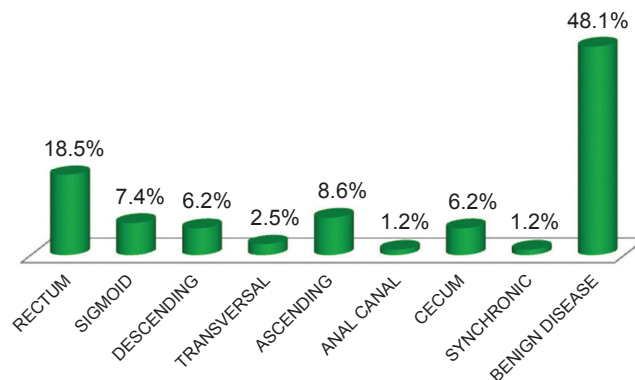


Fig. 2 – Tumor location.

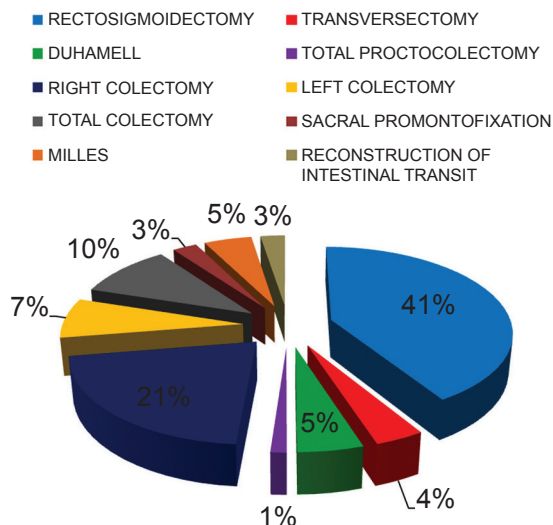


Fig. 3 – Procedure performed.

infection and ileus were present in 6.2% and 7.4% respectively, and a case of postoperative pulmonary embolism was reported (1.2%) (Fig. 4).

There were five cases (6.2%) of conversion in this series, four due to peritoneal adhesions and 1 (1.2%) due to CO₂ retention in the beginning of the surgical procedure, which was immediately converted.

There were two deaths (2.4%), one due to an episode of bronchoaspiration on the third postoperative day with respiratory failure and the second due to respiratory infection that progressed to multiple-organ and system dysfunction.

Discussion

The laparoscopic colorectal surgery can be performed on all patients, regardless of age and/or sex. Published studies have shown benefits. Most publications involve patients with benign disease, which accounted for 48.1% of cases in our initial series. Patients undergoing cancer treatment accounted for 51.9%. All oncological steps were maintained, such as artery ligation at its origin, surgical specimen extraction with abdominal wall protection and fixation of trocars. Regarding the literature, the work by Queiroz et al.¹⁰ showed that 42.5% of patients undergoing surgery in the state of Minas Gerais had malignancies. The predominance of the female gender was observed in all assessed studies.

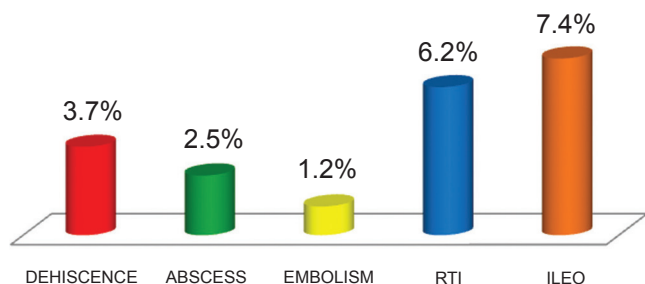


Fig. 4 – Postoperative complications.

There are many benefits of colorectal surgery and, among them the number of hospitalization days, which was 4.3, as shown by Regadas et al.,⁵ very similar to our series.

As for the procedures performed, Campos et al., in a national survey, reported that rectosigmoidectomy was the one most often performed, in 40.7% of cases, similar to our study (40.7%), followed by right colectomy in 8%, which was higher in our series (21%).

The complications reported in the literature vary from 8% to 29.6%, as shown by Campos et al. and Regadas et al.^{7,5} Our study showed 24.7% of complications, of which 3.7% were intraoperative, whereas literature shows a rate of 5.1 to 14%.⁵

When analyzing the post-operative complications, the difference between the assessed publications becomes evident, ranging from 14.7% reported by Bennett et al.,¹¹ to 29.6%, as reported in the national survey in 2001. In the initial series of 102 cases by Regadas et al.,¹² this rate was close to 24.5%, very similar to ours, of 21%. However, a new survey by the same author, with 401 cases,⁵ showed a decrease in this rate to 17%, which demonstrates the reduction in complications with sample size increase.

The mortality rate described in the literature ranges from 0% to 5% and it was 2.4% in our series. Of the two deaths reported in our study, one was a patient with chronic obstructive pulmonary disease (COPD) that had an episode of vomiting on the third postoperative day, with aspiration and progression to respiratory failure. The second case was also a smoker that had CO₂ retention at the start of pneumoperitoneum, which progressed to respiratory failure and death. The conversion ratio was 6.2%, whereas the literature has shown rates of 6% as reported by Lumlet et al.,¹³ 7.9% by Boulez et al.¹⁴ and 9% by Coelho et al.,⁴ being comparable to that shown in the literature.

Conclusion

It can be observed that laparoscopic colorectal procedures were shown to be safe, allowing oncologic resections, shorter hospitalization stay, less postoperative pain and better esthetic results. Both the surgeon's and team's training result in a decrease in complication rates and surgery duration. Further studies with follow-up of this series are needed to complement national series and stimulate new teams to start using the laparoscopic approach in the treatment of colorectal diseases.

Conflict of interest

The authors declare no conflicts of interest.

REFERENCES

- Jacobs M, Verdeja JC, Gosdtein HS. Minimally invasive colon resection (laparoscopic colectomy). *Surg Laparosc Endosc* 1991; 1(3):144-50.
- Regadas FSP, Nicodemo AM, Rodrigues LV, Garcia JHP, Nobrega AGS. Anastomose colorretal por via laparoscópica – apresentação de dois casos e descrição da técnica operatória. *Rev Bras Coloproct* 1992; 12: 21-23.

3. Regadas FSP, Ramos JR, Souza JV, Neto JA, Gama AH, Campos F, et al. Laparoscopic colorectal procedures: a multicenter brazilian experience. *Surg Laparosc Endosc PercutTech* 1993; 9: 295-98.
4. Coelho JCU, Pinho RV, Macedo JJM, Andriguetto PC, Campos ACL. Colectomia laparoscópica: revisão retrospectiva de 120 casos. *Rev Col Bras Cir* 2009; 36(2): 144-147.
5. Regadas FSP, Regadas SMM, Rodrigues LV, Lima D, Regadas Filho FSP. Cirurgia laparoscópica. Experiência com 401 casos. *Rev Bras Videocir* 2005; 3(4): 191-195.
6. Habr Gama A. Análise crítica das intervenções laparoscópicas sobre o colon. In: *Videocirurgia C.B.C. São Paulo. Robe Editorial* 1993: 277-389
7. Campos FG, Souza Jr AH, Carmel APW, Habr-Gama A, et al. Cirurgia laparoscópica colo-retal: resultados do inquérito nacional brasileiro. *Rev Bras Coloproct* 2001; 21(3): 135-143.
8. Araujo SEAR, et al. Conversão em cirurgia laparoscópica colorretal. *Rev Bras Coloproct* 2003; 23(10): 47-52.
9. Campos FG. Perspectiva e vantagens da videocirurgia no tratamento do câncer colo-retal. *Rev Bras Videocir* 2004; 2(1): 39-42.
10. Queiroz Fl, et al. Resultados do Registro de Cirurgias Colorretais videolaparoscópicas realizadas no estado de Minas Gerais – Brasil de 1996-2009. *Rev Bras Coloproct* 2010; 30(1): 61-67.
11. Bennett CL, Stryker SJ, Ferira MR, et al. The learning curve for laparoscopic colorectal surgery. Preliminary results from a prospective analysis of 1194 laparoscopic – assisted colectomies. *Arch Surg* 1997; 132(7): 781.
12. Regadas FSP, Rodrigues LV, Nocodemo AM, Siebra JA. Intervenções colorretais videolaparoscópicas. Experiência de 102 casos. *Rev Bras Coloproct* 1995; 15(3): 110-113.
13. Lumley JW, Fielding GA, Nathanson LK, SIU S, Stitz RW. Laparoscopic assisted colorectal surgery. Lessons learned from 240 consecutive patients. *Dis Colon Rectum* 1996; 39(2): 155-9.
14. Boulez J, Espalineu P, Fontaumard E, Meeus P. Laparoscopic colorectal surgery analysis of 113 cases. *Hepatogastroenterology* 1997; 44(13): 40-4.
15. Shah PR, Joseph A, Haray PN. Laparoscopic colorectal surgery: learning curve and training implications. *Postgrad Med J* 2005; 81: 537-540.
16. Senagore AJ, Delaney CP. A critical analysis of laparoscopic colectomy at a single institution: lessons learned after 1000 cases. *The American J Surg* 2006; 191: 377-380.
17. Reis Neto JA, Quilici FA, Cordeiro F, Pinto OL, Reis Jr JA. Cirurgia videolaparoscópica colorretal. *Rev Bras Coloproct* 1995; 15(2): 58-64.
18. Pedroso AMG, Marubayashi L, Gori R, Pedroso MA, Lupinacci RA. Aspectos relevantes da anestesia na videocirurgia colorretal. *Rev Bras Coloproct* 2007; 27(3): 284-287.
19. Melani AGF, Campos FG. Ressecção laparoscópica pós-terapia neoadjuvante no tratamento do câncer no reto médio e baixo. *Rev Bras Coloproct* 2006; 26(1): 89-96.
20. Souza Jr AHS, Scanavini Neto A, Habr-Gama A. Acesso vídeo-laparoscópico no tratamento cirúrgico da diverticulite aguda. *Rev Bras Coloproct* 2006; 26(3): 341-347.
21. Valarini R, Campos FGCM. Resultados do registro nacional brasileiro em vídeo-cirurgia colorretal - 2007. *Rev Bras Coloproct* 2008; 28(2): 145-155.
22. Souza JVS. Visão atual da cirurgia colorretal laparoscópica. *Rev Bras Coloproct* 1996; 16(3): 151-54.