



Journal of Coloproctology

www.jcol.org.br



Case report

Recurrent aggressive angiomyxoma[☆]

Suelene Suassuna Silvestre de Alencar^{a,b,c,*}, Romualdo da Silva Corrêa^{b,c},
Emanuela Simone Cunha de Menezes^{b,d}, Antonio Luiz do Nascimento^{b,d},
Davi Aragão Alves da Costa^{b,d}, Marcelo José Carlos Alencar^{b,d}

^aDepartament of Integrated Medicine, Universidade Federal do Rio Grande do Norte (UFRN), Natal, RN, Brazil

^bService of Coloproctology, Hospital Universitário Onofre Lopes, Natal, RN, Brazil

^cBrazilian Society of Coloproctology, Rio de Janeiro, RJ, Brazil

^dMedical School, Universidade Federal do Rio Grande do Norte (UFRN), Natal, RN, Brazil

ARTICLE INFO

Article history:

Received 30 May 2013

Accepted 17 August 2013

Keywords:

Pelvic neoplasms

Neoplasms of connective tissues
and soft tissues

Angiomyxoma

Local recurrence of neoplasm

Laparotomy

ABSTRACT

Introduction: aggressive angiomyxoma is a highly aggressive, rare neoplasm of the mesenchymal tissue with a high recurrence rate. It represents an important differential diagnosis of pelvic tumors in women of reproductive age. This study aims to describe a case of aggressive angiomyxoma.

Case report: woman, 37 years old, complained about a bulge on the right perianal region, and anal itching and burning, bleeding, tenesmus and incontinence. The proctologic examination confirmed the perianal bulge and extrinsic compression of the posterior wall of the rectum. Computed tomography (CT) of the pelvis showed a well-defined pelvic mass extending to the right rectal area. Exploratory laparotomy showed a mass of fibro elastic consistency adjacent to the pelvic organs and closely attached to the distal rectum, and performed a resection of the pelvic tumor afterward. Anatomopathological analysis revealed an aggressive angiomyxoma. Magnetic resonance imaging (MRI) of the pelvis showed signs of recurrence in the pelvic cavity on the right side of the rectum. A surgical procedure was performed to resect the lesion. After an asymptomatic period, the MRI showed solid growths located in the right ischiorectal fossa. A new surgical procedure identified only retention cysts in the pelvis and right ischiorectal fossa, only lysis of adhesions was performed. The patient is currently undergoing follow-up without disease recurrence.

© 2013 Elsevier Editora Ltda. Open access under [CC BY-NC-ND license](#).

[☆] Study carried out at Departament of Integrated Medicine da Universidade Federal do Rio Grande do Norte, Natal, RN, Brazil.

* Corresponding author.

E-mail: suelene@ufrnet.br; suelenesuassuna@gmail.com (S.S.S. Alencar)

2237-9363 © 2013 Elsevier Editora Ltda. Open access under [CC BY-NC-ND license](#).

<http://dx.doi.org/10.1016/j.jcol.2013.08.009>

Angiomixoma agressivo recidivante

RESUMO

Palavras-chave:

Neoplasias pélvicas
Neoplasias de tecido conjuntivo e de tecidos moles
Angiomixoma
Recidiva local de neoplasia
Laparotomia

Introdução: o angiomixoma agressivo é uma rara neoplasia do tecido mesenquimal de grande agressividade e alta taxa de recorrência. Representa um importante diagnóstico diferencial de tumorações pélvicas de mulheres em idade reprodutiva. Este estudo objetiva relatar um caso de angiomixoma agressivo.

Relato de caso: mulher, 37 anos, com queixa de abaulamento em região perianal direita, além de prurido e ardor anal, sangramento, tenesmo e incontinência anal. Exame proctológico confirmou o abaulamento perianal e compressão extrínseca da parede posterior do reto. Tomografia computadorizada (TC) de pelve evidenciou massa pélvica bem delimitada estendendo-se à região para-retal direita. Laparotomia exploradora demonstrou massa de consistência fibro-elástica adjacente aos órgãos pélvicos e intimamente aderida ao reto distal, sendo realizada ressecção do tumor pélvico. Anatomopatológico revelou angiomixoma agressivo. Ressonância nuclear magnética (RNM) de pelve demonstrou sinais de recidiva na escavação pélvica à direita do reto. Foi realizado procedimento cirúrgico para ressecção da lesão. Após período assintomática, RNM evidenciou processos expansivos sólidos localizados na fossa ísquio-retal direita. Novo procedimento cirúrgico identificou apenas cistos de retenção na pelve e fossa ísquio-retal direita sendo feita apenas lise de aderências. A paciente encontra-se em seguimento clínico sem recidiva da doença.

© 2013 Elsevier Editora Ltda. Todos os direitos reservados.

Introduction

Aggressive angiomyxoma (AA) is a neoplasm of mesenchymal connective tissue, which affects mainly women (6:1 ratio) of reproductive age, but there have been cases reported in perimenopausal women, men and children.¹

Steeper and Rosai, in 1983, described the histological characteristics and the tendency for local infiltration and recurrence.² The adjective “aggressive” is due to its high recurrence rate and infiltrative power, ranging from 33-72%.^{3,4} To date, AA has approximately 250 cases reported in literature.¹

Considering the rarity of cases of AA described in the literature, this report aims to highlight the recurrent nature of this disease and include it in the differential diagnosis of pelvic tumors, especially in women of reproductive age.

Case report

A 37-year-old female patient reported a bulge in the right perianal region, with progressive and painless growth for the past eight months. She also reported anal itching and burning, bleeding, tenesmus and anal incontinence. The proctologic examination disclosed a bulge in the right perianal region and extrinsic compression of the right lateral posterior rectal wall. Endoanal ultrasonography (USG) revealed a large perineal collection of undefined nature. The computed tomography (CT) revealed a well-defined pelvic mass extending to the right pararectal region (Figs. 1 and 2).

The patient underwent exploratory laparotomy, which revealed a mass of fibroelastic consistency adjacent to the pelvic organs and closely adhered to the distal rectum. Resection of the pelvic tumor and a total hysterectomy were performed

(Fig. 3). The anatomopathological examination revealed an aggressive angiomyxoma and the presence of intrauterine leiomyoma. Immunohistochemical analysis showed spindle cells positive for desmin, vimentin, smooth muscle actin, HHF-35, as well as nuclear positivity for estrogen and progesterone and negative for CD34 and S-100 protein (Figs. 4, 5 and 6).

About one year after the surgery, the proctologic examination revealed a small bulge in the right anterior anal region. Magnetic resonance imaging (MRI) of the pelvis showed signs of recurrence of the expansive process inside the pelvic cavity, right to the rectum, occupying the right ischioanal fossa and confirmed by pelvic CT. A surgical procedure was performed to resect the recurrent lesion through perianal approach.

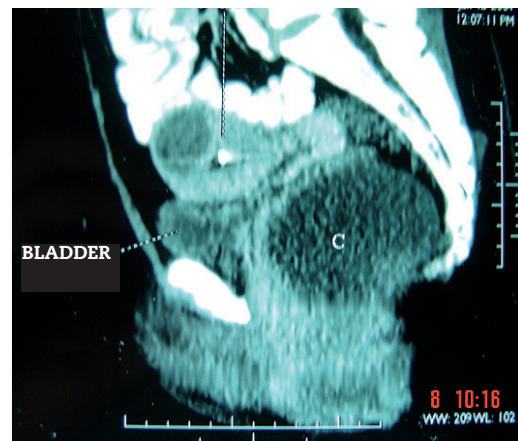

Fig. 1 - Pelvic CT (sagittal view) showing the presence of mass (C) in the pelvic region.

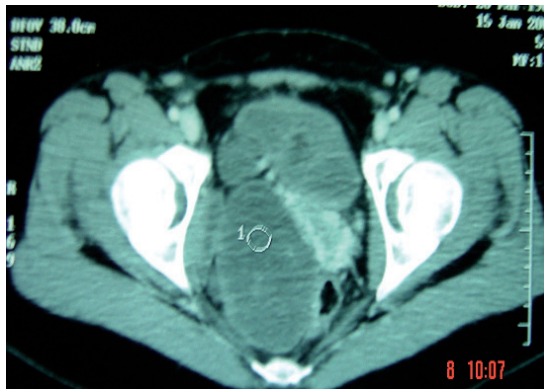


Fig. 2 - Pelvic CT (cross-sectional view) showing the presence of mass (1) in the pelvic region.

At the follow-up, after being asymptomatic for about three and a half years and displaying a normal proctologic examination, the MRI disclosed solid expansive processes located in the right ischio-rectal fossa, adjacent to the left iliac vessels. A third laparotomy was performed and identified only retention cysts in the pelvis and right ischio-rectal fossa, and only lysis of adhesions was performed.

Currently, the patient is in clinical follow-up, with no recurrence of the disease for three years.

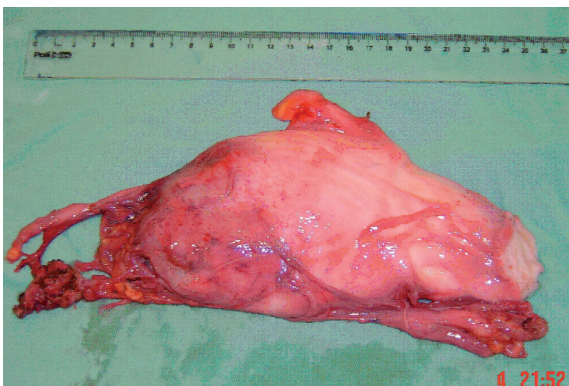


Fig. 3 - Resected pelvic tumor.

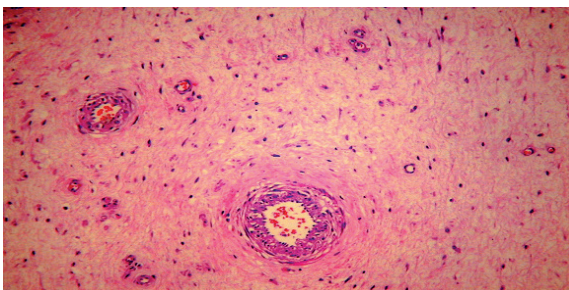


Fig. 4 - HE01 (x20) - Myxoid stroma showing spindle cells and blood vessel proliferation.

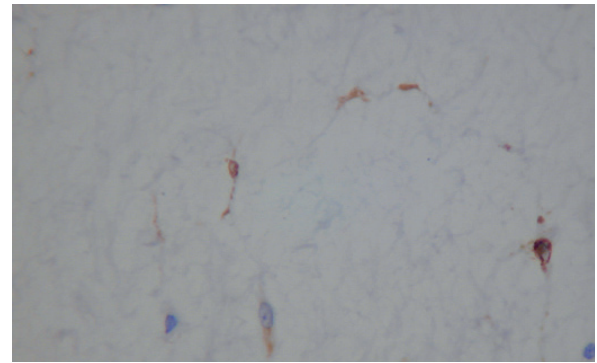


Fig. 5 - Desm06 (x20) Spindle cells positive for desmin.

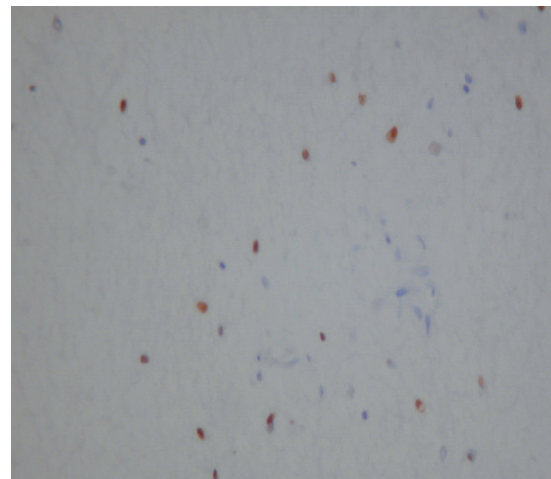


Fig. 6 - PgR05 (x20) - Nuclear positivity for progesterone.

Discussion

Aggressive angiomyxoma (AA) is a rare, slow-growing and invasive myxoid mesenchymal neoplasm. Women of reproductive age are affected in about 90% of cases, predominantly in the pelvic-perineal region, with a peak incidence at the fourth decade of life.^{3,5} It can also occur in menopausal women, in men and in children.²

The clinical presentation of AA is variable. Initially, it may manifest as a perineal or vulvar asymptomatic polyp/nodule, perineal hernia or pelvic mass diagnosed incidentally on imaging assessments.⁵

AA must be diagnosed considering age, clinical evolution, location, imaging assessment and anatomopathological and immunohistochemical evidence.⁶ However, due to the rarity of cases and lack of typical characteristics, the preoperative diagnosis is very difficult, hindering the therapeutic planning.

Thus, most cases are confirmed histopathologically after the primary surgical resection.⁷

Imaging studies are of great importance for the diagnosis of AA. The USG can reveal a polypoid, hypoechoic mass of soft tissue, which may appear as a cyst. At the CT, the characteristics vary and may include a homogeneous well-defined and hypodense mass relative in relation to the muscle, a hypoattenuating solid mass with an internal spiral pattern after intravenous contrast agent or a predominantly cystic mass with solid components. The MNR image is isointense (less commonly hypointense) on T1 and hyperintense on T2 relative to the muscle. After intravenous contrast, a spiral component of lower intensity is seen inside. The recurrent tumor is also detected at the resonance with characteristic signs similar to the primary tumor.^{5,8}

Macroscopically the AA consists of a homogeneous mass, partially or completely encapsulated, with a smooth surface, gelatinous appearance, of bluish gray color and small cysts or hemorrhagic areas can be found.^{1,5}

The histopathological examination shows myxoid stroma, hypocellularity, small spindled and stellate mesenchymal cells with undefined cytoplasm. Pleomorphism and mitoses are not present and there is no evidence of coagulation necrosis in the tumor cells. Characteristically, there is a prominent vascular component with vessels of various calibers.^{5,9}

Immunohistochemical findings show that tumor cells have immunoreactivity for desmin, smooth muscle actin, vimentin and CD34. They can also be positive for estrogen and progesterone. They are immunonegative for S100 proteins, factor VIII, carcinoembryonic antigen and cytokeratin.

Cytogenetic analysis shows chromosomal translocations involving chromosomes 8 and 12, associated with the rearrangement of HNGIC genes.¹⁰

The differential diagnosis of AA is based on other forms of soft tissue tumors (myxoma, myxoid lipoma, neurofibroma) and malignant tumors with metastatic potential (myxoid liposarcoma, myxofibrosarcoma, embryonal rhabdomyosarcoma).⁷ Additionally, it can occasionally mimic Bartholin's cyst, labial cyst, Gartner's duct cyst and perineal herniation.³

Angiomyxomas are locally aggressive tumors, generally not capable of distant metastases, with only two cases reported in the scientific literature.^{1,5}

Because of its high rate of local recurrence, the first line treatment for AA is complete surgical resection through abdominal, perineal or mixed approach, keeping margins free. However, the risk-benefit binomial should be considered, as most tumors occur in women of reproductive age and fertility is a very important factor. In such situations this choice may not be the best option, as in cases of high surgical morbidity.^{1,5,11}

Incomplete lesion resection occurs in 45-66% of cases and is directly associated with the possibility of recurrence, often requiring re-excision, such as the case reported here. In some free margin cases, the chances of recurrence are of 30-70%; the ischioanal fossa is the most frequently affected site.^{1,5}

Due to the low mitotic potential of this neoplasm, chemotherapy and radiotherapy are ineffective in their treatment.⁴ In cases of incomplete resection or recurrence, GnRH agonists can be used.^{3,12}

Conclusion

The present case depicts the characteristics of aggressive angiomyxoma, emphasizing the importance of the inclusion of this disease as a differential diagnosis in cases of locally invasive pelvic masses in women of reproductive age. Imaging tests are very important for the diagnosis of primary or recurrent AA, and immunohistochemical analysis should be considered whenever possible to confirm the diagnosis.

Conflicts of interest

The authors declare no conflicts of interest.

REFERENCES

- Fuentea J, Zapardiela I, Herreroa S, Kazlauskasa SG, Vargasb J, Frutosa LS, et al. Angiomixoma agresivo vulvar. *Prog Obstet Ginecol* 2008; 51(2): p 99 - 103.
- Akbulut M, Demirkan NÇ, Çolakoglu N, Düzcan E. Aggressive angiomyxoma of the vulva: a case report and review of the literature. *Aegean Pathology Journal* 2006; 3: p 1 - 4.
- Danesh A, Sanei MH. Aggressive angiomixoma of the vulva: dramatic response to gonadotropin-releasing hormone agonist therapy. *Journal of research in medical sciences* 2007; 12 (4): 217 - 221.
- Dove S, Remoué P, Valo I, Ybarlucea LR, Panel N, Fondrinier E - Unusual female pelvic tumour: Aggressive angiomixoma. *Letters to the editor/Eur J Obst and Reprod Biol* 2008; 137, (1): 123 - 124.
- Haldar K, Martinek IE, Kehoe S - Aggressive angiomyxoma: a case series and literature review. *Eur J Surg Oncol* 2010; 36(4): p 335 - 339.
- Minagawa T, Matsushita K, Shimada R, Takayama H, Hiraga R, Uehara T, et al. Aggressive angiomyxoma mimicking inguinal hernia in a man. *Int J Clin Oncol* 2009; 14: p 365 - 368.
- Bastian PJ, Fisang C, Schmidt ME, Biermann K, Textor J, Müller SC. Aggressive angiomyxoma of the prostate mimicking benign prostatic hyperplasia. *Eur J Med Res* 2006; 11(4): p 167 - 169.
- Jeyadevan NN, Sohaib SAA, Thomas JM, Jeyarajah A, Shepherd JH, Fisher C. Imaging features of aggressive angiomyxoma. *Clinical Radiology* 2003; 58(2): p 157 - 162.
- Odashiro NA, Odashiro LN, Odashiro DN, Odashiro M, Campos JCP. Angiomixoma agresivo em paciente do sexo masculino acometendo cordão espermático: relato de caso e revisão da literatura. *J Bras Patol Med Lab* 2005; 41(2): p 131 - 134.
- Morar R, Fridman E, Mor Y. Aggressive angiomyxoma of the scrotum mimicking huge hydrocele: case report and literature review. *Case Reports in Medicine* 2009; 2009 (ID 157624).
- Wiser A, Korach J, Gotlieb WH, Fridman E, Apter S, Ben-Baruch G. Importance of accurate preoperative diagnosis in the management of aggressive angiomyxoma: report of three cases and review of the literature. *Abdominal Imaging* 2006; 31(3): p 383 - 386.
- Velasco SM, Burgos AJC, López MR, Poveda IG, Santoyo JS. Resección laparoscópica de angiomixoma pélvico agresivo. *Cirugía española* 2010; 88(2), p 121 - 122.