



Journal of Coloproctology

www.jcol.org.br



Case report

Needle knife-assisted polypectomy in hot snare-resistant fibrotic inflammatory polyps

Xian-rui Wu^a, Xiu-li Liu^b, Bo Shen^{c,*}

^aDepartment of Colorectal Surgery, Cleveland Clinic Foundation, Cleveland, USA

^bDepartment of Anatomic Pathology, Cleveland Clinic Foundation, Cleveland, USA

^cDepartment of Gastroenterology/Hepatology, Cleveland Clinic Foundation, Cleveland, USA

ARTICLE INFO

Article history:

Received 3 January 2014

Accepted 5 February 2014

Keywords:

Hot snare

Inflammatory bowel diseases

Inflammatory polyps

Needle knife

ABSTRACT

Background: Inflammatory polyps are common sequelae in patients with inflammatory bowel diseases (IBD). Those polyps can usually be removed with snare polypectomy. There were limited data evaluating the management of hot snare-resistant inflammatory polyps. **Methods:** We reported on two cases with hot snare-resistant inflammatory polyps, one was a Crohn's disease (CD) patient with the polyp at the ileo-colonic anastomosis (ICA) and the other one was an ulcerative colitis (UC) patient with polyp at the pouch inlet.

Results: Sedated endoscopy was performed, which showed a large 2.5 cm pedunculated polyp at the ICA in the first patient and a large 5 cm pedunculated polyp at the pouch inlet in the second patient. Hot snare polypectomy was initially attempted, but failed in both patients. Then endoscopic needle knife polypectomy was performed, which helped complete polypectomy. Both procedures took approximately 25 minutes each. The patients tolerated the procedure well and continued to do well after the procedure. The final pathological diagnoses for both patients were inflammatory polyps with extensive fibrosis.

Conclusions: Endoscopic needle knife-assisted polypectomy appeared to be an effective technique for the management of hot snare-resistant inflammatory polyps.

© 2014 Sociedade Brasileira de Coloproctologia. Published by Elsevier Editora Ltda.

Este é um artigo Open Access sob a licença de [CC BY-NC-ND](https://creativecommons.org/licenses/by-nc-nd/4.0/)

Polipectomia assistida por bisturi-agulha em pólipos inflamatórios fibróticos resistentes à cauterização por laço

RESUMO

Experiência: Pólipos inflamatórios são sequelas comuns em pacientes com doença intestinal inflamatória (DII). Geralmente esses pólipos podem ser removidos pela polipectomia por cauterização com laço. São limitados os dados que avaliam o tratamento de pólipos inflamatórios resistentes à cauterização por laço.

Métodos: Descrevemos dois casos com pólipos inflamatórios resistentes à cauterização por laço; um deles se tratava de paciente com doença de Crohn (DC) com o pólipo na anas-

Palavras-chave:

Cauterização por laço

Doença intestinal inflamatória

Pólipos inflamatórios

Bisturi-agulha

* Corresponding author.

E-mail: shenb@ccf.org (B. Shen).

2237-9363 © 2014 Sociedade Brasileira de Coloproctologia. Published by Elsevier Editora Ltda.

Este é um artigo Open Access sob a licença de [CC BY-NC-ND](https://creativecommons.org/licenses/by-nc-nd/4.0/) <http://dx.doi.org/10.1016/j.jcol.2014.02.003>

tomose íleo-colônica (AIC), e o outro era paciente de colite ulcerativa (CU) com pólipos na entrada da bolsa.

Resultados: Foi efetuada uma endoscopia com o paciente sedado, demonstrando um grande pólipo pedunculado (2,5 cm) na AIC do primeiro paciente e um grande pólipo pedunculado (5 cm) na abertura da bolsa no segundo paciente. Inicialmente, foi tentada polipectomia por cauterização com laço, que falhou nos dois pacientes. Foi então executada a polipectomia assistida por bisturi-agulha, que ajudou na polipectomia completa. Os dois procedimentos levaram 25 minutos cada. Os pacientes toleraram satisfatoriamente o procedimento e, depois da polipectomia, ficaram bem. Os diagnósticos patológicos finais para os dois pacientes foram pólipos inflamatórios com fibrose extensa.

Conclusões: Ao que parece, a polipectomia endoscópica por bisturi-agulha é técnica efetiva para o tratamento de pólipos inflamatórios resistentes à cauterização por laço.

© 2014 Sociedade Brasileira de Coloproctologia. Publicado por Elsevier Editora Ltda.

Este é um artigo Open Access sob a licença de [CC BY-NC-ND](#)

Introduction

Inflammatory polyps are commonly recognized as a distinct entity of non-neoplastic polyps in the gastrointestinal tract, mainly seen in patients with inflammatory bowel disease (IBD). The reported frequency of inflammatory polyps in patients with IBD ranged from 12.5% to 48%.¹ snare polypectomy has been accepted as the treatment modality of choice in most patients with inflammatory polyps.^{2,3} surgical interventions might be required when snare polypectomy was not eligible.¹ Here we reported on two IBD patients whose inflammatory polyps were fibrotic and initially resistant to hot snare polypectomy, but were successfully resected with the assistance of endoscopic needle-knife.

Case 1

The patient was a 53-year-old female who was diagnosed with Crohn's ileitis at age 19. She has undergone a total of four ileocolonic resections related to recurrent Crohn's disease (CD), with the latest surgery being done at the age of 49. Her current medicines included mercaptopurine (50 mg/day) and budesonide (9 mg/day). She was a non-smoker. Her past medical history was remarkable for multiple sclerosis.

The patient presented to our clinic with a 4-month history of bloating and right lower quadrant abdominal pain. A stricture at the ileocolonic anastomosis (ICA) was suspected clinically. On conscious sedation (intravenous meperidine 75 mg and midazolam 4 mg), colonoscopy was performed using a PCF-190 colonoscope (Olympus, Tokyo, Japan). There was a large 2.5 cm pedunculated polyp at the ICA. On endoscopy, the polyp was rubbery and resistant to two sessions of hot snare polypectomy (ConMed, Utica, NY, USA) at setting of 40 joules. The stalk was still intact even after complete closure of the snare. With previous vast experience of the tool, we decided to use endoscopic needle knife (Olympus Medical Systems, Tokyo, Japan) to remove the polyp. One Endoloop (Olympus Medical Systems, Tokyo, Japan) was deployed to block the blood supply of the polyp. The stalk of the polyp was cut half-way through using the needle knife at the setting of ERCP Endocut (ERBE, USA Incorporated Surgical Systems, Marietta, Georgia, USA).

We then switched back to the hot snare, due to perforation concern of needle knife therapy. The residual stalk of the polyp was successfully cut through with additional three sessions of hot snares (Fig. 1 A-D). The entire procedure took 25 minutes. The patient tolerated the procedure well. After the procedure, the patient continued to do well and her bowel obstructive symptoms were relieved. The final pathological diagnosis was inflammatory polyp with extensive fibrosis (Fig. 2 A and B).

Case 2

A 58-year-old female was referred to our clinic for a possible mass in the ileal pouch. She was diagnosed as having UC at age 32. Subsequently, she developed medically refractory disease and underwent a 2-stage J pouch surgery at an outside institution at age 52. Postoperatively, the patient had an average of 20 bowel movements a day, with occasional blood in

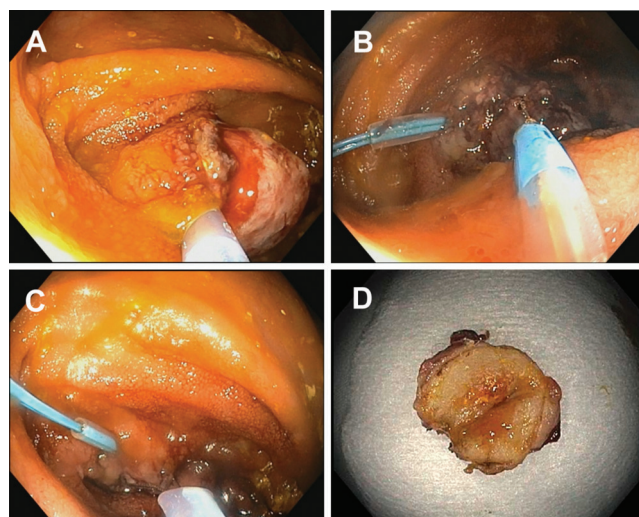


Fig. 1 – Endoscopic needle knife-assisted polypectomy in hot snare-resistant fibrotic inflammatory polyp (Case 1). A, Inflammatory polyp was resistant to hot snare polypectomy; B, Endoscopic needle knife was applied; C, Switched to the hot snares; D, Gross specimen of the resected polyp.

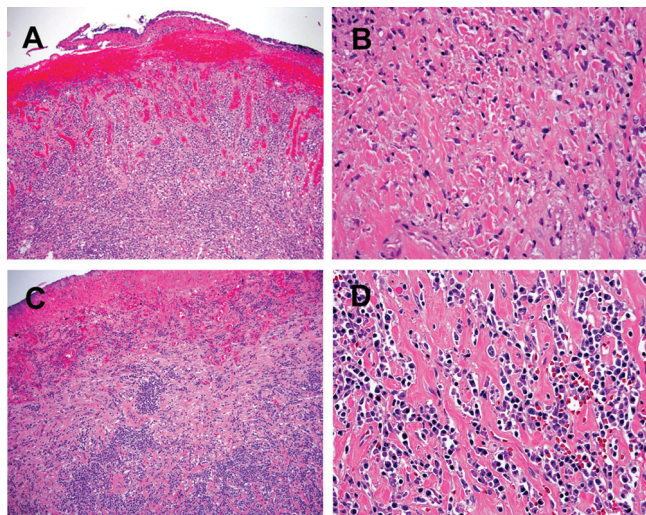


Fig. 2 – Histologic pictures of inflammatory polyps. Both polyps demonstrate similar features, which are characterized by near complete surface erosion, dense lymphoplasmacytic inflammation (A & C, H&E stain, 100X, Case 1 and 2, respectively), and extensive fibrosis (B & D, H&E stain, 100X, Case 1 and 2, respectively).

stool. The most recent pouchoscopy at the outside hospital suggested a possible mass in the pouch inlet.

With conscious sedation of the patient (intravenous meperidine 150 mg and midazolam 6 mg), a pouchoscopy was performed with a GIF-H180 gastroscope (Olympus, Tokyo, Japan). A large 5 cm pedunculated polyp was found at the pouch inlet. Hot snare polypectomy was attempted, but failed to cut through. Then endoscopic needle knife polypectomy was successfully performed with setting of ERCP Endocut (Fig. 3 A-D). The entire procedure took 25 minutes. The patient tolerated the procedure well and continued to do well after the procedure. The final pathological diagnosis was inflammatory polyp with extensive fibrosis (Fig. C and D).

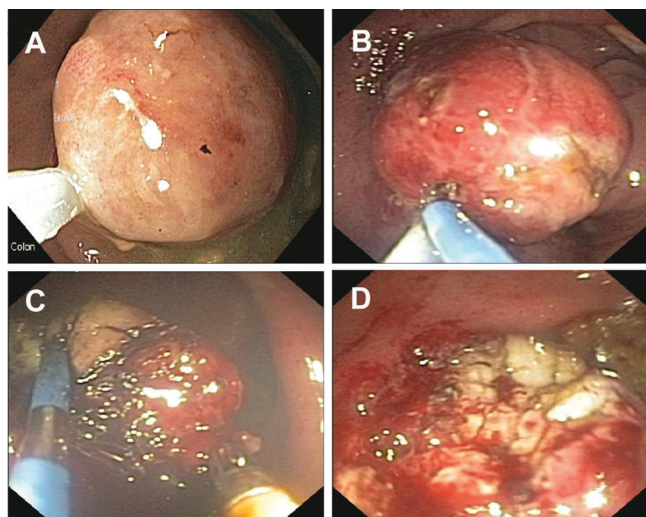


Fig. 3 – Endoscopic needle knife-assisted polypectomy in hot snare-resistant fibrotic inflammatory polyp (Case 2).

Discussion

Inflammatory polyps, or pseudopolyps, are common sequelae in patients with IBD, occurring twice as frequently in UC as in colonic CD.¹ Those inflammatory polyps, irrespective of size, may result from residual islands of mucosa that remain after the surrounding, severely inflamed mucosa becomes ulcerated. These islands of mucosa project into the lumen and traction by the fecal stream elongates these tags to a polypoid configuration.⁴ Those polyps can contribute to patient's symptoms of obstruction or hemorrhage.

Clinical and endoscopic distinction between inflammatory polyps and dysplastic polyps in patients with IBD can be difficult. In our clinical practice, polypectomy are recommended for large inflammatory polyps which are believed to cause symptoms or are indistinguishable from dysplastic mass or lesion. The main challenge for endoscopic treatment of inflammatory polyps has been bleeding, as those inflammatory polyps are rich in blood vessels. Inflammatory polyps, especially for those cannot be removed by endoscopic polypectomy or those present with obstructive symptoms, such as luminal obliterations and/or intussusceptions, usually required surgical resection.¹ The two cases presented in our study were initially resistant to the routine hot snare polypectomy, which might have been doomed for surgical intervention. However, both of the two patients were salvaged from the invasive procedure by applying the endoscopic needle knife technique. As shown by a previous study from our group,⁵ endoscopic needle-knife therapy holds the benefits of being less-invasive and relatively easy to perform. No hospitalization is required and the patient has quick recovery. However, this procedure is preferred to be performed in experienced hands, since it has a potential risk for bowel perforation. Furthermore, follow-up colonoscopies or pouchoscopies may be needed — even for those with successful polypectomies — for the following reasons: 1) two cases of IBD with inflammatory polyps complicating occult cancer or dysplasia have been reported, although inflammatory polyps were initially thought to be benign; 2) the presence of inflammatory polyps has been shown to be an independent marker of increased risk for malignancy in patients with IBD, since their presence can reflect previously severe inflammatory changes.⁶

In summary, our study showed that needle knife-assisted polypectomy seemed to be an effective technique for the management of hot snare-resistant inflammatory polyps, representing a new potential indication for this treatment modality.

Conflicts of interest

The authors declare no conflicts of interest.

REFERENCES

- Maggs JR, Browning LC, Warren BF, et al. Obstructing giant post-inflammatory polyposis in ulcerative colitis: Case report and review of the literature. *J Crohns Colitis* 2008;2: 170-180.

2. Ishibashi H, Aoyagi K, Kobayashi H, et al. Endoscopic mucosal resection of inflammatory fibroid polyp in the transverse colon. *Endoscopy* 2012;44 Suppl 2 UCTN: E15-16.
3. Ergun M, Zengin N, Kayacetin E. Loop observe and snare technique for endoscopic resection of a gastric inflammatory fibroid polyp. *Endoscopy* 2012;44 Suppl 2 UCTN: E86-87.
4. Kelly JK, Gabos S. The pathogenesis of inflammatory polyps. *Dis Colon Rectum* 1987;30: 251-254.
5. Wu XR, Wong RC, Shen B. Endoscopic needle-knife therapy for ileal pouch sinus: a novel approach for the surgical adverse event (with video). *Gastrointest Endosc* 2013.
6. Velayos FS, Loftus EV, Jr., Jess T, et al. Predictive and protective factors associated with colorectal cancer in ulcerative colitis: A case-control study. *Gastroenterology* 2006;130: 1941-1949.