



## Original Article

# A novel approach to lower rectal anastomosis: technique innovation and the preliminary report of twenty cases



Abbas Alibakhshi\*, Yosra Jahangiri, Fereydoun Sirati, Sayed Mahdi Jalali, Mohammad Sadegh Nikdad, Arezou Abbasi, Mohsen Afarideh

Department of General Surgery, Imam Khomeini Hospital Complex (IKHC), Tehran University of Medical Sciences, Tehran, Iran

## ARTICLE INFO

## Article history:

Received 4 December 2015

Accepted 25 March 2016

Available online 13 April 2016

## Keywords:

Colorectal surgery

Low rectal stapler anastomosis

Pull-through

Transanal

Transabdominal

## ABSTRACT

**Background and aims:** To describe a practical technique innovation (transanal 'Pull-through' approach) as a feasible, safe and effective alternative to the conventional transabdominal stapler low rectal anastomosis in lesions of minimal anatomical distinction from the adjacent intact mucosa.

**Material and methods:** Prospective case-series of patients with low rectal cancers, familial adenomatous polyposis (FAP) and ulcerative colitis undergoing Pull-through transection and very low rectal anastomosis using linear TA-90 noncutting stapler and circular stapler-cutter. **Results:** In this series, twenty patients (11 men and 9 women) underwent proctectomy by the transanal Pull-through technique. Barring one of the patients that developed a pelvic abscess in the immediate postop follow-up, surgical procedure and the long-term follow-up period was uncomplicated with no critical findings of leakage, stenosis and bleeding. The postop rate of infection and fecal incontinence was not significantly different between genders and different age groups of the study. The mean operative time was calculated  $169.9 \pm 11.1$  minutes.

**Conclusion:** Pull-through transection procedure using the TA-90 non-cutting stapler is a safe, efficient and economically sound technique implicated in low-lying rectal lesions. The transanal 'Pull-through' approach is particularly helpful in situations where the direct visualization of lower rectal mucosa changes the prognosis through determining the marginal extent of intact/involved mucosa (e.g., FAP, villous adenomas, rectal polyps and post-neoadjuvant chemoradiotherapy tumors).

© 2016 Sociedade Brasileira de Coloproctologia. Published by Elsevier Editora Ltda. This is an open access article under the CC BY-NC-ND license (<http://creativecommons.org/licenses/by-nc-nd/4.0/>).

\* Corresponding author.

E-mail: [alibakhshi52@yahoo.com](mailto:alibakhshi52@yahoo.com) (A. Alibakhshi).

<http://dx.doi.org/10.1016/j.jcol.2016.03.006>

2237-9363/© 2016 Sociedade Brasileira de Coloproctologia. Published by Elsevier Editora Ltda. This is an open access article under the CC BY-NC-ND license (<http://creativecommons.org/licenses/by-nc-nd/4.0/>).

## Uma nova abordagem para a anastomose retal mais baixa: inovação técnica e relatório preliminar de cinte casos

### R E S U M O

#### Palavras-chave:

Cirurgia colorretal  
Anastomose retal baixa com grampos  
Abordagem pull-through  
Transanal  
Transabdominal

**Experiência e objetivos:** Descrever uma inovação técnica prática (abordagem transanal pull-through) como uma alternativa viável, segura e eficaz à anastomose transabdominal retal baixa convencional com grampos em lesões com mínima diferenciação anatômica com respeito à mucosa intacta adjacente.

**Material e métodos:** Estudo prospectivo de série de casos de pacientes com cânceres retais baixos, polipose adenomatosa familiar e colite ulcerativa submetidos à transecção pull-through e a uma anastomose retal muito baixa com o uso de um grampeador linear não cortante TA-90 e um grampeador cortante circular.

**Resultados:** Nesta série, 20 pacientes (11 homens, 9 mulheres) foram submetidos a uma proctectomia pela técnica transanal pull-through. À exceção de um dos pacientes, que apresentou um abscesso pélvico no seguimento pós-operatório imediato, não ocorreram complicações com o procedimento cirúrgico e ao longo do prolongado período de seguimento, nem houve achados críticos de vazamento, estenose ou sangramento. O percentual de infecção e incontinência fecal no pós-operatório não foi significativamente diferente entre gêneros e nas diferentes faixas etárias dos pacientes envolvidos no estudo. O tempo cirúrgico médio foi de  $169,9 \pm 11,1$  minutos.

**Conclusão:** O procedimento de transecção pull-through com o uso do grampeador não cortante TA-90 é técnica segura, eficaz e economicamente confiável para uso em lesões retais baixas. A abordagem transanal pull-through tem particular utilidade em situações nas quais a visualização direta de alterações na mucosa retal mais baixa muda o prognóstico, mediante a determinação da extensão marginal da mucosa intacta/envolvida (p. ex., FAP, adenomas vilosos, pólipos retais e tumores pós-quimiorradioterapia neoadjuvante).

© 2016 Sociedade Brasileira de Coloproctologia. Publicado por Elsevier Editora Ltda. Este é um artigo Open Access sob a licença de CC BY-NC-ND (<http://creativecommons.org/licenses/by-nc-nd/4.0/>).

## Introduction

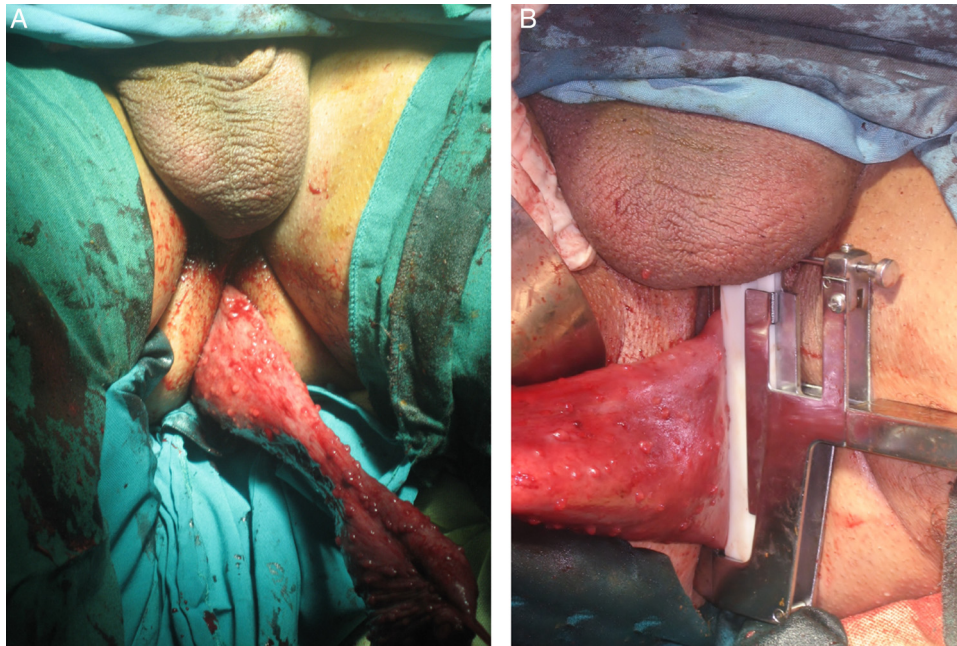
Although conventional end-to-end anastomosis (EEA) techniques are often viewed as an excellent option in a select number of lower colorectal diseases,<sup>1</sup> the problems of a complicated anastomosis; in particular in sites with limited anatomical access such as depth of the pelvic cavity, has led many gastrointestinal oncologist surgeons to seek alternative treating options to overcome this challenge. Ensuring the anastomotic security is especially important because life threatening potential of EEA failure in rectal cancer sufferers is associated with increased recurrence rate, which further deteriorates the prognosis.<sup>2-4</sup>

Currently, intra-abdominal transection of rectal lesions is routinely performed using different types of staplers.<sup>5</sup> However and aside from concerns over a possible anastomotic leak that could persist with double stapling,<sup>6</sup> operator-dependency and the high expenses of curved stapler-cutters used in these settings, many preclude its widespread use in certain regions with limited financial power. Additionally, unconfident determination of safe margin border in lesions with seemingly inseparable gross morphology from the adjacent intact mucosa (e.g., familial adenomatous polyposis [FAP] and post-neoadjuvant chemoradiotherapy rectal tumors) is another restraint to the use of transabdominal procedures.

Herein, we aimed to describe a novel yet simple and practical technique innovation for performing low and very low rectal anastomoses using different set of staplers with an eye to resolve the aforementioned shortcomings

## Material and methods

We prospectively examined the proposed 'Pull-through' EEA technique on twenty consecutive candidates of elective proctectomy who fulfilled the eligibility criteria to enter our study in the Imam Khomeini Hospital Complex (IKHC, a tertiary referral teaching hospital affiliated with Tehran University of Medical Sciences) from January 2011 to February 2012. Institutional review board (IRB) exemptions were previously obtained in accordance with the Human Subjects Research policy. In addition, written informed consent was received from each of the participating patients. From our perspective, suggestive indications for transanal Pull-through approach to the lower rectal anastomosis included small to moderate sized lesions of the middle to very lower rectum, post-neoadjuvant chemoradiation therapy tumors without a palpable tumor margin, FAP, villous adenoma, other benign/malignant outgrown tissues and other indications of elective proctectomy (e.g., ulcerative colitis, UC). We excluded obese patients (body mass index  $>30 \text{ kg/m}^2$ ) due to a complicated course of surgery, while patients with a bulky mesorectum and/or mass lesion



**Fig. 1 – Intra-operative images of the stapled “Pull-through” end-to-end anastomosis (EEA) in a patients with familial adenomatous polyposis (FAP). (A) Transanal grasp of lower rectum as facilitated by the use of sponge stick; (B) application of the linear non-cutter TA-90 stapler in the stable ileoanal EEA anastomosis. Note the level at which transection is performed on the lower rectal lumen should be immediately adjacent to the dentate line in patients with FAP.**

with the potential of anal rim incarceration were also excluded from the study.

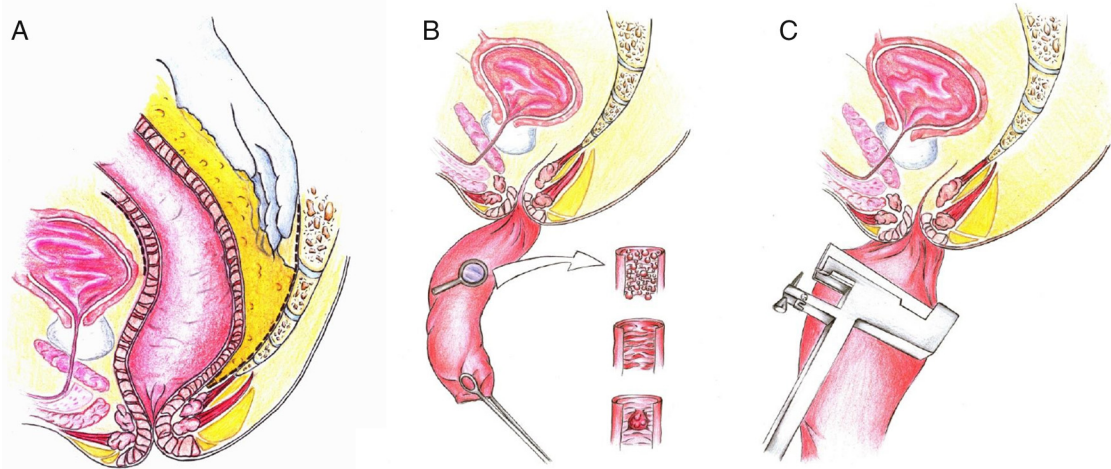
### **Surgical technique**

Patients were scheduled for the operation, received bowel preparation in the OR and placed in a lithotomy/V position. Under the general anesthesia, a peri-umbilical midline incision was cut to diagnostically explore the abdomen and determine whether the mass is resectable, with further supra-pubic extension of the incision line. Initial steps of procedure were performed as per the standard transabdominal stapled anastomosis. Following a mid to low rectal transection (keeping a minimum 5-cm distance from the superior plane of levators and pelvic floor), a peri-rectal dissection was performed to ease the passage of freed rectal stump down a dilated anal canal as described below. Of note, a mechanical barrier was formerly located between the field of resection and the superior level of levators to avoid mechanical sphincteric manipulation and damage during the Pull-through procedure. The LigaSure vessel sealing system (Valley Laboratory Inc., Boulder, CO) was employed for the resection of mesorectosigmoid colon or total mesorectal excision (TME) to free rectum from the nearby bony sacrum. Considering the anatomical proximity between urinary tract and lateral rectal wall, dispatching their inter-connecting adhesions required an exhaustively meticulous approach. By changing the surgical position to commence transanal eversion, a large sponge stick clamp was entered inside the anal canal to draw and evert the severed rectum cut edge resulting in the rectal exteriorization and exposure of inner surface (i.e., exposure of the rectal mucosa). We ensued the operation by resecting selected

mucosal specimens with a 1.9 mm distance (an increase from the maximum 1.5 mm distance in the transabdominal stapler method) from the predetermined site of safe margin as marked by a linear noncutting TA-90 mm stapler (Covidien TA™ 90 mm). In FAP and other global pathologies, the line of stapling should be ideally positioned as high up the everted rectum as possible, next to the pectinate (dentate) line to extirpate the residual at-risk rectal mucosa. Prior to the insertion of the anal canal, oversewn and continuously running sutures reinforced the newly formed rectal/anal pouch to ensure an increased level of stability; thus helping reduce the risk of leaking anastomosis. 25-mm anvil of 29–33 mm circular stapler (PROXIMATE® ILS Circular, Ethicon, Endo-Surgery, Cincinnati, OH, USA) was anchored endoluminally on proximal colon/distal ileum to form a standard stapled anastomosis with the rectal/anal pouch. Before the transanal passage of circular stapler in preparation for firing, anvil was repositioned from tilted to a flat position to enable anastomosis of the pouch with proximal colonic J-pouch/distal ileal pouch. Finally, attachment of the spike of circular stapler to the anvil head signaled the conclusion of Pull-through lower rectal EEA. Assurance for a fully functioning lower rectal anastomosis was post-operatively assessed through air injection (Figs. 1 and 2).

Each patient was prescribed to start his/her routine diet on the postop day 3. Perioperative and long-term follow-up of the patients included recorded data on fecal continence and the frequency of bowel movements as well as the rate of developing complications, recurrences, morbidities and mortalities. Previous estimation of preoperative staging through computed tomography (CT) scan imagery ± endoscopy assessment revealed no case of locally invasive tumor.





**Fig. 2 – Sequential overview of the Pull-through procedure in schematic representations. (A) Total mesorectal excision (step 1); (B) the transanal “Pull-through” end-to-end anastomosis (EEA) is particularly optimized for pathologies that do not obstruct the lumen and are not readily distinguished from the normal neighboring mucosa (e.g., familial adenomatous polyposis, ulcerative colitis and post-chemo radiation tumors (step 2); (C) lateral plane view of the everted rectal mucosa under the direct view of surgeon following stapling with TA-90 mm linear stapler-noncutter (step 3).**

### Statistical analysis

Clinical endpoint data for this study was entered to PASW software V 18.0 (IBM Corp., Armonk, NY). Categorical variables are expressed as frequencies (%) and were compared by Fisher exact test. Continuous baseline characteristics are expressed as mean  $\pm$  standard deviation (SD). Since the normality of data was previously assessed and rejected by goodness of fit Shapiro–Wilk test, between-group comparisons across the two and three groups was made using Mann–Whitney *U* and Kruskal–Wallis *H* tests, respectively. Two-sided statistical significance was preset at  $p < 0.05$ .

### Results

From the 20 analyzed cases (twelve men and eight women), nine had rectal cancer (seven cases of rectal cancer had underwent previous neoadjuvant chemoradiation sessions), one ulcerative colitis (UC) and the ten others had FAP. The average distance of the mass lesion from the anal verge, as confirmed by rigid sigmoidoscopy work-up was approximately 6 cm. The mean  $\pm$  SD length of remaining rectal cuff for creating colorectal/ileo-rectal pouch was measured at  $3.4 \pm 2.2$  cm (excluding FAP patients), depending on the location of tumor/lesion from the dentate line and with a minimum of 2 cm safe margin distance from the distal tumor free border. For patients with FAP, rectal transection was carefully done just above the dentate line to diminish the risk of micro-metastasis and recurrences of remaining polyps. Median age of study participants was 49 years, ranging from 18 to 71. Histopathology evaluations demonstrated all resected samples to have tumor-free margins. The mean operative time was calculated  $169.9 \pm 11.1$  minutes, with no significant difference between genders ( $170.8 \pm 9.7$  for females vs.  $169.1 \pm 12.6$  for males;  $p = 0.6$ ) and different age groups ( $171.0 \pm 5.7$  for age group  $< 30$ ,  $166.0 \pm 9.7$  for  $30 \leq$  age group  $< 50$  and  $174.4 \pm 12.9$ ;

$p = 0.2$ ). The observation of a slight leak after air injection prompted us to perform two defunctioning ileostomy in our series, one in a patient with post-neoadjuvant rectal cancer and another in a case with UC. Excluding one of the patients who developed a pelvic abscess in the immediate postop follow-up, there were no critical post-surgical complications namely, bleeding, leakage, incontinence and fistula formation. Mild and transient (lasting for 3 and 4 months, respectively) gas incontinence, not interfering with engaging in daily normal activities, occurred in two cases (one with rectal cancer and the other with FAP; assessed by clinical evaluation). Wound infection was also reported in two cases, with neither requiring reoperation. The mean  $\pm$  SD hospitalization period was  $5.7 \pm 1.1$  days and patients were discharged thereafter; similarly we found no statistically significant differences in terms of hospital stay between females and male and difference categories of participants’ age ( $p$  for all non-significant). Patients were followed for a mean preoperative period of  $2.5 \pm 0.6$  years, with no report of stricture, functional outcomes and mortality during this period.

### Discussion

Colorectal surgeries have drastically evolved during the past few decades. The emergence of Colo- and ileoanal stapled EEA techniques have propelled the development of modern very low rectal anastomosis and reduced the risk of leakage and other complications.<sup>7,8</sup> For low anastomosis in general, a higher incidence of urgent defecation, fecal incontinence, evacuation disorders, coupled with frequent bowel movements are expected.<sup>9</sup> However, very low rectal resections located within 5 cm distance from the anal verge represent a technically superior challenge due to having a comparatively increased risk for anastomotic complication and the imperative need of a sphincter-preserving surgery.

Considering numerous problems characteristic of the resection of low lying rectal tumors, surgeons have sought many alternative manual or robotic techniques, to approach lesions of this area of the gut.<sup>10-15</sup> In 1972, Parks described reestablishing anorectal continuity with a handsewn coloanal anastomosis by a perineal approach in intersphincteric resection of benign conditions.<sup>16</sup> Since then, many authors have adopted a hand-sewn coloanal anastomosis method or variations thereof, even as a salvage procedure following failed attempts of stapled anastomosis.<sup>17</sup>

While the coloanal handsewn anastomosis is considered by many as an excellent option,<sup>17</sup> stapled EEA is recently being preferred by some surgeons,<sup>5</sup> which has led to controversy in standardization of care in low lying rectal cancers.<sup>18</sup> Several Meta-analyses and Cochrane-based systematic reviews have compared the efficacy of the handsewn and stapled anastomoses in lower rectal operations with controversial results.<sup>19-22</sup> Although ileostomy closure using stapler and sutured anastomotic techniques were comparable in terms of anastomotic leak, surgical site infection, readmission, reoperations and hospitalization period, stapled anastomosis was associated with a shorter operative time and lower risk of post-operative small bowel obstruction.<sup>23</sup> Nevertheless and as our experience with colorectal anastomosis suggest, transabdominal stapled technique (in depth of the pelvic cavity) has two major drawbacks:

- (I) Inadequate transabdominal stapling performed by the novice surgeon is associated with an increased risk of post-surgical anastomotic dehiscence that may result in reoperation, higher morbidity, hospital stay and mortality, permanent colostomy with a high rate of,<sup>24</sup> anal stenosis and local recurrences of the rectal tumors.<sup>25</sup> Straight EEA lines created by linear TA-90 stapling device instead of gastrointestinal anastomosis (GIA)/Contour stapler-cutter curved lines, and increased side-to-side anastomotic span from 40 mm in the transabdominal stapler anastomosis to 90 mm in the Pull-through procedure prevents ischemia in the EEA corners (triangle ischemia) and folding of the colon cut edges, respectively and safeguard the colorectal anastomosis.
- (II) In post-neoadjuvant chemoradiotherapy rectal cancers or FAP, safe margin determination becomes a difficult task due to mainly non-palpable lesions. As such, direct mucosal inspection in the transanal Pull-through approach would be superior to the blind transection in conventional stapled anastomosis to clearly differentiate intact from involved rectal mucosa and subsequently prevent invasive overtreatment procedures that could potentially result in a dysfunctioning anal sphincter.

Our described approach is in many ways, an upgrade to the predecessor Pull-through technique as developed by Toupet, which in turn is a modification of Duhamel Pull-through procedure.<sup>26</sup> The essence of Toupet Pull-through technique includes an anterior colorectal intubation and a temporary perineal colon anus. The author suggested the newly found anastomosis can doubly protect against the development of fistulae from anastomotic disunion.<sup>27</sup> Whilst

the maximum anastomotic support gained from the initial use of linear noncutter stapler and subsequent oversewing of sutured tumor margins can obviate the need for the proximal ostomy,<sup>24</sup> our approach is unique to provide direct perineal visualization of non-palpable lesions (e.g., FAP and post-chemoradiation rectal cancers) where a precise safe margin determination remains fundamental to achieve consistent results.

It should be noted the proposed 'Pull-through' approach to lower rectal anastomoses bears some considerable limitations. Transanal extraction of the lower rectal part turns ineffective once comparatively large lesions of rectal adenomas block the entry of full-thickness rectal mucosa into the dilated anal opening. Additionally, extirpation of rectal mucosa in patients with FAP requires expert and meticulous transection of rectum down to the dentate line to lower the risk of residual microscopic polyp and metastasis. Finally, because of the limited number of included patients and a relatively short-term follow-up period, the safety and efficacy of the described technique is not entirely applicable to the patients of previous studies. The advantages of this technique include a thorough scrutiny of tumor margin under direct visualization of rectal mucosa, minimal risk of complications (e.g., anastomotic leak), simplicity of the procedure compared to transabdominal stapler EEA (in particular, in patients with anatomically small pelvis). The cost-effective nature of transanal Pull-through approach due to affordable use of linear noncutting TA-90 staplers (cost per unit up to \$150) as opposed to the additional high costs imposed by the use of curved stapler cutter (up to a total of \$500 per surgical set in our country) can be a viable resource saving strategy in the settings of middle to lower rectal tumor surgeries.

---

## Conclusion

Indicated for medium to low rectal anastomoses, the sphincter-preserving transanal Pull-through EEA is an efficient clinical asset and easily applicable to both benign and malignant diseases. Implementation of the Pull-through approach using a TA-90 linear stapler-noncutter and by a directly visualized mucosectomy (as an alternative to the expensive intra-operative endoscopy in laparoscopic settings) is associated with significantly less economic burdens on the patients. We recommend comparative studies involving the conventional transabdominal stapled or hand-sewn anastomosis methods, and the described Pull-through technique to endorse the preferred standard of care in each setting. Future large-scale studies of the Pull-through approach should confirm its safety, efficiency and feasibility and investigate whether this approach is equally reproducible in laparoscopic settings.

---

## Conflicts of interest

The authors declare no conflicts of interest.

## Acknowledgements

The authors wish to thank the patients and staff of Imam Khomeini Hospital Complex (IKHC) for their gracious participation in this study.

## REFERENCES

- Fazio VW, Kiran RP, Remzi FH, Coffey JC, Heneghan HM, Kirat HT, et al. Ileal pouch anal anastomosis: analysis of outcome and quality of life in 3707 patients. *Ann Surg.* 2013;257:679–85.
- Nandakumar G, Stein SL, Michelassi F. Anastomoses of the lower gastrointestinal tract. *Nat Rev Gastroenterol Hepatol.* 2009;6:709–16.
- Paun BC, Cassie S, MacLean AR, Dixon E, Buie WD. Postoperative complications following surgery for rectal cancer. *Ann Surg.* 2010;251:807–18.
- Telem DA, Chin EH, Nguyen SQ, Divino CM. Risk factors for anastomotic leak following colorectal surgery: a case-control study. *Arch Surg.* 2010;145:371–6.
- Köhler A, Athanasiadis S, Ommer A, Psarakis E. Long-term results of low anterior resection with intersphincteric anastomosis in carcinoma of the lower one-third of the rectum. *Dis Colon Rectum.* 2000;43:843–50.
- Averbach AM, Chang D, Koslowe P, Sugarbaker PH. Anastomotic leak after double-stapled low colorectal resection. *Dis Colon Rectum.* 1996;39:780–7.
- Villanueva-Sáenz E, Sierra-Montenegro E, Peña-Ruiz Esparza JP, Martínez Hernández-Magro P, Bolaños-Badillo LE. Double stapler technique in colorectal surgery. *Cir Ciruj.* 2008;76:49–53.
- Fingerhut A, Hay JM, Elhadad A, Lacaine F, Flamant Y, French Associations for Surgical Research. Supraperitoneal colorectal anastomosis: hand-sewn versus circular staples—a controlled clinical trial. *Surgery.* 1995;118:479–85.
- Bittorf B, Stadelmaier U, Göhl J, Hohenberger W, Matzel KE. Functional outcome after intersphincteric resection of the rectum with coloanal anastomosis in low rectal cancer. *Eur J Surg Oncol.* 2004;30:260–5.
- Velez JP, Villavicencio RT, Schraut W, Lee K. Outcome analysis of external coloanal anastomosis. *Am J Surg.* 1999;177:467–71.
- Joo JS, Latulippe JF, Alabaz O, Weiss EG, Noguera JJ, Wexner SD. Long-term functional evaluation of straight coloanal anastomosis and colonic J-pouch. *Dis Colon Rectum.* 1998;41:740–6.
- Williams N, Seow-Choen F. Physiological and functional outcome following ultra-low anterior resection with colon pouch–anal anastomosis. *Br J Surg.* 1998;85:1029–35.
- Huber FT, Herter B, Siewert JR. Colonic pouch vs. side-to-end anastomosis in low anterior resection. *Dis Colon Rectum.* 1999;42:896–902.
- Manceau G, Karoui M, Breton S, Blanchet AS, Rousseau G, Savier E, et al. Right colon to rectal anastomosis (Deloyers procedure) as a salvage technique for low colorectal or coloanal anastomosis: postoperative and long-term outcomes. *Dis Colon Rectum.* 2012;55:363–8.
- Kang J, Hur H, Min BS, Lee KY, Kim NK. Robotic coloanal anastomosis with or without intersphincteric resection for low rectal cancer: starting with the perianal approach followed by robotic procedure. *Ann Surg Oncol.* 2012;19:154–5.
- Parks A. Transanal technique in low rectal anastomosis. *Proc R Soc Med.* 1972;65:975.
- Tekkis P, Tan E, Kontovounisios C, Kinross J, Georgiou C, Nicholls RJ, et al. Hand-sewn coloanal anastomosis for low rectal cancer; technique and long term outcome. *Colorectal Dis.* 2015.
- Rullier E, Denost Q, Vendrely V, Rullier A, Laurent C. Low rectal cancer: classification and standardization of surgery. *Dis Colon Rectum.* 2013;56:560–7.
- Neutzling CB, Lustosa SA, Proenca IM, da Silva EM, Matos D. Stapled versus handsewn methods for colorectal anastomosis surgery. *The Cochrane Library;* 2012.
- Matos D, Atallah ÁN, Castro AA, Silva Lustosa SA. Stapled versus handsewn methods for colorectal anastomosis surgery. *The Cochrane Library;* 2001.
- MacRae HM, McLeod RS. Handsewn vs. stapled anastomoses in colon and rectal surgery. *Dis Colon Rectum.* 1998;41:180–9.
- Choy PY, Bissett IP, Docherty JG, Parry BR, Merrie A, Fitzgerald A. Stapled versus handsewn methods for ileocolic anastomoses. *The Cochrane Library;* 2011.
- Sajid M, Craciunas L, Baig M, Sains P. Systematic review and meta-analysis of published, randomized, controlled trials comparing suture anastomosis to stapled anastomosis for ileostomy closure. *Tech Coloproctol.* 2013;17:631–9.
- Nurkin S, Kakarla VR, Ruiz DE, Cance WG, Tiszenkel HI. The role of faecal diversion in low rectal cancer: a review of 1791 patients having rectal resection with anastomosis for cancer, with and without a proximal stoma. *Colorectal Dis.* 2013;15:309–16.
- Akasu T, Takawa M, Yamamoto S, Yamaguchi T, Fujita S, Moriya Y. Risk factors for anastomotic leakage following intersphincteric resection for very low rectal adenocarcinoma. *J Gastrointest Surg.* 2010;14:104–11.
- Katkhouda N, Khalil MR, Manhas S, Grant S, Velmahos GC, Umbach TW, et al. André Toupet: surgeon technician par excellence. *Ann Surg.* 2002;235:591.
- Toupet A. Abdominal approach to rectal resection with subperitoneal anastomosis by anterior colorectal intubation (author's transl). *J Chir (Paris).* 1980;117:705–12.